

## Sevoflurane Insufflation Sedation for the Dental Treatment of a Patient with Pulmonary Arterial Hypertension : A Case Report

Seongin Chi<sup>1</sup>, Seungoh Kim<sup>2</sup>

<sup>1</sup>Department of Pediatric Dentistry, College of Dentistry, Dankook University

<sup>2</sup>Department of Dental Anesthesiology, College of Dentistry, Dankook University

### Abstract

Pulmonary arterial hypertension (PAH) is a common complication of Congenital heart defects (CHD) with left-to-right shunts, and PAH with increased pulmonary vascular resistance (PVR) is associated with considerable morbidity and mortality. General anesthesia (GA) can be life-threatening in patients with PAH, because the positive pressure ventilation during GA increases pulmonary arterial pressure and decreases pulmonary blood flow. This may also lead to hypoxia. Therefore, spontaneous ventilation may be safer than positive pressure ventilation in patients with PAH.

A five-year-old male child, weighing 11 kg, with medical history showing a total correction of Tetralogy of Fallot (TOF) in 2009 and ongoing treatment with hypertension (HTN) medicine since 2007, visited the Dankook University Dental Hospital. He had multiple dental caries, and the treatment was completed under sevoflurane insufflation sedation via nasal cannula. The patient remained sedated throughout the operation while maintaining normal vital signs and spontaneous respiration.

In conclusion, sevoflurane insufflation sedation may be a safer alternative to GA for the dental treatment of patients with PAH.

**Key words:** Insufflation sedation, Nasal cannula, Pulmonary arterial hypertension, Sevoflurane, Spontaneous ventilation

### I. Introduction

Pulmonary arterial hypertension (PAH) is a common complication in patients with congenital heart defects (CHD)<sup>1)</sup>. Patients with PAH have reported markedly increased morbidity and mortality during general anesthesia (GA) and surgery, compared to normal patients<sup>2,3)</sup>. Patients with PAH have higher risk of perioperative

complications, such as right ventricular (RV) failure and systemic hypotension<sup>4)</sup>. Since GA poses high risk to PAH patients, more suitable anesthetic management is needed for these patients. In recent years, some studies have suggested sevoflurane inhalation or insufflation sedation as an alternative sedation method<sup>5-8)</sup>. We present a case of sevoflurane insufflation sedation for dental treatment in a five-year-old child with PAH.

Corresponding author : Seungoh Kim

Department of Dental Anesthesiology, College of Dentistry, Dankook University, 119, Dandae-ro, Dongnam-gu, Cheonan-si, Chungcheongnam-do, 330-714, Republic of Korea

Tel: +82-41-550-1863 / Fax: +82-41-550-1863 / E-mail: ksomd@dankook.ac.kr

Received November 20, 2014 / Revised November 28, 2014 / Accepted November 29, 2014

※ This study was supported by the research fund of Dankook University in 2013.

## II. Case report

A five-year-old male child with multiple dental caries was referred from local clinic due to his low body weight (11 kg) in January 2013. He was born with congenital heart defects (CHD) - heart with mass, tetralogy of fallot (TOF), large ventricular septal defects (VSD) and left ventricle (LV) to right atrium (RA) shunt - in December 2006. He underwent palliative operation of right modified blalock-taussing shunt (RMBT) in January 2007 and total correction operation in April 2009. He was diagnosed with hypertension (HTN) in 2007 and has been receiving inpatient care and hypertension medication ever since. He was diagnosed with tuberous sclerosis in January 2007 and has been receiving antiepileptic drug (AED).

The patient's chief complaint was multiple dental caries. Results from the clinical and radiographic examination showed dental caries on #54, 55, 65, 74, 75, 84 and 85. Operation under sevoflurane insufflation sedation was planned in consideration of the patient's medical history and to lower the risk of possible complications. The chest radiograph taken before the operation showed enlarged heart size and increased pulmonary vasculature (Fig. 1), confirming the previous diagnosis of CHD with left to right shunt.

Before the treatment, his parents' consent was acquired after the explanation of the entire sedation process was provided. Treatment was performed twice:

Amoxicillin, 650 G, oral, administered 1 hour prior to each dental treatment as a prophylaxis to bacterial infection, and 8 vol% inspired sevoflurane gas administered using a full facial mask. After achieving loss of consciousness, the facial mask was substituted with a nasal cannula (Softech BI-FLO<sup>®</sup> Cannula 1844, Teleflex Inc., Pennsylvania, USA)(Fig. 2). This nasal cannula is composed of two parts, where one supplies the oxygen and sevoflurane and the other detects expired gas of the patient (Fig. 3). Sevoflurane vaporizer was set to deliver 100% oxygen at gas flow of 2.0 L/min. End-tidal sevoflurane concentration as well as patient's respiration through capnography line of the nasal cannula was monitored throughout sevoflurane insufflation sedation.

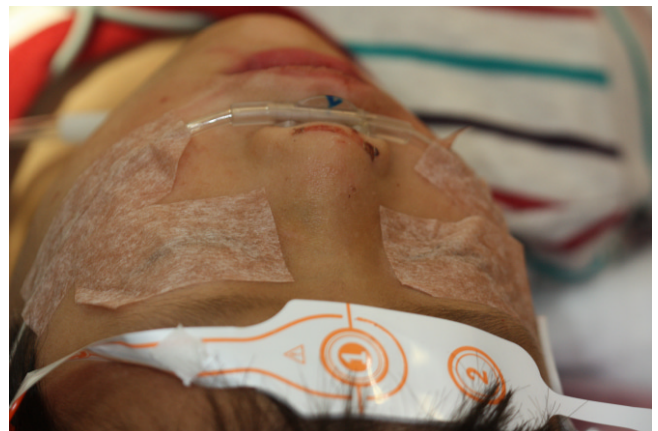

Fig. 2. Patients with nasal cannula and sensor of S/5 Entropy<sup>™</sup> Module.

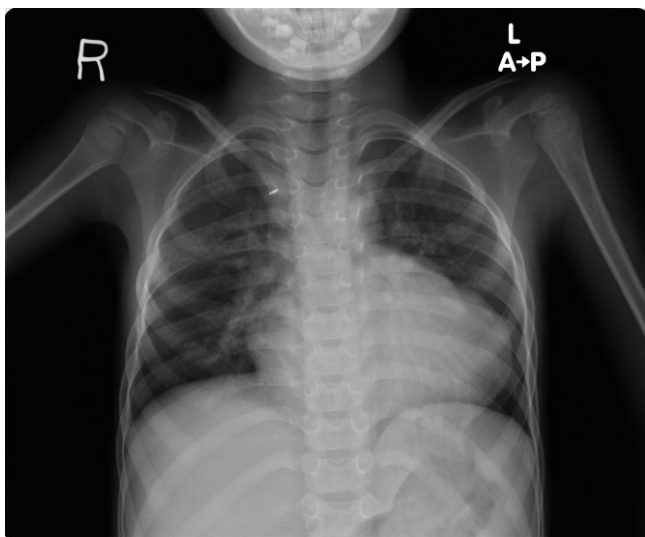


Fig. 1. Chest radiograph. Enlarged heart size and increased pulmonary vasculature, confirming the previous diagnosis of congenital heart defect with left to right shunt.

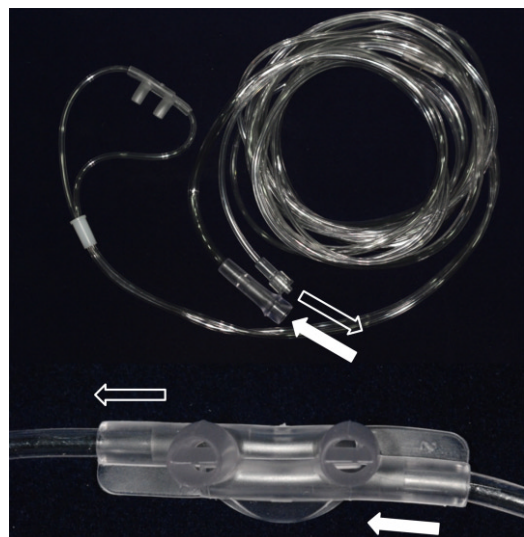


Fig. 3. Nasal cannula. Solid arrow indicates direction of delivering oxygen and sevoflurane gas, hollow arrow indicates direction of detecting expired gas of the patient.

Inspired sevoflurane gas concentration was adjusted to maintain end-tidal sevoflurane concentration in the range of 1 to 1.5 vol%. Then, sedation depth was monitored using S/5 Entropy™ Module (Datex-Ohmeda Division, Instrumentarium Corporation, Helsinki, Finland)(Fig. 2). The patient was sedated throughout the operation while maintaining normal vital signs and spontaneous respiration. After completion of the dental treatment, sevoflurane was discontinued. The patient gained consciousness less than 5 minutes after discontinuation of sevoflurane. He was discharged from the hospital on the same day without any complications. All procedures during operation were performed under supervision of an anesthesiologist and were monitored applying the same standard as for GA. At the 3-months follow-up, the patient did not show any PAH-related complication and was referred back to the local clinic for further follow-up.

### III. Discussion

PAH is a complication of CHD with VSD and is associated with significant perioperative risk for major complications, such as RV failure and systemic hypotension<sup>1,9</sup>. PAH with increased pulmonary vascular resistance (PVR) is associated with considerable morbidity and mortality. An analysis on 156 children (median age 4.0 years) with PAH who had undergone noncardiac surgery demonstrated outcome of 1.17% cardiac arrest and 0.78% death<sup>10</sup>. Another analysis on 92,881 children younger than 18 years old who had perioperative cardiac arrest at a tertiary referral center found that all children undergoing noncardiac surgery or procedure demonstrated 0.029% cardiac arrest and 0.016% death<sup>11</sup>.

General anesthesia causes decreases in functional residual capacity (FRC) and increases the chances of uneven distribution of ventilation. This may lead to a cascade of symptoms of ventilation-perfusion (V/Q) mismatch, hypoxia, hypoxic pulmonary vasoconstriction (HPV) and ultimately exacerbation of pulmonary hypertension<sup>12</sup>. Furthermore, increased PVR may lead to decreased RV function. Finally, RV failure can result in systemic hypotension<sup>2,4,9,13</sup>. Positive pressure ventilation during GA in PAH patients has high risk and should be conducted under the presence of well-trained professional anesthesiologist and with extra care.

In addition, airway instrumentation during GA can

trigger a rapid increase in PVR<sup>8</sup>. Tracheal intubation has been reported to precipitate pulmonary hypertensive crisis and death in critically ill adult patients with severe PAH<sup>4,15</sup>.

In other words, if possible, deep sedation may be safer than general anesthesia using positive pressure ventilation for patients with PAH. The patient in this case was born with CHD of large VSD and LV-RA shunt and had been taking HTN medication since 2007. For reasons stated above, the dental treatment was planned to be completed under deep sedation.

In numerous recent articles, sevoflurane inhalation and insufflation sedations have been suggested as new sedation methods<sup>5-8,16</sup>. Sevoflurane has low blood-gas partition coefficient, which allows rapid induction and emergence<sup>17</sup>. This characteristic is suitable in outpatient procedures. In general, sevoflurane is associated with clinical pulmonary vasodilation and is an accepted component of a balanced anesthetic technique in patients with PAH<sup>2</sup>. Especially, most of the previous reports on sevoflurane inhalation and/or insufflation sedations were conducted on premature or preterm infants, to whom general anesthesia imposes higher risk<sup>7,8,16</sup>. Therefore, sevoflurane inhalation and insufflation sedations can be used safely even in high-risk patient groups. In addition, the sedation depth can be easily controlled using inhalation and insufflation sedation, and they have auto-regulation effect, which also enables safer sedation<sup>18</sup>.

Friesen RH and Alswang M stated, when spontaneous ventilation through the natural airway is used, end-tidal CO<sub>2</sub> should be monitored via nasal cannulae<sup>19,20</sup>. In this case, the nasal cannula connected to capnograph was used, as previously described by Kim, *et al.*<sup>6</sup>. This type of nasal cannula not only delivers sevoflurane gas, but also allows monitoring of respiration gases (oxygen, carbon dioxide and sevoflurane). It also takes up less space on patient's face and allows wider access for the dental treatment (Fig. 2).

The procedural sedation was conducted with special attention to over-sedation, because over-sedation is associated with hypercarbia, hypoxemia and airway obstruction in patients managed with a natural airway and spontaneous ventilation<sup>19,21</sup>. Hypercarbia, hypoxemia and airway obstruction can trigger a rapid increase in PVR. As the appropriate dose of sevoflurane to achieve appropriate sedation depth varies per person, sedation depth was monitored by acquiring the electroencephalograph (EEG) and frontal electromyography (FEMG) sig-

nals using S/5 Entropy™ Module to prevent over-sedation and maintain proper sedation depth.

#### IV. Summary

This successful case of dental treatment in a patient with PAH through sevoflurane insufflation sedation has shown that sevoflurane insufflation sedation can be used effectively and safely in PAH patients and opened doors to sevoflurane sedation in high risk patients. Deep sedation by sevoflurane insufflation may be used as alternative method of GA in the field of cardiopulmonary dysfunction and in high-risk patients.

#### Acknowledgements

The authors extend our heartfelt gratitude to Eunji Lee for her hidden hard work.

#### References

1. Levine DJ : Diagnosis and management of pulmonary arterial hypertension: implications for respiratory care. *Respir Care*, 51:368-381, 2006.
2. Friesen RH, Williams GD : Anesthetic management of children with pulmonary arterial hypertension. *Paediatr Anaesth*, 18:208-216, 2008.
3. Hill NS, Roberts KR, Preston IR : Postoperative pulmonary hypertension: etiology and treatment of a dangerous complication. *Respir Care*, 54:958-968, 2009.
4. Pritts CD, Pearl RG : Anesthesia for patients with pulmonary hypertension. *Curr Opin Anaesthesiol*, 23:411-6, 2010.
5. Kim SO, Kim YJ, Koo YS, Shin TJ : Deep sedation with sevoflurane insufflated via a nasal cannula in uncooperative child undergoing the repair of dental injury. *Am J Emerg Med*, 31:894e1-894e3, 2013.
6. Kim SO, Kim YJ, Shin TJ, *et al.* : Deep sedation with sevoflurane inhalation via a nasal hood for brief procedure in pediatric patients. *Pediatr Emerg Care*, 29:926-928, 2013.
7. Sury MRJ, Harker H, Thomas ML : Sevoflurane sedation in infants undergoing MRI: a preliminary report. *Paediatr Anaesth*, 15:16-22, 2005.
8. Yu L, Sun H, Yang B *et al.* : Comparison of effective inspired concentration of sevoflurane in preterm infants with different postconceptual ages. *Paediatr Anaesth*, 21:148-152, 2011.
9. Fischer LG, Van Aken H, Bürkle H : Management of pulmonary hypertension: physiological and pharmacological considerations for anesthesiologists. *Anesth Analg*, 96:1603-1616, 2003.
10. Carmosino MJ, Friesen RH, Ivy DD *et al.* : Perioperative complications in children with pulmonary hypertension under going noncardiac surgery or cardiac catheterization. *Anesth Analg*, 104:521-527, 2007.
11. Flick RP, Sprung J, Warner DO *et al.* : Perioperative cardiac arrests in children between 1988 and 2005 at a tertiary referral center. *Anesthesiology*, 106:226-237, 2007.
12. Miller RD : Miller's anesthesia, 7th ed. Churchill Livingstone Inc., Philadelphia, 361-392, 2010.
13. Forrest P : Anaesthesia and right ventricular failure. *Anaesth Intensive Care*, 37:370-385, 2009.
14. Höhn L, Schweizer A, Licker M *et al.* : Circulatory failure after anesthesia induction in a patient with severe primary pulmonary hypertension. *Anesthesiology*, 91:1943-1945, 1999.
15. Höhn L, Licker M : Extreme pulmonary hypertension and anesthesia induction. *Anesthesiology* 93: 903-904, 2000.
16. De Sanctis Briggs V : Magnetic resonance imaging under sedation in newborns and infants: a study of 640 cases using sevoflurane. *Paediatr Anaesth*, 15: 9-15, 2005.
17. Smith I, Nathanson M, White PF : Sevoflurane - a long-awaited volatile anaesthetic. *Br J Anaesth*, 76: 435-445, 1996.
18. Conscious sedation with sevoflurane, *Anaesthesia tutorial of the week* 188, 2010.
19. Friesen RH, Alswang M : Changes in carbon dioxide tension and oxygen saturation during deep sedation for paediatric cardiac catheterization. *Paediatr Anaesth*, 6:15-20, 1996.
20. Friesen RH, Alswang M : End-tidal PCO<sub>2</sub> monitoring via nasal cannulae in pediatric patients: accuracy and sources of error. *J Clin Monit*, 12:155-159, 1996.
21. Motas D, McDermott NB, Vansickle T, Friesen RH : Depth of consciousness and deep sedation attained in children as administered by nonanaesthesiologists in a children's hospital. *Pediatr Anesth*, 14:256-60, 2004.

국문초록

## 폐동맥 고혈압 환자의 치과치료에서 세보플루란 흡입 진정의 사용 : 증례보고

지성인<sup>1</sup> · 김승오<sup>2</sup><sup>1</sup>단국대학교 치과대학 소아치과학교실, <sup>2</sup>단국대학교 치과대학 치과마취과학교실

폐동맥 고혈압은 좌우단락을 가진 선천성 심장질환의 흔한 합병증으로 폐동맥 고혈압 환자에서 높아진 폐혈관 저항은 생명에 위협을 초래한다. 전신마취시의 양압환기는 폐동맥압을 높이고, 폐혈류량은 감소시키므로 저산소증을 유발할 수 있으며, 이는 폐동맥 고혈압 환자에게서 불리하게 작용할 수 있다. 따라서 폐동맥 고혈압 환자에서는 양압환기보다는 자발호흡이 보다 안전할 것으로 생각된다.

만 5세 남환이 심한 저체중으로 본원으로 의뢰되었으며, 내원 당시 환자의 몸무게는 11 kg이었고, 2009년 팔로사정후로 완전 교정 수술을 받은 의과적 병력이 있었으며, 2007년부터 현재까지 고혈압 약을 복용하고 있다고 하였다. 환아는 다발성 우식을 가지고 있었으며, 치료는 경비케놀라를 사용한 세보플루란 흡입 진정 하에 진행하였다. 치료 내내 환아는 정상적인 생징후와 자발호흡을 유지하였으며, 이후에도 폐동맥 고혈압과 연관된 다른 합병증은 보이지 않았다.

폐동맥 고혈압 환자에서의 세보플루란 흡입 진정의 안전한 사용 증례를 통해서, 세보플루란 흡입 진정이 심혈관계 질환을 가진 환자들에서 전신마취의 대안으로 사용될 수 있는 가능성을 보여주었다.

**주요어:** 경비케놀라, 세보플루란, 자발호흡, 폐동맥고혈압, 흡입진정

www.kci.go.kr