

An Unusual Communication between the Radial and the Ulnar Nerves

Mi-Sun Hur, Kyu-Seok Lee

Department of Anatomy, Kwandong University College of Medicine

(Received 28 February 2013, revised 18 March 2013, accepted 19 March 2013, Published Online 30 March 2013)

Abstract : This case report describes an unusual communicating branch from radial to ulnar nerves in the axilla region on the right side of the Korean cadaver of a 59-year-old male.

The brachial plexus containing the communicating branch were extracted *en bloc*. The extracted specimens were immersed in Guanidine-HCl (0.2 M) for two weeks and then treated several times with an ultrasonic cleaner for an hour to soften the connective tissue around the nerve bundles.

The spinal root origins of this communicating branch were found to be largely C7 and some C8. Unexpectedly, the branches of the ulnar nerve innervated the medial two-third of the medial head of the triceps brachii muscle on the right side in the same cadaver. Numbers of nerve fibers of the communicating branch and the main distributing branch of the ulnar nerve to the triceps brachii muscle were 523 and 525, respectively.

This result implies that nerve fibers moving from the radial to the ulnar nerves may innervate the original distributing territories of the radial nerve. Another possibility is that a part of radial muscular branch to the triceps brachii muscle may be fused to the ulnar nerve in their distributing territories.

Keywords : Radial to ulnar nerves communication, Radial nerve, Ulnar supply to triceps brachii muscle, Ulnar nerve

Introduction

Communication between the terminal nerves of the brachial plexus has been often reported, that is, the median and musculocutaneous nerves in the upper arm [1,2], median and ulnar nerves (Martin-Gruber and Marinacci anastomoses) in the forearm [3-5], ulnar and median nerves (Riche-Cannieu anastomosis) in the hand [6]. All of these communications were connections between nerves derived from the anterior division of the brachial plexus. However, in literatures, it could not be found to describe communication from radial to ulnar nerves, which are connections between nerves derived from the anterior and posterior

divisions.

Bergmann et al. (1988) [7] described an anomalous branch of the ulnar nerve innervating the medial head of the triceps brachii muscle. These innervations are uncommon, because the nerve derived from the anterior division distributes the territories of the nerve derived from the posterior division.

If these two anomalies, which are communication from radial to ulnar nerves and the ulnar nerve innervating the medial head of the triceps brachii muscle, appeared in same cadaver, a correlation of the two variations can be deduced. The purpose of this paper is to present a detailed report of unusual communication between the radial and the ulnar nerves and uncommon innervation of the ulnar nerve.

Materials and Methods

An unusual unilateral communicating branch was found in formalin-fixed Korean cadaver of a 59-year-old male

This work was supported by Basic Science Research Program through the National Research Foundation of Korea (NRF) funded by the Ministry of Education and Technology (2009-0071338).

Correspondence to : Kyu-Seok Lee (Department of Anatomy, Kwandong University College of Medicine, 522 Naegok-Dong, Gangneung 210-701, Gangwon-do, Korea)

E-mail : kslee@kwandong.ac.kr

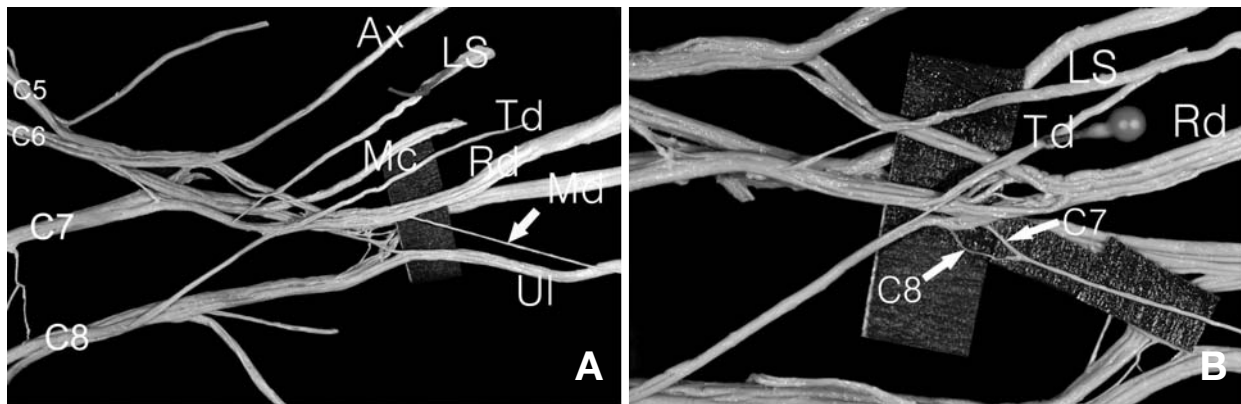


Fig. 1. Photograph showing the communicating branch between the radial and the ulnar nerves and its spinal nerve components in the posterior aspect (right side). The communicating branch (arrow) arises as short distance from the origin point of the radial nerve (A). After separating nerve fascicles, the components of the communicating branch are confirmed that it derives from mainly C7 and some C8 (B). Ax: axillary nerve, Ul: ulnar nerve, Rd: radial nerve, Td: thoracodorsal nerve, LS: lower subscapular nerve, Mc: Musculocutaneous nerve, Md: median nerve.

during dissection in a gross anatomy course. The brachial plexus containing the communicating branch were extracted *en bloc*. The extracted specimens were immersed in Guanidine-HCl (0.2 M) for two weeks and then treated several times with an ultrasonic cleaner for an hour to soften the connective tissue around the nerve bundles. The processed brachial plexus were dissected carefully removing the connective tissue around the nerve bundles to expose the running of the nerve fibers under a surgical microscope (Carl Zeiss OPMI-FC, $\times 7.5$), and to confirm the spinal root compositions of the communicating branch [8] (Lee 2007). Applying the routine histological preparation, numbers of the nerve fiber were counted to estimate the correlation of the two variant nerve branches.

Results

The unusual communicating branch from the radial to the ulnar nerves was found unilaterally in the axilla region on the right side. The spinal root origins of this communicating branch were largely C7 and some C8 (Fig. 1). In the same cadaver, another variant was observed unilaterally on the right side. The branches of the ulnar nerve innervated the medial side of the medial head of the triceps brachii muscle (Fig. 2). Numbers of nerve fibers of the communicating branch and the main distributing branch of the ulnar nerve to the triceps brachii muscle were 523 and 525, res-




Fig. 2. The branches of the ulnar nerve innervating the triceps brachii muscle. The branches (arrows) of the ulnar nerve innervate the medial two-third of the medial head (med.h) of the triceps brachii muscle. Ul: ulnar nerve, BA: brachial artery, Mc: musculocutaneous nerve, Bra.m.: brachialis muscle.

pectively (Fig. 3). Thus two branches had similar quantities of the nerve fibers.

Discussion

The communicating branch was believed to occur when the nerve fibers that run into the different route (nerve) return to the original route (nerve), such as in Martin-Gruber anastomosis, in which the ulnar nerve components that are mixed with the median nerve return to their original innervating territories. Therefore this result implies that nerve

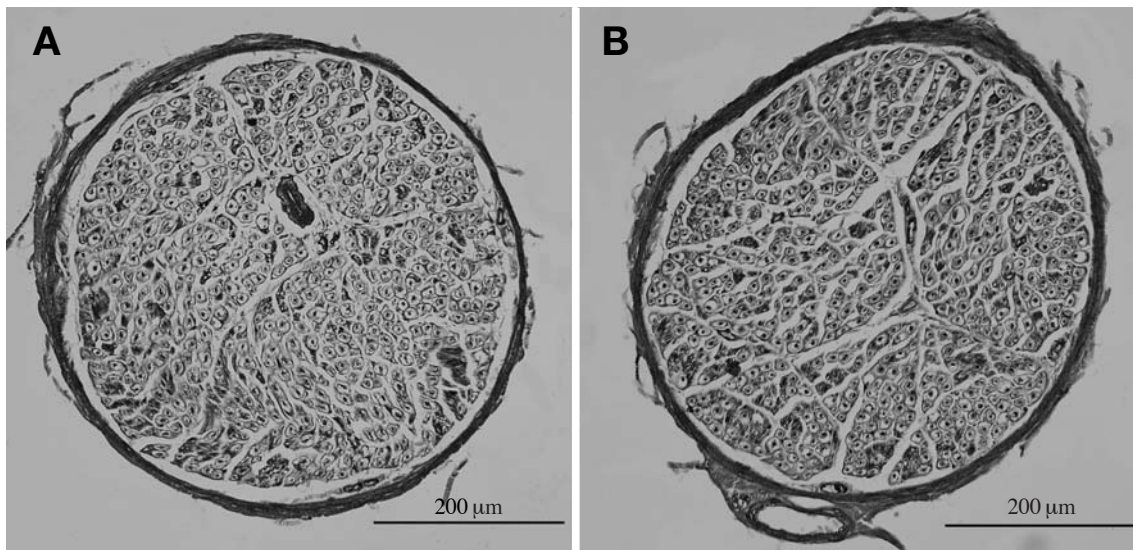


Fig. 3. Histologic comparison of the communicating branch between the radial to the ulnar nerves (A) and main distributing branches to the medial head of the triceps brachii muscle (B). Numbers of nerve fibers of communicating branch and main distributing branch of the ulnar nerve to the triceps brachii muscle are 523 and 525, respectively.

fibers moving from the radial to the ulnar nerves may innervate the original distributing territories of the radial nerve.

Bergman et al. (1988) [7] described a muscular branch of the ulnar nerve innervating the medial head of the triceps brachii muscle. However, the authors could not explain the “occurring cause of the variation”. We believe that the communicating branch certainly shows the “occurring cause” in the present study. The spinal root compositions of this communicating branch were largely C7 and some C8, and the triceps brachii muscle was normally innervated by C7 and C8 [9]. Even though terminal innervation of the communicating branch was not observed in the arm, numbers of nerve fibers of the communicating branch and the main distributing branch of the ulnar nerve to the triceps brachii muscle were similar. Thus it is thought that the communicating branch from the radial to the ulnar nerves innervated the original distributing territories of the radial nerve. Some articles have described the variant sensory distribution of the dorsum of the hand [7,10,11]. It is known that the sensory nerve innervating the muscle may convey proprioceptive impulse from the muscle. If the communicating branch in this result was sensory components, the ulnar dominant sensory distribution of the dorsum of the hand may have appeared.

As another possibility of the occurrence of this variant

communication, the communicating branch may be driven from the radial muscular branch to the medial head of triceps brachii muscle. This muscular branch runs generally close to the ulnar nerve. A part of this branch may be fused to the ulnar nerve in their distributing territories. This muscular branch is called as ‘ulnar collateral nerve’. Therefore, this unusual communication could appear in running process of the neighboring nerves. The “occurring cause” may present in the proximal or distal portion of the related nerves of various communications of several regions.

References

1. Venieratos D, Anagnostopoulou S. Classification of communications between the musculocutaneous and median nerves. *Clin Anat.* 1998; 11:327-31.
2. Saeed M, Rufai AA. Median and musculocutaneous nerves: variant formation and distribution. *Clin Anat.* 2003; 16:453-7.
3. Shu HS, Chantelot C, Oberlin C, Alnot JY, Shao H. Martin-Gruber communicating branch: anatomical and histological study. *Surg Radiol Anat.* 1999; 21:115-8.
4. Meenakshi-Sundaram S, Sundar B, Arunkumar MJ. Marinacci communication: an electrophysiological study. *Clin Neurophysiol.* 2003; 114:2334-7.
5. Lee KS, Oh CS, Chung IH, Sunwoo IN. An anatomic study

- of the Martin-Gruber anastomosis: electrodiagnostic implication. *Muscle Nerve*. 2005; 31:95-7.
6. Budak F, Gönenç Z. Innervation anomalies in upper and lower extremities. *Electromyogr Clin Neurophysiol*. 1999; 39:231-4.
 7. Bergman RA, Thompson SA, Afifi AK, Saadeh FA. *Compendium of human anatomic variation*. Baltimore: Urban & Schwarzenberg; 1988. p.142.
 8. Lee KS. Variation of the spinal nerve compositions of thoracodorsal nerve. *Clin Anat*. 2007; 20:660-2.
 9. Lindner HH. *Clinical anatomy*. International ed. London: Appleton & Lange; 1989. p. 536.
 10. MaCluskey LF. Anomalous superficial radial sensory innervation of the ulnar dorsum of the hand: a cause of paradoxical presentation of ulnar sensory function. *Muscle Nerve*. 1996; 19:923-5.
 11. Kurivilla A, Laaksonen S, Falck B. Anomalous superficial radial nerve: a patient with probable autosomal dominant. *Muscle Nerve*. 2002; 26:716-9.

노신경과 자신경 사이 연결가지의 형태변이

허미선, 이규석

관동대학교 의과대학 해부학교실

간추림 : 이 연구의 목적은 겨드랑부위에서 노신경에서 자신경으로의 연결가지의 형태변이를 기술하는 데 있다.

노신경과 자신경 사이 연결가지를 포함한 팔신경얼기를 한 덩이로 떼어내, Guanidine-HCl (0.2 M)에 2주동안 담근 후, 초음파세척기로 여러 번 처리하여 신경다발 주위의 결합조직을 부드럽게 하여 신경다발을 분리하였다.

노신경에서 자신경으로의 연결가지를 구성하는 척수신경은 대부분이 C7이었고, 일부 C8이 참여를 하였다. 같은 시신 오른 팔에서 위팔세갈래근에 분포하는 자신경의 분포변이가 관찰되었다. 이 자신경가지는 위팔세갈래근 안쪽갈래의 안쪽 2/3 부위에 분포하였다. 자신경과 노신경 사이의 연결가지와 위팔세갈래근에 분포하는 자신경 가지의 신경섬유 수는 각각 523개와 525개였다.

이 결과는 노신경에서 자신경으로 연결되는 신경섬유가 노신경이 원래 분포하는 부위에 분포하는 것을 나타내며, 또 다른 가능성으로는 노신경의 근육가지가 자신경가지와 분포영역에서 가깝게 달리며 합쳐질 수 있다는 것을 의미한다.

찾아보기 낱말 : 노신경에서 자신경으로의 연결가지, 노신경, 위팔세갈래근에 분포하는 자신경, 자신경