

Sparassis crispa Attenuates Carbon Tetrachloride-Induced Hepatic Injury in Rats

Guang Hai Yan¹, Yun Ho Choi²

¹Department of Anatomy and Histology and Embryology, Yanbian University School of Basic Medical Sciences

²Department of Anatomy, Medical School, Institute for Medical Sciences, Chonbuk National University

(Received 10 April 2014, revised 19 June 2014, accepted 17 July 2014, Published Online 30 September 2014)

Abstract : *Sparassis crispa* is an edible mushroom with various medicinal properties. Here we demonstrate the effect of *Sparassis crispa* on carbon tetrachloride (CCl₄)-induced hepatotoxicity and the underlying mechanism.

To evaluate the hepatoprotective effects of *Sparassis crispa* ethanol extract (SCE), 50 male Sprague-Dawley rats were equally divided into 5 groups. Group I is the normal control rats with an intraperitoneal (i.p.) 0.5% carboxy methyl cellulose (CMC) pretreatment and olive oil treatment. Group II is the model group with an i.p. 0.5% CMC and 0.5 mL/kg CCl₄ treatment. Group III and IV is the CCl₄-administered rats pretreated with an i.p. 100 and 200 mg/kg SCE, respectively. Group V includes the silymarin group with an i.p. 50 mg/kg silymarin and CCl₄ treatment.

At 16 h after the CCl₄ treatment, the levels of serum aminotransferases, TNF- α , and lipid peroxidation were substantially increased, whereas the activity of hepatic antioxidative enzymes, such as superoxide dismutase and catalase, was decreased. These changes were attenuated by SCE. The histological studies also showed that SCE inhibited the CCl₄-induced liver injury. Furthermore, the contents of hepatic nitrite, inducible nitric oxide synthase (iNOS), and cyclooxygenase-2 (COX-2) were elevated after CCl₄ treatment, while the cytochrome P450 2E1 (CYP2E1) expression was suppressed. SCE treatment inhibited the formation of liver nitrite, reduced the over-expression of iNOS and COX-2 proteins, but restored the liver CYP2E1 content compared with the CCl₄-treated model group.

The present data elucidate that SCE protects the liver against CCl₄-induced acute hepatotoxicity, which might be due to its ability to restore the CYP2E1 function and suppress the inflammatory responses, in combination with its capacity to reduce oxidative stress.

Keywords : *Sparassis crispa*, Carbon tetrachloride, Hepatotoxicity

Introduction

Carbon tetrachloride (CCl₄) is a well-known hepatotoxin that is widely used to induce toxic liver injury in a range of laboratory animals. CCl₄-induced hepatotoxicity is believed to involve two phases. The initial phase involves the

metabolism of CCl₄ by cytochrome P450 to the trichloromethyl radicals (CCl₃· and/or CCl₃OO·), which lead to membrane lipid peroxidation and finally to cell necrosis [1,2]. The second phase of CCl₄-induced hepatotoxicity involves the activation of Kupffer cells, which is accompanied by the production of pro-inflammatory mediators [3]. In addition, it has been shown that CCl₄-induced toxicity may stimulate endogenous reactive oxygen and nitrogen species that have also been suggested to play an important role in the pathogenesis of hepatotoxicity [4]. Hierholzer et al. suggested that inducible nitric oxide synthase (iNOS)-generated nitric oxide not only directly contributes to tis-

The author(s) agree to abide by the good publication practice guideline for medical journals.

The author(s) declare that there are no conflicts of interest.

Correspondence to : Yun Ho Choi (Department of Anatomy, Medical School, Institute for Medical Sciences, Chonbuk National University)

E-mail : why76@jbnu.ac.kr

sue damage but also upregulates the inflammatory response through specific signaling mechanisms [5]. Recent reports have demonstrated that induced nitric oxide overproduction occurs in the liver of rats with CCl₄-induced acute liver injury and suggested that iNOS may act as a mediator in the pathogenesis of hepatotoxicity in rats [6-8].

Sparassis crispa, also known as cauliflower mushroom in English, is an edible mushroom with various medicinal properties that has recently been cultivated in Korea, China, and Japan. It is a brown root fungus that grows primarily on the stumps of coniferous trees [9]. *Sparassis crispa* has been reported to exhibit many biological activities, including tumor suppressive, anti-angiogenic, anti-allergic, and anti-diabetic effects [10,11]. Moreover, the administration of soluble β -glucan preparation from *Sparassis crispa* has been found to modulate cytokine production in mice [12]. However, there is little information about the pharmacological action of this mushroom on acute liver injury caused by CCl₄.

The aim of our study is to evaluate the protective effect of *Sparassis crispa* against CCl₄-induced hepatotoxicity and to elucidate the possible mechanisms underlying these defensive effects in rats. The effect of *Sparassis crispa* on CCl₄-induced acute liver injury was also compared to the effect of silymarin.

Materials and Methods

1. Ethics statements

All experiments were approved by Institutional Animal Care and Use Committee of Yanbian University School of Medical Sciences, and were in accordance with the Guide for the Care and Use of Laboratory Animals, published by the National Institutes of Health (NIH Publication 82-23, revised 1996) as well as ARRIVE (Animal Research: Reporting In Vivo Experiments) guidelines, produced by the National Centre for the Replacement, Refinement and Reduction of Animals in Research (NC3Rs). All surgery was performed under ethyl ether anesthesia, and all efforts were made to minimize suffering.

2. Preparation of *Sparassis crispa* ethanol extract (SCE)

The dried fruiting bodies of *Sparassis crispa* were purchased from the Hangzhou Xueyu Biological Technology

Co., Ltd (Zhejiang, China). The voucher specimens were deposited in the College of Pharmacy, Yanbian University. The active *Sparassis crispa* was isolated using ethanol precipitation methods. Briefly, *Sparassis crispa* was soaked into 50% ethanol and boiled at 90°C for 4 h and filtered through a 270-mesh sieve. The sludge from the primary extraction was then extracted twice using the same procedure and evaporated to dryness with a rotary vacuum evaporator (Yiheng Technology Ltd., Shanghai, China) at 40°C under reduced pressure. The yield was 22% of the raw *Sparassis crispa*. The extract filtered with 0.2 μ m syringe filter was adjusted with 0.5% carboxy methyl cellulose (CMC, Sigma, St. Louis, MO, USA) solution to give a stock solution in 10 mg/mL for experimental use. The solution was stored at 4°C until use.

3. Animals and treatment regimens

Male Sprague Dawley rats (house section of Yanbian University Health Science Center, China) weighing 180-200 g were used throughout the experiment. Animals were housed under standard environmental conditions (23 \pm 1°C, 55 \pm 5% humidity, and a 12 h light: 12 h dark cycle) and maintained with free access to water and a standard laboratory diet *ad libitum*. A total of 50 rats were assigned to five groups as follows group I, normal control rats with an intraperitoneal (i.p.) 0.5% CMC (vehicle) pretreatment and olive oil (Wako Pure Chemical Ind., Osaka, Japan) treatment; group II, the model group with an i.p. 0.5% CMC and CCl₄ (Merck, Darmstadt, Germany) treatment; group III, the low-dose SCE group with an i.p. 100 mg/kg SCE and CCl₄ treatment; group IV, the high-dose SCE group with an i.p. 200 mg/kg SCE and CCl₄ treatment; group V, the silymarin group with an i.p. 50 mg/kg silymarin (Sigma) and CCl₄ treatment. All rats were pretreated with the vehicle, SCE, or silymarin suspension daily for a period of 5 d. The SCE or silymarin suspension for i.p. administration was prepared by suspending in 0.5% CMC. At 1 h after the last pretreatment, 50% CCl₄ in olive oil was given intraperitoneally to the rats of groups II ~ V at a dose of 1 mL/kg of body weight, while olive oil (vehicle) was injected to group I. Rats were anesthetized with ethyl ether and blood was collected from the abdominal aorta 16 h after CCl₄ administration. All animals were killed by decapitation at the end of the experiment. For each rat, the liver was isolated and stored at -70°C for later

analysis, except for the part in the left lobe, which was used for histological analysis.

4. Assessment of serum aminotransferase activities

The serum alanine aminotransferase (ALT) and aspartate aminotransferase (AST) activities were determined using a Hitachi 747 automatic analyzer (Hitachi, Tokyo, Japan).

5. Serum TNF- α assay

The serum concentration of TNF- α was measured by using a rat TNF- α ELISA kit (eBioscience, San Diego, CA, USA) according to the corresponding protocol.

6. Oxidative damage assay

Hepatic malondialdehyde (MDA), a degrading product of lipid peroxidation known as thiobarbituric acid-reactive substances (TBARS), was also determined according to the thiobarbituric acid methods using an MDA test kit (Nanjing Jiancheng Bioengineering Institute, Nanjing, China).

7. Antioxidative enzyme assays

Hepatic antioxidative defense enzymes including superoxide dismutase (SOD) and catalase (CAT) were assayed by using SOD and CAT detection kits (Nanjing Jiancheng Bioengineering Institute).

8. Hepatic nitrite estimation

Hepatic nitrite level was estimated enzymatically with a

colorimetric nitrite detection kit (Nanjing Jiancheng Bioengineering Institute).

9. Western blot immunoassay

Freshly isolated liver tissue was homogenized in a lysis buffer. A 20 μ g sample of protein from the liver homogenates was loaded per lane on 7.5% or 10% polyacrylamide gels. Electrophoresis was then performed. The proteins were then transferred to nitrocellulose membranes. Western blot analysis was performed using the polyclonal antibodies against rat inducible nitric oxide synthase (iNOS; Transduction Laboratories, San Jose, CA, USA), cyclooxygenase-2 (COX-2; Cayman, Ann Arbor, MI, USA), Glyceraldehyde-3-phosphate dehydrogenase (GAPDH, Santa Cruz Biochemicals, Santa Cruz, CA, USA), and goat polyclonal anti-rat CYP 2E1 antibody (Chemicon Co., Temecula, CA, USA). The binding of all the antibodies was detected using an ECL detection system (iNtRON Biotechnology Co., Ltd., Seoul, Korea), according to the manufacturer's instructions. The intensity of the immunoreactive bands was determined using a densitometric analysis program (Image Gauge V3. 12; Fuji Photo Film Co., Ltd., Tokyo, Japan).

10. Histological analysis

Twenty-four hours after administering CCl₄, a small piece of liver tissue from the anterior portion of the left lateral lobe was removed for histological analysis. The sample was fixed by immersing it in 10% neutral-buffered formalin. The sample was then embedded in paraffin, sliced into 5 μ m

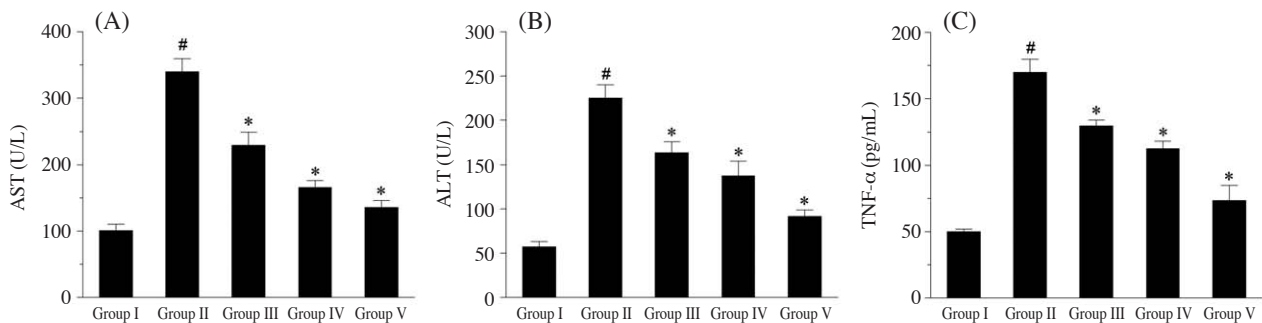


Fig. 1. Effect of *Sparassis crispa* ethanol extract (SCE) against CCl₄-induced alteration of the liver function parameters in serum. (A) aspartate aminotransferase, AST; (B) alanine aminotransferase, ALT; (C) tumor necrosis factor (TNF)- α . Data are presented as the mean \pm SEM ($n=10$) in each group. The animals were pretreated with SCE, silymarin, or a vehicle. CCl₄ was given intraperitoneally on the last day of the treatment protocol, and the animals were sacrificed 16 h after CCl₄ treatment. [#] $p < 0.05$, significantly different from group I. ^{*} $p < 0.05$, significantly different from group II. Group I, normal control; group II, model (CCl₄ alone); group III, 100 mg/kg of SCE+CCl₄; group IV, 200 mg/kg of SCE+CCl₄; group V, 50 mg/kg of silymarin+CCl₄.

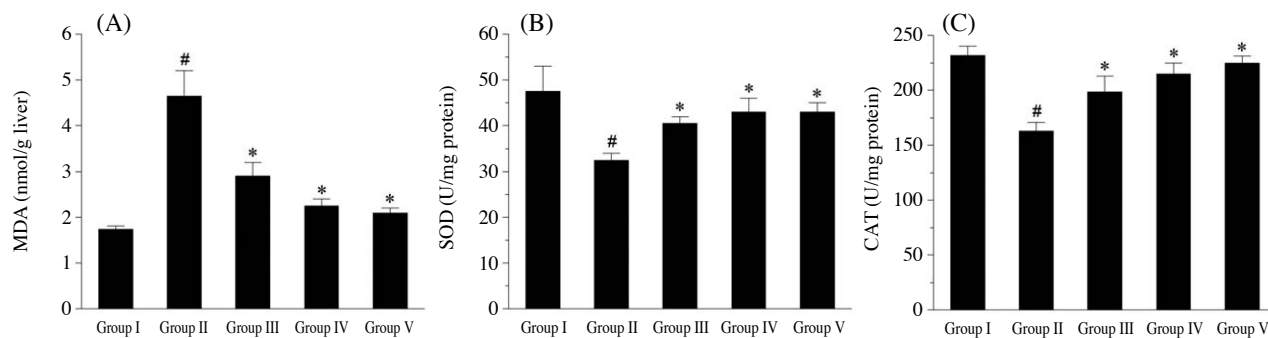


Fig. 2. Effect of *Sparassis crisper* ethanol extract (SCE) on CCl_4 -induced alteration of the hepatic lipid peroxidation and antioxidative enzyme activities. (A) malondialdehyde, MDA; (B) superoxide dismutase, SOD; (C) catalase, CAT. Data are presented as the mean \pm SEM ($n=10$) in each group. The animals were pretreated with SCE, silymarin, or a vehicle. CCl_4 was given intraperitoneally on the last day of the treatment protocol, and the animals were sacrificed 16 h after CCl_4 treatment. [#] $p < 0.05$, significantly different from group I. ^{*} $p < 0.05$, significantly different from group II. Group I, normal control; group II, model (CCl_4 alone); group III, 100 mg/kg of SCE+ CCl_4 ; group IV, 200 mg/kg of SCE+ CCl_4 ; group V, 50 mg/kg of silymarin+ CCl_4 .

sections, and stained with hematoxylin-eosin for a blinded histological assessment. The histological changes were evaluated in nonconsecutive, randomly chosen $\times 100$ histological fields.

11. Statistics

All the results are reported as the means \pm SEM. The overall significance of the data was examined by one-way analysis of variance (ANOVA). The differences between the groups were considered significant at $p < 0.05$ with the appropriate Bonferroni correction made for multiple comparisons.

Results

1. Serum aminotransferase activities and TNF- α levels

Fig. 1 showed that the rats of the model group (group II) induced with a single dose of CCl_4 developed hepatic damage as compared with the normal control group (group I). This was evident from marked modifications of liver function parameters AST and ALT in the serum. SCE and silymarin administration showed a significant reduction in AST and ALT activities as compared with the CCl_4 -intoxicated model group. In the rats of groups III and IV, the intraperitoneal administration of SCE at doses of 100 and 200 mg/kg prior to the CCl_4 challenge was observed to dose-dependently reverse the CCl_4 -induced alteration of AST and ALT. The CCl_4 treatment also induced an increase in the serum TNF- α level as compared to the

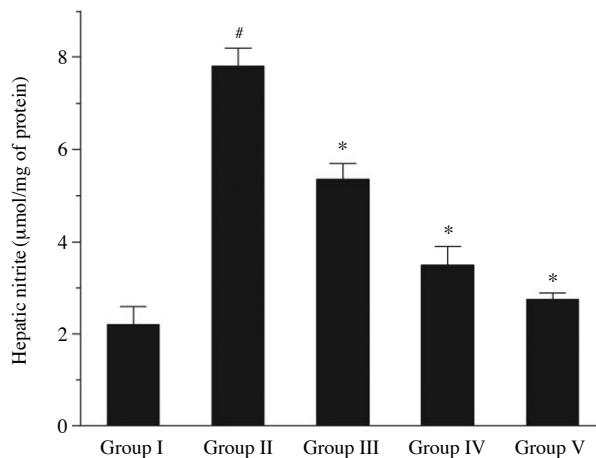


Fig. 3. Effect of *Sparassis crisper* ethanol extract (SCE) on the hepatic nitrite level. Data are presented as the mean \pm SEM ($n=10$) in each group. The animals were pretreated with SCE, silymarin, or a vehicle. CCl_4 was given intraperitoneally on the last day of the treatment protocol, and the animals were sacrificed 16 h after CCl_4 treatment. [#] $p < 0.05$, significantly different from group I. ^{*} $p < 0.05$, significantly different from group II. Group I, normal control; group II, model (CCl_4 alone); group III, 100 mg/kg of SCE+ CCl_4 ; group IV, 200 mg/kg of SCE+ CCl_4 ; group V, 50 mg/kg of silymarin+ CCl_4 .

normal control group. However, the serum TNF- α level in both SCE and silymarin-supplemented groups was significantly lower than that in the CCl_4 -treated group. In addition, SCE alone did not alter the serum TNF- α concentration (data not shown).

2. Lipid peroxidation and antioxidative enzyme system

An expected increase of the hepatic lipid peroxidative index in the CCl_4 -treated model group also confirmed that

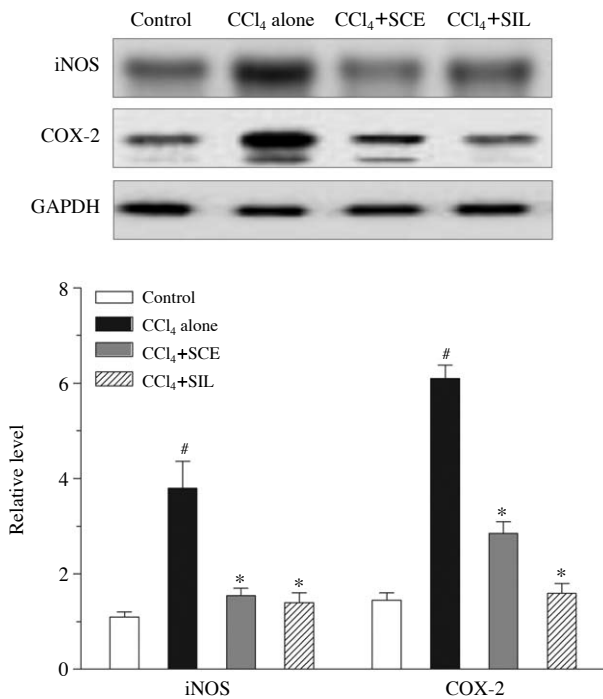


Fig. 4. Effect of *Sparassis crispa* ethanol extract (SCE) on the hepatic iNOS and COX-2 protein expression. Data are presented as the mean \pm SEM ($n=10$) in each group. The animals were pretreated with SCE, silymarin (SIL), or a vehicle. CCl₄ was given intraperitoneally on the last day of the treatment protocol, and the animals were sacrificed 16 h after CCl₄ treatment. Glyceraldehyde-3-phosphate dehydrogenase (GAPDH) were used as an internal control. Density ratio vs. GAPDH was measured using a densitometer. [#] $p < 0.05$, significantly different from control. ^{*} $p < 0.05$, significantly different from CCl₄ alone. Control, normal group; CCl₄ alone, model group; CCl₄+SCE, group with 200 mg/kg SCE and CCl₄ treatment; CCl₄+SIL, group with 50 mg/kg silymarin and CCl₄ treatment.

oxidative damage had been induced (Fig. 2). When CCl₄ was injected into the rats that had been pretreated with SCE or silymarin, the level of MDA in the liver were significantly lower than that in the CCl₄-treated model group. The observed suppression of oxidative damage in the CCl₄-injured liver by SCE administration suggests that SCE was antioxidative and hepatoprotective. On the other hand, CCl₄ also induced substantial modifications to the hepatic antioxidative enzymes (Fig. 2). The data show that the decrease levels of hepatic SOD and CAT activity as the result of CCl₄ injection were significantly elevated in SCE and silymarin groups.

3. Hepatic nitrite level

CCl₄-induced hepatotoxicity is accompanied by the pro-

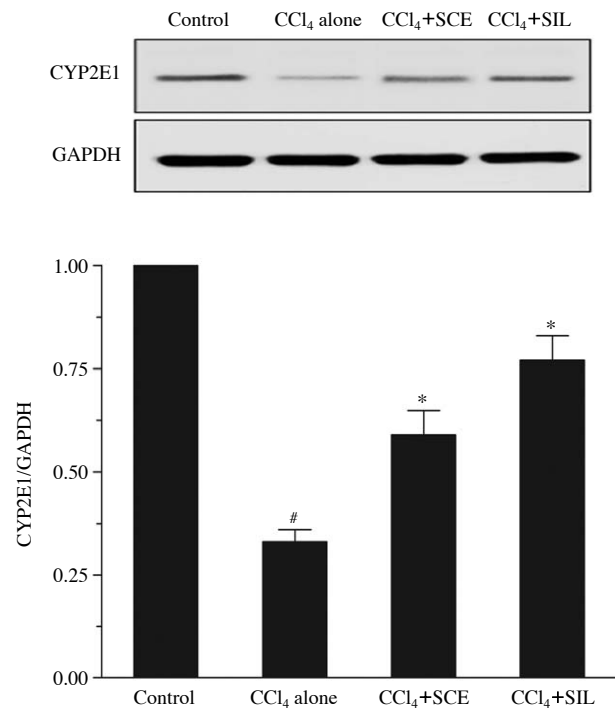


Fig. 5. Effect of *Sparassis crispa* ethanol extract (SCE) on the Hepatic CYP2E1 protein expression. Data are presented as the mean \pm SEM ($n=10$) in each group. The animals were pretreated with SCE, silymarin (SIL), or a vehicle. CCl₄ was given intraperitoneally on the last day of the treatment protocol, and the animals were sacrificed 16 h after CCl₄ treatment. Glyceraldehyde-3-phosphate dehydrogenase (GAPDH) were used as an internal control. Density ratio vs. GAPDH was measured using a densitometer. [#] $p < 0.05$, significantly different from control. ^{*} $p < 0.05$, significantly different from CCl₄ alone. Control, normal group; CCl₄ alone, model group; CCl₄+SCE, group with 200 mg/kg SCE and CCl₄ treatment; CCl₄+SIL, group with 50 mg/kg silymarin and CCl₄ treatment.

duction of pro-inflammatory mediator such as iNOS. A significant rise in the hepatic nitrite level was observed in CCl₄-induced animals when compared with control rats. However, the rats pretreated with SCE or silymarin showed a decreased nitrite level compared with the model animals (Fig. 3).

4. Hepatic iNOS and COX-2 protein expression

Western blot analysis also revealed that the amount of hepatic iNOS and COX-2 proteins increased considerably after the CCl₄ administration. However, the increase in iNOS and COX-2 protein levels was significantly attenuated by SCE or silymarin (Fig. 4). SCE treatment alone did not alter the protein levels of iNOS and COX-2 (data not shown).

5. Hepatic microsomal P450 2E1 protein expression

Fig. 5 shows the protein expression of cytochrome P450 (CYP) 2E1 in the liver microsomes. Compared to the normal control group, the rats receiving CCl_4 alone showed a significant decrease in the CYP2E1 protein level. In con-

trast, in the rats pretreated with SCE or silymarin, a higher level of CYP2E1 was found than that in the rats intoxicated with CCl_4 alone. The restoration of CYP2E1 by SCE supplementation implies that SCE could have a hepatoprotective effect which led to rapid recovery from CCl_4 -induced liver injury.

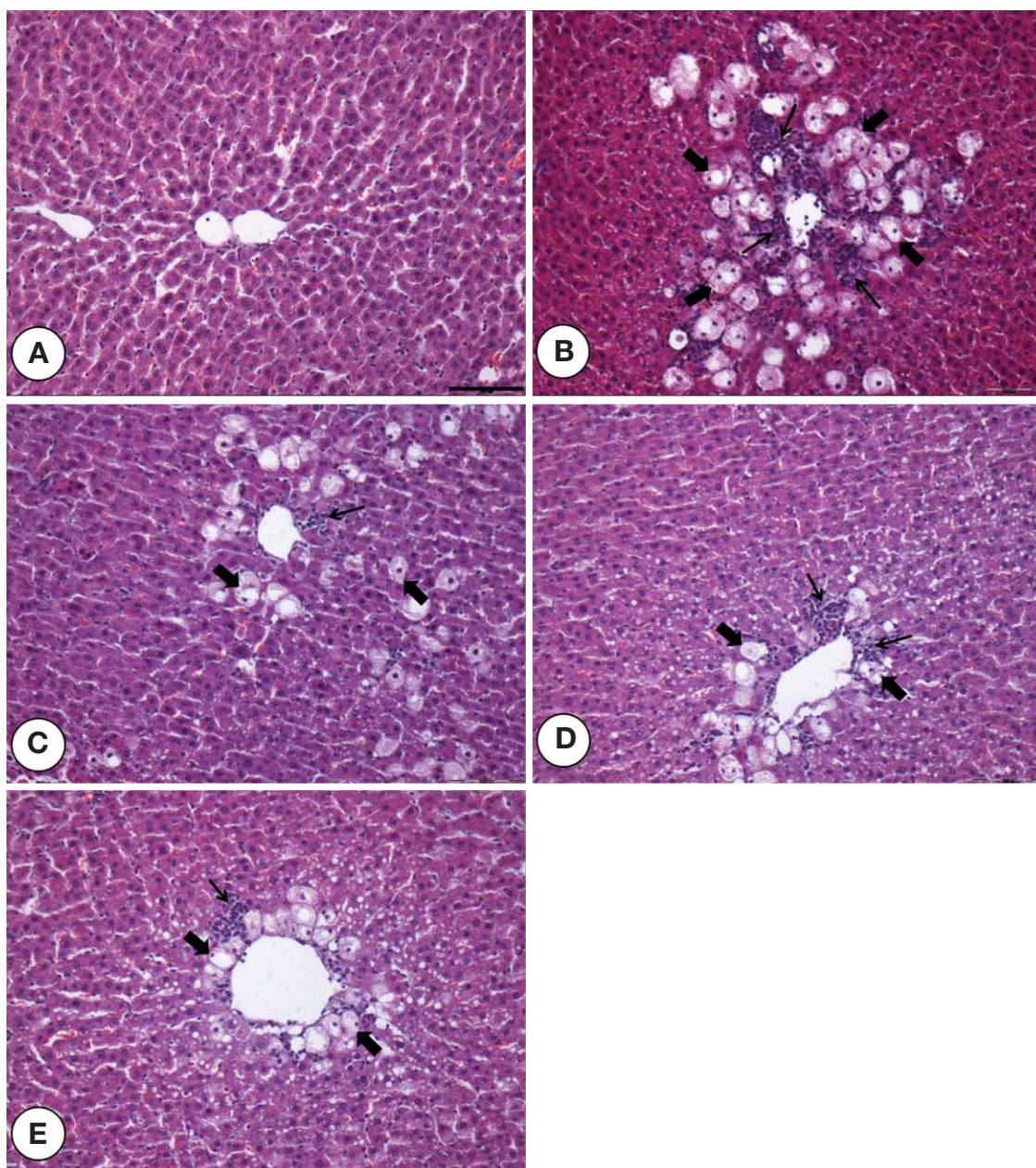


Fig. 6. Histological analysis of the livers after CCl_4 administration. The animals were pretreated with *Sparassis crispa* ethanol extract (SCE), silymarin, or a vehicle. Typical images were chosen from the different experimental groups. Black thick arrows, hepatocytes with lipid vacuoles; black thin arrows, infiltrating mononuclear cells. (A) Group I, normal control; (B) group II, model (CCl_4 alone); (C) group III, 100 mg/kg of SCE+ CCl_4 ; (D) group IV, 200 mg/kg of SCE+ CCl_4 ; (E) group V, 50 mg/kg of silymarin+ CCl_4 . Histological sections were prepared from liver 16 h after CCl_4 exposure and stained with hematoxylin and eosin (original magnification $\times 100$, calibration bar = 100 μm).

6. Histological analysis

A liver tissue section from normal rats is shown in Fig. 6A. In rats receiving CCl_4 alone, the liver histology at 16 h after CCl_4 exposure showed extensive hepatocellular damage such as hepatosteosis and inflammation, which was evidenced by the presence of hepatocyte lipid vacuolation and infiltrating lymphocyte-rich mononuclear cells around vena centralis (Fig. 6B). These histopathological changes were ameliorated by both SCE (100 and 200 mg/kg) and silymarin (50 mg/kg) treatments (Fig. 6C, D, and E).

Discussion

Acute and chronic liver diseases constitute a global concern, and the medical treatments for these diseases are often difficult to handle and have limited efficacy. Therefore, there has been considerable interest in the role of complementary and alternative medicines for treatment of liver diseases [13]. Developing therapeutically effective agents from natural products may reduce the risk of hepatotoxicity when the drug is used clinically. The present *in vivo* study has demonstrated the hepatoprotective potential of *Sparassis crispa*.

Liver injury induced by CCl_4 is a common model for screening the hepatoprotective activity of drugs because this chemical is a potent hepatotoxin and a single exposure can rapidly lead to severe hepatic necrosis and steatosis [2,14]. Increases in serum AST and ALT levels by CCl_4 have been attributed to hepatic structural damage because these enzymes are normally localized to the cytoplasm and released into the circulation after cellular damage has occurred [14]. The present study showed that SCE significantly preserves the structural integrity of the hepatocellular membrane and suppresses CCl_4 -induced hepatic injury, as demonstrated by the reduction in serum marker enzyme activities. This phenomenon was also supported by histological examinations. In this study, CCl_4 caused a variety of histological changes to the liver, including hepatosteosis and inflammation. These changes were significantly attenuated by SCE. Furthermore, the hepatoprotective effect of SCE seemed to be as beneficial as that of silymarin, which has been used as a potent hepatoprotective agent. Therefore, it is suggested that SCE may have potential clinical application for treating liver diseases.

It is generally accepted that the hepatotoxicity of CCl_4

is the result of reductive dehalogenation. Lipid peroxidation is accepted to be one of the principal causes of CCl_4 -induced liver injury and is mediated by the production of free radical derivatives of CCl_4 . Therefore, antioxidant activity and/or the inhibition of free radical generation are important in terms of protecting the liver from CCl_4 -induced damage [2]. In general, antioxidative enzymes such as SOD and CAT are easily inactivated by lipid peroxides or reactive oxygen species (ROS), which results in decreased activities of these enzymes in CCl_4 toxicity [1]. Our results showed that, in parallel with the alteration in serum marker enzymes, increased level of lipid peroxidation (MDA) as well as decreased activities of SOD and CAT occurred in liver injury induced by CCl_4 , implying downregulation of numerous antioxidative reactions in liver. SCE pretreated animals showed a significant reduction in the level of the hepatic peroxidative marker (MDA) with concomitant improvement in the hepatic antioxidative defense system. This suggests that SCE may be able to protect against the oxidative damage of hepatic cellular membrane *via* a free radical scavenging property.

The results also show that SCE suppresses an increase in the serum TNF- α level. TNF- α is a pro-inflammatory cytokine produced predominantly by macrophage and plays a key role in the host defense response to injury and infection. While low levels of TNF- α may play a role in cell protection, excessive amounts cause cell impairment. An increase in the TNF- α level has been directly correlated with the histological evidence of hepatic necrosis and the elevation in the serum aminotransferase levels [15]. DeCicco et al. have reported the stimulation of TNF- α production in both serum and liver following CCl_4 administration, and it is suggested that $\text{CCl}_3\cdot$ activates Kupffer cells to release TNF- α [16]. In this study, the hepatic expression of TNF- α increased abnormally in CCl_4 -administered animals. The SCE pretreatment inhibited the elevated TNF- α production following CCl_4 injection, and the low level of TNF- α might have played a protective role in this model by inducing hepatocyte proliferation and the release of mediators involved in tissue repair. The inhibitory capacity of SCE appears to be related to suppression of the production of TNF- α from Kupffer cells. Further studies may be needed to elucidate this phenomenon.

TNF- α also stimulates the release of cytokines from macrophages and induces phagocyte oxidative metabolism and nitric oxide production [17]. Nitric oxide can exacerbate

oxidative stress by reacting with ROS, particularly with the superoxide anion, and forming peroxynitrite [18]. However, the role of nitric oxide in liver damage remains controversial [5,19]. Although several studies have found that nitric oxide protects against CCl₄-induced liver injury using NOS knockout mice or a NOS inhibitor, certain evidence has addressed that excessive nitric oxide production by iNOS may lead to hepatic injury [6,18,20,21]. The current study confirmed significant increases in hepatic nitrite level and iNOS protein expression after CCl₄ administration. As the augment in hepatic nitrite content was dose-dependently attenuated by SCE, the extent of suppression of iNOS levels was evaluated by using both SCE (200 mg/kg) and a reference drug, silymarin (50 mg/kg). The observed repression of iNOS expression by SCE suggests that SCE inhibits iNOS protein secretion and/or enhances the degradation of these proteins. Accordingly, the possible mechanism of protection against CCl₄-induced hepatotoxicity appears to be, at least in part, due to the decreased hepatic nitric oxide production.

Previous studies have reported that the induction of cyclooxygenase in inflammatory response is the secondary effect of CCl₄-induced hepatotoxicity [1]. COX-2 is thought to be the predominant cyclooxygenase involved in the inflammatory responses [22]. There is considerable evidence suggesting that COX-2 is upregulated in several pathological conditions including cancer and autoimmune disease [23]. In other words, the reduction in excess nitric oxide generation as well as inhibition of iNOS and COX-2 protein expression may be associated with the prevention and treatment of the oxidative stress-induced inflammatory diseases. Our data showed an increase in the expression of COX-2 protein after CCl₄ administration. SCE attenuated this increase, suggesting a suppression of inflammatory responses.

Generally, CCl₄ is metabolized to highly reactive trichloromethyl-free radicals mainly by the CYP system in the endoplasmic reticulum of hepatic cells [24]. However, the trichloromethyl radical may bind either at the haem group of CYP or at the active site of the enzyme near the haem group, leading to the inactivation of CYP pathways [25]. In the present study, a significant decrease in hepatic CYP2E1 function was found in the rats treated with CCl₄ alone. In contrast, in rats pretreated with SCE, the hepatic CYP2E1 function was less suppressed after CCl₄ administration. This result proposes that SCE exerts a beneficial effect on hepatic

CYP2E1 restoration in this animal model. Therefore, it is possible that SCE restores the hepatic CYP2E1 function and leads to a rapid recovery from CCl₄-induced liver injury. On the other hand, it is also likely that the administration of SCE causes a reduction in CCl₄-induced hepatotoxicity that leads to an early recovery of the CYP2E1 function in the animal model, which would give rise to an elevation of the enzyme activity. With regard to this phenomenon, future work may be needed.

More recently, the water extract of *Sparassis crispa* has been shown to increase inhibitory kappa B-alpha and to reduce nuclear factor-kappa B (NF-κB) levels in activated mast cells, suggesting the possibility that *Sparassis crispa* could regulate the NF-κB activity in a variety of cell types [11]. However, the role of NF-κB in liver damage remains controversial. While it has been shown that NF-κB activation promotes cell survival in TNF-α-induced hepatotoxicity [26], studies have also indicated that NF-κB is an important regulator of numerous inflammatory mediators, several of which have been implicated in drug-induced hepatotoxicity [27,28]. On the basis of these observations, it is reasonable to speculate that *Sparassis crispa* may protect against hepatotoxicity by exerting anti-NF-κB actions. However, there is no evidence to support these assumptions in liver damages. Therefore, anti-NF-κB actions of *Sparassis crispa* in liver injury should be addressed in the future study.

In conclusion, our work demonstrates that SCE protects the liver from CCl₄-induced acute hepatic damage, which might be due to its ability to restore the CYP2E1 function and suppress the inflammatory responses, in combination with its capacity to reduce oxidative stress. The potential for using *Sparassis crispa* in experimental and practical applications should be examined further.

References

1. Basu S. Carbon tetrachloride-induced lipid peroxidation: eicosanoid formation and their regulation by antioxidant nutrients. *Toxicology*. 2003; 189:113-27.
2. Manibusan MK, Odin M, Eastmond DA. Postulated carbon tetrachloride mode of action: a review. *J Environ Sci Health C Environ Carcinog Ecotoxicol Rev*. 2007; 25:185-209.
3. Planaguma A, Claria J, Miquel R, Lopez-Parra M, Titos E, Masferrer JL, et al. The selective cyclooxygenase-2 inhibitor SC-236 reduces liver fibrosis by mechanisms involving non-parenchymal cell apoptosis and PPARgamma activation.

- FASEB J. 2005; 19:1120-2.
4. Weber LW, Boll M, Stampfl A. Hepatotoxicity and mechanism of action of haloalkanes: carbon tetrachloride as a toxicological model. *Crit Rev Toxicol.* 2003; 33:105-36.
 5. Hierholzer C, Harbrecht B, Menezes JM, Kane J, MacMicking J, Nathan CF, et al. Essential role of induced nitric oxide in the initiation of the inflammatory response after hemorrhagic shock. *J Exp Med.* 1998; 187:917-28.
 6. Zhu W, Fung PC. The roles played by crucial free radicals like lipid free radicals, nitric oxide, and enzymes NOS and NADPH in CCl₄-induced acute liver injury of mice. *Free Radic Biol Med.* 2000; 29:870-80.
 7. Al-Shabanah OA, Alam K, Nagi MN, Al-Rikabi AC, Al-Bekairi AM. Protective effect of aminoguanidine, a nitric oxide synthase inhibitor, against carbon tetrachloride induced hepatotoxicity in mice. *Life Sci.* 2000; 66:265-70.
 8. Gardner CR, Heck DE, Yang CS, Thomas PE, Zhang XJ, DeGeorge GL, et al. Role of nitric oxide in acetaminophen-induced hepatotoxicity in the rat. *Hepatology.* 1998; 27:748-54.
 9. Kimura T, Hashimoto M, Yamada M, Nishikawa Y. *Sparassis crispa* (Hanabiratake) ameliorates skin conditions in rats and humans. *Biosci Biotechnol Biochem.* 2013; 77:1961-3.
 10. Kimura T. Natural products and biological activity of the pharmacologically active cauliflower mushroom *Sparassis crispa*. *Biomed Res Int.* 2013; 2013:982317.
 11. Kim HH, Lee S, Singh TS, Choi JK, Shin TY, Kim SH. *Sparassis crispa* suppresses mast cell-mediated allergic inflammation: Role of calcium, mitogen-activated protein kinase and nuclear factor-kappaB. *Int J Mol Med.* 2012; 30: 344-50.
 12. Hida TH, Kawaminami H, Ishibashi K, Miura NN, Adachi Y, Ohno N. Oral administration of soluble beta-glucan preparation from the cauliflower mushroom, *Sparassis crispa* (Higher Basidiomycetes) modulated cytokine production in mice. *Int J Med Mushrooms.* 2013; 15:525-38.
 13. Batey RG, Salmond SJ, Bensoussan A. Complementary and alternative medicine in the treatment of chronic liver disease. *Curr Gastroenterol Rep.* 2005; 7:63-70.
 14. Recknagel RO, Glende EA, Jr., Dolak JA, Waller RL. Mechanisms of carbon tetrachloride toxicity. *Pharmacol Ther.* 1989; 43:139-54.
 15. Brucoleri A, Gallucci R, Germolec DR, Blackshear P, Simeonova P, Thurman RG, et al. Induction of early-immediate genes by tumor necrosis factor alpha contribute to liver repair following chemical-induced hepatotoxicity. *Hepatology.* 1997; 25:133-41.
 16. DeCicco LA, Rikans LE, Tutor CG, Hornbrook KR. Serum and liver concentrations of tumor necrosis factor alpha and interleukin-1beta following administration of carbon tetrachloride to male rats. *Toxicol Lett.* 1998; 98:115-21.
 17. Lowenstein CJ, Snyder SH. Nitric oxide, a novel biologic messenger. *Cell.* 1992; 70:705-7.
 18. Morio LA, Chiu H, Sprowles KA, Zhou P, Heck DE, Gordon MK, et al. Distinct roles of tumor necrosis factor-alpha and nitric oxide in acute liver injury induced by carbon tetrachloride in mice. *Toxicol Appl Pharmacol.* 2001; 172:44-51.
 19. Bohlinger I, Leist M, Barsig J, Uhlig S, Tiegs G, Wendel A. Interleukin-1 and nitric oxide protect against tumor necrosis factor alpha-induced liver injury through distinct pathways. *Hepatology.* 1995; 22:1829-37.
 20. Nadler EP, Dickinson EC, Beer-Stolz D, Alber SM, Watkins SC, Pratt DW, et al. Scavenging nitric oxide reduces hepatocellular injury after endotoxin challenge. *Am J Physiol Gastrointest Liver Physiol.* 2001; 281:G173-81.
 21. Inoue T, Kwon AH, Oda M, Kaibori M, Kamiyama Y, Nishizawa M, et al. Hypoxia and heat inhibit inducible nitric oxide synthase gene expression by different mechanisms in rat hepatocytes. *Hepatology.* 2000; 32:1037-44.
 22. Griswold DE, Adams JL. Constitutive cyclooxygenase (COX-1) and inducible cyclooxygenase (COX-2): rationale for selective inhibition and progress to date. *Med Res Rev.* 1996; 16:181-206.
 23. Chun KS, Surh YJ. Signal transduction pathways regulating cyclooxygenase-2 expression: potential molecular targets for chemoprevention. *Biochem Pharmacol.* 2004; 68:1089-100.
 24. Edwards MJ, Keller BJ, Kauffman FC, Thurman RG. The involvement of Kupffer cells in carbon tetrachloride toxicity. *Toxicol Appl Pharmacol.* 1993; 119:275-9.
 25. Fernandez G, Villarruel MC, de Toranzo EG, Castro JA. Covalent binding of carbon tetrachloride metabolites to the heme moiety of cytochrome P-450 and its degradation products. *Res Commun Chem Pathol Pharmacol.* 1982; 35:283-90.
 26. Papa S, Bubici C, Zazzeroni F, Franzoso G. Mechanisms of liver disease: cross-talk between the NF-kappaB and JNK pathways. *Biol Chem.* 2009; 390:965-76.
 27. Dambach DM, Durham SK, Laskin JD, Laskin DL. Distinct roles of NF-kappaB p50 in the regulation of acetaminophen-induced inflammatory mediator production and hepatotoxicity. *Toxicol Appl Pharmacol.* 2006; 211:157-65.
 28. Nakahira K, Takahashi T, Shimizu H, Maeshima K, Uehara K, Fujii H, et al. Protective role of heme oxygenase-1 induction in carbon tetrachloride-induced hepatotoxicity. *Biochem Pharmacol.* 2003; 66:1091-105.

사염화탄소로 유도된 흰쥐 간 손상에 대한 꽃송이버섯의 보호효과

연광해¹, 최윤호²

¹중국 연변대학교 기초의학원 해부학교실, ²전북대학교 의학전문대학원 해부학교실 및 의과학 연구소

간추림 : 꽃송이버섯은 다양한 약리활성을 지닌 식용버섯으로, 한국을 비롯해서 중국과 일본 등지에서 널리 재배된다. 이 논문은 꽃송이버섯의 추출물이 사염화탄소에 의해 유발된 간 독성을 억제할 수 있다는 가능성을 제시한다.

본 연구진은 0.5 mg/kg의 사염화탄소를 6주령 Sprague Dawley 흰쥐의 복강에 투여함으로써 간 독성 모델을 유도하였다. 그리고 꽃송이버섯이 간 독성에 미치는 효과를 확인하고자 이로부터 에탄올 추출물을 얻은 다음, 간 독성 모델을 유도하기 전에 복강으로 5일 연속 투여하였다.

사염화탄소 투여 후 16시간이 경과했을 때, 흰쥐의 혈장에서 aminotransferase와 TNF- α 의 농도 및 지질과산화의 정도가 현저히 증가하는 것을 관찰할 수 있었다. 아울러 간 내 항산화효소들의 활성은 감소하는 것이 확인되었다. 반면, 꽃송이버섯의 에탄올 추출물 100, 200 mg/kg을 상기 모델에 전 처리할 경우, 이러한 일련의 변화들이 용량 의존적으로 유의하게 억제되었다. 게다가 조직학적 소견 또한 꽃송이버섯 추출물이 사염화탄소에 의한 간 손상을 억제한다는 사실을 보여주었다. 더 나아가, 간 손상 모델에서 보이는 nitrite, inducible nitric oxide synthase (iNOS), cyclooxygenase-2 (COX-2)의 증가와 cytochrome p450 2E1 (CYP2E1)의 감소 양상은 꽃송이버섯의 에탄올 추출물에 의해 현저하게 억제되었다.

이상으로부터 꽃송이버섯은 사염화탄소에 의한 자극으로부터 간을 보호할 것으로 예상되는데, 이러한 효과는 꽃송이버섯이 산화적 스트레스를 줄일 뿐 아니라 iNOS와 COX-2에 의한 염증성 반응을 억제하고 CYP2E1의 기능을 회복시키기 때문으로 여겨진다.

찾아보기 낱말 : 꽃송이버섯, 사염화탄소, 간 독성