

# A Comparative Evaluation of Absorbable and Nonabsorbable Sutures for Open Repair of Achilles Tendon Rupture - A Pilot Study

Jeong Hyun Park<sup>1</sup>, Dong-Il Chun<sup>2</sup>, Sang Hyeon Lee<sup>3</sup>, Jae Ho Cho<sup>1,3</sup>

<sup>1</sup>*Department of Anatomy & Cell Biology, Graduate School of Medicine, Kangwon National University*

<sup>2</sup>*Department of Orthopedic Surgery, Soonchunhyang University Seoul Hospital*

<sup>3</sup>*Department of Orthopedic Surgery, Chuncheon Sacred Heart Hospital, Hallym University of Medicine*

(Received 18 May 2017, revised 16 June 2017, accepted 20 June 2017)

**Abstract** : This pilot study was performed to compare the functional and clinical results including complications after surgery in the open repair of Achilles tendon rupture with regard to the type of suture material. A consecutive series of twenty patients with acute Achilles tendon rupture who underwent open repair were enrolled in this pilot study. The patients were divided equally into 2 groups according to suture type. In the nonabsorbable suture group, No. 2 braided nonabsorbable polyethylene terephthalate sutures were used, and in the absorbable suture group, braided absorbable polyglactin sutures were used. The Korean version of the Foot and Ankle Outcome Score (FAOS) and complications were assessed to evaluate functional and clinical result. Mean total Foot and Ankle Outcome Score (FAOS) was 89.8 (range, 71.1~100) in the nonabsorbable suture group and 82.7 (range, 61.9~92.5) in the absorbable suture group ( $p=0.22$ ). All patients returned to their previous life activity. The absorbable suture group had fewer postoperative complications (10%) than the nonabsorbable suture group (20%), but there was no significant difference between two groups ( $p=0.45$ ). This pilot study showed that use of an absorbable suture for Achilles tendon repair had functional and clinical results comparable to those of the nonabsorbable suture. However, a use of an absorbable suture was associated with a lower incidence of complications than the use of nonabsorbable suture. Therefore, these results have to be confirmed in a randomized controlled cohort trial with larger population.

**Keywords** : Achilles tendon, Acute rupture, Polyethylene terephthalate, Polyglactin

## Introduction

Achilles tendon rupture occurs generally after sport-related traumas and usually in males aged 30~39 years [1]. Primary open repair of acute Achilles tendon rupture is a

common procedure and the results of this procedure are good but several complications such as; wound problems or infection, can be observed after surgery [2,3]. Also, there are many accepted suture materials on open repair surgery and selection of suture material depend on surgeon preference.

In Achilles tendon repairs, generally nonabsorbable sutures are used. Because the suture materials has to be strong enough to bear forces after tendon repair during healing and rehabilitation periods [4]. However, it has been reported that nonabsorbable suture material can cause

The author(s) agree to abide by the good publication practice guideline for medical journals.

The author(s) declare that there are no conflicts of interest.

Correspondence to : Jae Ho Cho (Department of Orthopedic Surgery, Chuncheon Sacred Heart Hospital, Hallym University of Medicine, 77, Sakju-ro, Chuncheon-si, Gangwon-do 24253, Korea)

E-mail : hohotoy@nate.com

**Table 1.** Demographic data on the two groups

	Group A	Group B
Number of cases	10	10
Mean age at surgery, years (range)	40.9 (30~48)	42.4 (21~59)
Male/Female	10/0	9/1
BMI, Kg/m <sup>2</sup> (range)	23.8 (22.2~26.1)	23.6 (21.7~26.4)

Group A = open repair with nonabsorbable suture

Group B = open repair with absorbable suture

BMI, Body Mass Index

complications such as granuloma, fibrosis, and triggering due to the stimulation of a suture [4,5]. On the other hand, absorbable suture materials had the highest holding capacities in animal models [6,7] and lowers the chance of foreign body reaction because it will be absorbed from the repair site [5].

According to our knowledge, no randomized study with regard to the type of suture material has evaluated functional and clinical results including complications after surgery in the open repair of Achilles tendon rupture. Thus, we compared the functional and clinical results of Achilles tendon open repairs using nonabsorbable versus absorbable sutures material as a pilot study (prospective, non-randomized, comparative study) before starting randomized controlled trial.

## Materials and Methods

A consecutive series of patients with acute Achilles tendon rupture who underwent open repair by a single surgeon between November 2015 and October 2016 were enrolled in this pilot study. The inclusion criteria were isolated traumatic Achilles tendon rupture had injured during sports activity with minimum follow-up of 6 months after surgery. Exclusion criteria were as follows: 1) open rupture or laceration, 2) direct blunt traumatic rupture, 3) delayed diagnosed rupture (defined by over one week after injury), 4) previous injury to the same tendon, 5) functional impairment on the contralateral side, 6) systemic disease such as diabetes mellitus or neurovascular disease, or immune-suppressed disease 7) severe tendinosis and degeneration that required adjunctive procedures like plantaris, flexor hallucis longus, or gastrocnemius augmentation.

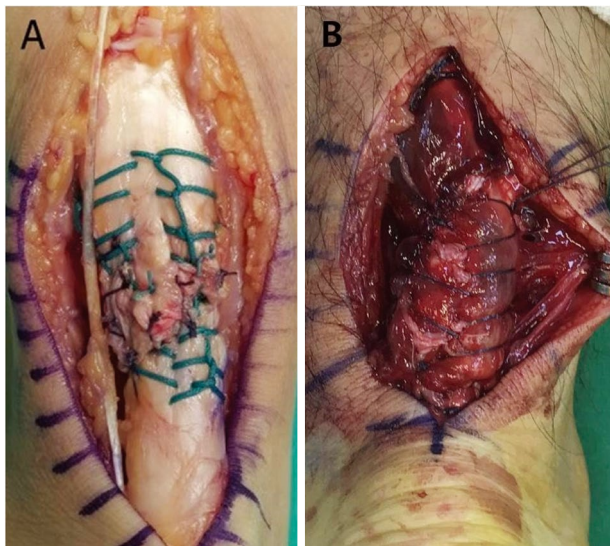
Consequently, the study included 20 ankles in 20 patients. In the first part of the study, patients exclusively

underwent Achilles tendon open repair with nonabsorbable braided polyethylene terephthalate suture “Ethibond<sup>®</sup> (ETHICON, Johnson & Johnson, Seoul, Korea)” (group A). Gradually, the move was made to Achilles tendon open repair with absorbable braided polyglactin suture “Vicryl<sup>®</sup> (ETHICON, Johnson & Johnson, Seoul, Korea)” (group B) to compare the functional and clinical results including complications after surgery between two different suture materials. The all patients in both groups were evaluated prospectively.

There were 10 patients in group A, 40.9 years (range, 30~48 years) and 10 patients in group B, with 42.4 years (range, 21~59 years). The mean follow-up period was 8.7 months (range, 6~12 months) in group A and 7.5 months (range, 6~12 months) in group B. The times from injury to operation were within two days (48 hours) in both groups. The two groups were homogeneous and there were no significant differences between groups regarding all the factors listed in Table 1.

The Korean version of the Foot and Ankle Outcome Score (FAOS) was obtained in all patients at the final follow-up to evaluate functional and clinical result [8]. The FAOS score contains 42 questions divided into five subscales: Pain, Symptoms, Activities of Daily living (ADLs), Sports and Recreational activities, and foot- and ankle-related quality of life (QoL). Patients answer the questions with respect to the symptomatic foot or ankle, such as: ‘Can you bend your foot or ankle fully?’, thus eliminating observer bias. Patients respond to each question on a scale from 0 to 4, and a total score between 0 (extreme symptoms) and 100 (no symptom) for each subscale is calculated according to a particular formula [8,9].

The complications after surgery were assessed the number of major surgical problems, including deep infection, rerupture, and suture reaction or foreign body reaction. For better objectivity in the follow-up, all evaluations were performed by a single medical doctor other than the



**Fig. 1.** We repaired Achilles tendon with two double-stranded Krackow technique using No. 2 Ethibond® (A) and No. 2 Vicryl® (B).

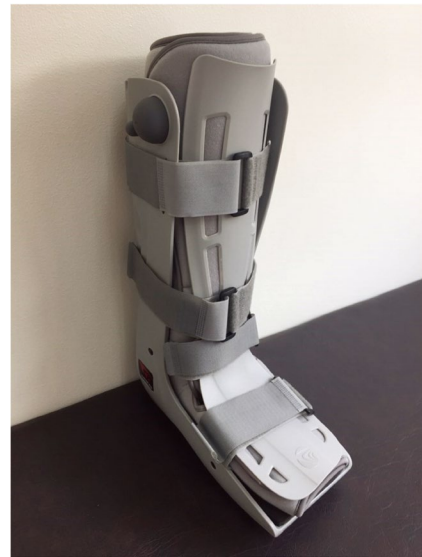surgeon in order to minimize observer bias.

### Surgical technique

The surgical technique of open repair of Achilles tendon rupture is described below. All procedures were performed with the patient in the prone position under regional or general anesthesia. All procedures were performed under the tourniquet (300 mmHg). A 6 cm longitudinal skin incision was made and paratenon & mesotenon were incised longitudinally and retracted to expose the ruptured tendon. In the group A, we used two double-stranded, Krackow sutures by No. 2 Ethibond® to repair the tendon ends, while the No. 2 Vicryl® was used in the group B (Fig. 1). And then supplemented tendon repaired site with interrupted 3-0 Vicryl® circumferential sutures in both groups. We sutured over the paratenon repair with 3-0 Vicryl® and closed the skin with interrupted fine nylon mattress sutures.

### Postoperative management

All 20 patients were managed postoperatively with short leg splint immobilization for two weeks and started the tolerable weight-bearing in a functional brace (Fig. 2) at two weeks' follow-up. During the period of maintenance with a splint, the ankle was immobilized in a non-weight-bearing position of natural plantar flexion. After the pati-



**Fig. 2.** Functional brace after the removal of splint.

ents had switched to the functional brace, tolerable weight-bearing and ankle joint motion from full plantar flexion to 20 degree dorsiflexion were permitted. The dorsiflexion angle of the ankle joint increased gradually per a week. At postoperative two weeks, the patients were allowed to perform full weightbearing as tolerated, using a functional brace. Additionally, the ankle joint was permitted to the full range of motion in addition to the plantar strengthening exercises and distraction exercise of the muscles around the Achilles tendon using a rubber band at postoperative four weeks. From postoperative more eight weeks, patients were allowed to walk with normal shoes. Three months after surgery, sports activity such as running was allowed.

### Statistical analysis

The Mann-Whitney *U* test was used to compare the functional and clinical result, while the chi-squared test was used to compare the number of surgical complications between groups. A *p* value < 0.05 was considered to indicate a significant difference. Statistical analysis was performed using SPSS version 18.0 software (SPSS, Chicago, IL, USA).

## Results

The functional and clinical result in both groups is

**Table 2.** The functional and clinical results between the two groups

Parameter	Group A	Group B	<i>p</i> value
Total FAOS	89.8 (13.5)	82.7 (11.2)	0.22
Pain	94.5 (10.8)	93.0 (8.7)	0.75
Symptoms	94.6 (11.6)	90.7 (8.3)	0.39
Activities of daily living	96.2 (8.6)	93.2 (9.5)	0.48
Sports and recreational activities	88.0 (16.0)	69.5 (34.8)	0.15
Foot- and ankle-related quality of life	75.6 (30.8)	66.9 (21.5)	0.47

Results are presented as mean (SD).

Group A = open repair with nonabsorbable suture

Group B = open repair with absorbable suture

**Table 3.** Distribution of postoperative complications in the two groups

Complications	Group A	Group B
Rerupture, n	0	0
Deep infection, n	1	1
Foreign body reaction, n	1	0
Total complications, n (%)	2 (20)	1 (10)

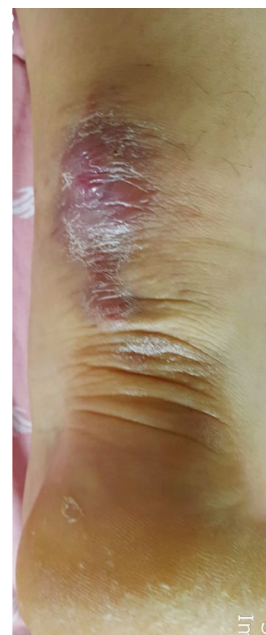Group A = open repair with nonabsorbable suture

Group B = open repair with absorbable suture

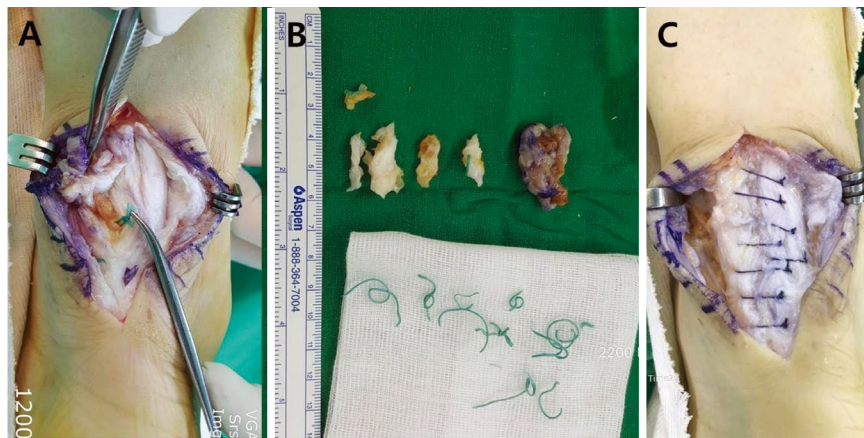n, number

described in Table 2. Mean total FAOS score was 89.8 (range, 71.1~100) in the nonabsorbable suture group and 82.7 (range, 61.9~92.5) in the absorbable suture group ( $p=0.22$ ). All patients returned to their previous life activity. The distribution of postoperative complications in the two groups is described in Table 3. The absorbable suture group had fewer postoperative complications (10%) than the nonabsorbable suture group (20%), but there was no significant difference between two groups ( $p=0.45$ ).

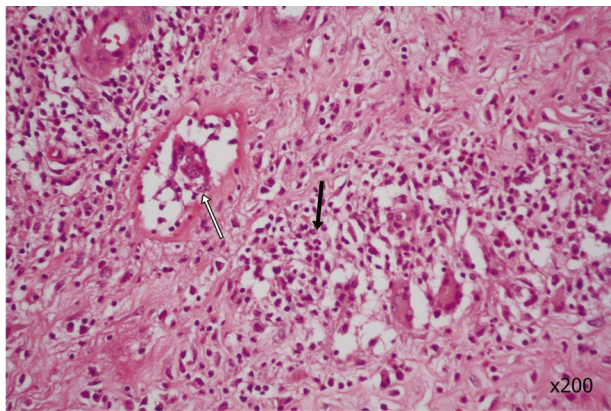
Deep infection occurred in 1 patient in the nonabsorbable suture group and absorbable suture group, respectively. All patients with deep infection were treated without any residual deficit by debridement and parenteral antibiotic therapy. Six months after surgery, one of the patients from the nonabsorbable suture group visited the outpatient clinic complaining pain and a gradually enlarging soft-tissue mass adjacent to the previous surgical scar of Achilles tendon repair. On physical examination, mass with morphological characteristic of a semi-mobile solid soft tissue (2 × 3 cm sized in diameter) was detected along the previous incision scar (Fig. 3). The infection parameters of laboratory data (C-reactive protein level, erythrocyte sedimentation rate and white blood-cellcount) were within normal limited. The patient was subsequently readmitted and underwent exploration and revision surgery.

**Fig. 3.** The granulomatous mass was detected along the previous incision scar.

Inside the masses, Ethibond® suture were detected and Ethibond® suture materials still remained on intact Achilles tendon after the granulomatous masses were excised (Fig. 4A). All suture material remnants were removed (Fig. 4B) and a defect of Achilles tendon was restored by tubular repair using absorbable sutures (Fig. 4C). Later histopathological analysis revealed typical findings of the foreign body reaction with macrophages, giant cells and eosinophilic infiltration as well as acute and chronic inflammatory cells surrounding the suture material (Fig. 5). There was no evidence of infection or malignancy. At final follow-up (six months later), the functional recovery of the Achilles tendon repair remained stable and there was no recurrence of the granuloma.



**Fig. 4.** Intraoperative findings in the patient with foreign body reaction. (A) Ethibond<sup>®</sup> suture materials still remained on intact Achilles tendon after the granulomatous masses were excised, (B) All suture material remnants were removed, (C) A defect of Achilles tendon was restored by tubular repair using absorbable sutures.



**Fig. 5.** Histologic finding shows giant cells (white arrow) as well as acute and chronic inflammatory cells (black arrow) surrounding the suture material. This finding means granulation tissue and foreign body reaction in Achilles tendon.

## Discussion

For tendon repair, most surgeons prefer to use non-absorbable suture depending on surgeon's preferences, because nonabsorbable sutures are believed to be stronger than absorbable sutures. However, nonabsorbable materials may cause stitch granuloma, fibrosis, triggering, and other complications because the body responds to the stimulation of the foreign suture material [10]. To overcome the aforementioned disadvantages of nonabsorbable suture materials, the use of absorbable suture materials for tendon repair have been considered in animal model [6,11,12]. Also, clinical results have been reported in flex-

or tenorrhaphy using absorbable suture materials [13].

In the English literatures, most authors have reported good results of open repair of acute Achilles tendon rupture. However, wound complications of this surgical treatment were reported as 7~13% [2]. Main risk factors of wound complications were considered with systemic or local predisposing factor such as age, gender, timing of surgery, body mass index, smoking, diabetes mellitus, and steroid use, but it was well documented that suture materials may cause wound problems [14,15]. Nevertheless, nonabsorbable suture materials for Achilles tendon repair have been used in the most articles. Thus, we think a study is necessary which investigates the surgical outcome of Achilles tendon repair with regard to the type of suture material.

For Achilles tendon repair, the tensile strength of suture, knot-holding ability, biocompatibility, manipulation, and complication rate should be considered. Meanwhile, nonabsorbable sutures are widely used due to the advantages of easy handling, good biocompatibility, and minimal loss of tensile strength after knotting but that may result in early suture reaction, deep infection and knots triggering from suture bulk and delayed foreign body reaction can be occurred at any time while nonabsorbable suture material is existed [4,5,16]. In contrast, the use of absorbable sutures may avoid problems associated with long term foreign body reaction from suture compared to nonabsorbable sutures. But, maintaining adequate tensile strength during the healing period remains a challenge to

surgeons due to suture's absorption into the body [10,12]. Thus, the strength of the absorbable suture could be an issue despite of advantage with regard to bioabsorbability.

In an experimental study of biomechanical properties of sutures, Najibi et al. [17] suggested unexpected finding about that No. 1 Vicryl<sup>®</sup> had equivalent strength (maximum load to failure, strain, and stiffness) to No. 2 Ethibond<sup>®</sup>. In addition, Yildirim et al. [7] reported that absorbable suture (polydioxanone) had the highest holding capacities and unabsorbable suture (polyethylene terephthalate) had the lowest in sheep model with comparison of the tendon-holding capacities about suture materials. In this study, we used the No. 2 Ethibond<sup>®</sup> and the No. 2 Vicryl<sup>®</sup> through the same surgical technique. In both group, all patients were managed postoperatively using same rehabilitation protocol. Also, age and body mass index (BMI) were not statistically different between two groups. As a result, the functional and clinical results using both suture materials were approximately equivalent. Therefore, we assumed that absorbable sutures could be used in repair of Achilles tendon.

The numerous studies regarding Achilles tendon repair have been reported complications of nonabsorbable sutures. Kim et al. [18] reported knots triggering from suture bulk after surgery using nonabsorbable suture (Ethibond<sup>®</sup>). Chronic deep sinus formation following Achilles tendon repair using nonabsorbable suture (Ethibond<sup>®</sup>) also has been reported [19]. In this report, authors urged surgeons to use routinely use an absorbable suture, which remains buried within the core when performing Achilles tendon repair. Some authors presented a case reports regarding to foreign body granulomatous reaction associated with nonabsorbable suture material (respectively, Ethibond<sup>®</sup> and Fibewire<sup>®</sup>) used in Achilles tendon repair [15,16]. In this pilot study, we experienced a case of granulomatous reaction from the nonabsorbable suture. Thus, selection of appropriate suture material important in avoiding potential complications and absorbable suture could be an option for Achilles tendon rupture because it has lower chance of suture reaction if the suture material is absorbed.

Our study is limited in that ours is a non-randomized pilot cohort study with a relatively small number of case and short term follow-up. Also, we only use one type of both nonabsorbable (Ethibond<sup>®</sup>) and absorbable sutures (Vicryl<sup>®</sup>). Nevertheless, this comparative study between two suture materials may be clinically important for the

choice for application of suture material. Ethibond<sup>®</sup> is clinically most common used material in Achilles tendon repair, because it has least tissue reaction with high tension strength compared to other nonabsorbable materials [5]. Also, Vicryl<sup>®</sup> has the property with equivalent strength and caliber compared to Ethibond<sup>®</sup> [17].

In this pilot study, we hypothesized that the absorbable suture would have functional and clinical results comparable to those of the nonabsorbable suture for Achilles tendon repair and use of an absorbable suture may be associated with a lower incidence of complications from suture reaction compared to the nonabsorbable suture. Accordingly, this pilot study showed that use of an absorbable suture for Achilles tendon repair had no difference on the surgical outcome both clinically and functionally, compared to the use of nonabsorbable suture. In addition, a use of an absorbable suture for Achilles tendon repair had fewer postoperative complications (10%) than the use of nonabsorbable suture group, although there was no significant difference statistically. Therefore, we suggest that these results have to be confirmed in a randomized controlled cohort trial with larger patient.

## REFERENCES

1. Leppilahti J, Puranen J, Orava S. Incidence of Achilles tendon rupture. *Acta Orthop Scand*. 1996; 67:277-9.
2. Dalton GP, Wapner KL, Hecht PJ. Complications of achilles and posterior tibial tendon surgeries. *Clin Orthop Relat Res*. 2001; 391:133-9.
3. Pajala A, Kangas J, Ohtonen P, Leppilahti J. Rupture and deep infection following treatment of total Achilles tendon rupture. *J Bone Joint Surg Am*. 2002; 84-A:2016-21.
4. Esenyel CZ, Demirhan M, Kilicoglu O, Adanir O, Bilgic B, Guzel O, et al. Evaluation of soft tissue reactions to three nonabsorbable suture materials in a rabbit model. *Acta Orthop Traumatol Turc*. 2009; 43:366-72.
5. Carr BJ, Ochoa L, Rankin D, Owens BD. Biologic response to orthopedic sutures: a histologic study in a rabbit model. *Orthopedics*. 2009; 32:828.
6. Wada A, Kubota H, Akiyama T, Hatanaka H, Miura H, Iwamoto Y. Effect of absorbable polydioxanone flexor tendon repair and restricted active mobilization in a canine model. *J Hand Surg Am*. 2001; 26:398-406.
7. Yildirim Y, Saygi B, Kara H, Cabukoglu C, Esemeli T. Tendon holding capacities of the suture materials used in

- repairing Achilles tendon rupture. *Acta Orthop Traumatol Turc.* 2006; 40:164-8.
8. Lee KM, Chung CY, Kwon SS, Sung KH, Lee SY, Won SH, et al. Transcultural adaptation and testing psychometric properties of the Korean version of the Foot and Ankle Outcome Score (FAOS). *Clin Rheumatol.* 2013; 32:1443-50.
  9. Roos EM, Brandsson S, Karlsson J. Validation of the foot and ankle outcome score for ankle ligament reconstruction. *Foot Ankle Int.* 2001; 22:788-94.
  10. Trail IA, Powell ES, Noble J. An evaluation of suture materials used in tendon surgery. *J Hand Surg Br.* 1989; 14:422-7.
  11. Bourne RB, Bitar H, Andrae PR, Martin LM, Finlay JB, Marquis F. In-vivo comparison of four absorbable sutures: Vicryl, Dexon Plus, Maxon and PDS. *Can J Surg.* 1988; 31:43-5.
  12. O'Broin ES, Earley MJ, Smyth H, Hooper AC. Absorbable sutures in tendon repair. A comparison of PDS with prolene in rabbit tendon repair. *J Hand Surg Br.* 1995; 20:505-8.
  13. Kang HJ, Lee DC, Kim JS, Ki SH, Roh SY, Yang JW. Flexor tenorrhaphy using absorbable suture materials. *Arch Plast Surg.* 2012; 39:397-403.
  14. Bruggeman NB, Turner NS, Dahm DL, Voll AE, Hoskin TL, Jacofsky DJ, et al. Wound complications after open Achilles tendon repair: an analysis of risk factors. *Clin Orthop Relat Res.* 2004; 427:63-6.
  15. Ollivere BJ, Bosman HA, Bearcroft PW, Robinson AH. Foreign body granulomatous reaction associated with polyethylene 'Fiberwire((R))' suture material used in Achilles tendon repair. *Foot Ankle Surg.* 2014; 20:e27-9.
  16. Kara A, Celik H, Seker A, Uysal MA, Uzun M, Malkoc M. Granuloma formation secondary to Achilles tendon repair with nonabsorbable suture. *Int J Surg Case Rep.* 2014; 5:720-2.
  17. Najibi S, Banglmeier R, Matta J, Tannast M. Material properties of common suture materials in orthopaedic surgery. *Iowa Orthop J.* 2010; 30:84-8.
  18. Kim DY, Kim SB, Heo YM, Lee JB, Lim JW, Oh HT. Surgical Treatment of the Ruptured Achilles Tendon: A Comparative Study between Percutaneous and Open Repair. *J Korean Foot Ankle Soc.* 2011; 15:79-85.
  19. Ahluwalia R, Zourelidis C, Guo S, Dega R. Chronic sinus formation using non absorbable braided suture following open repair of Achilles tendon. *Foot Ankle Surg.* 2013; 19:e7-9.

# 발꿈치힘줄 파열의 수술적 치료 시 사용한 비흡수성 봉합사와 흡수성 봉합사의 임상적 결과 비교: 선행 연구

박정현<sup>1</sup>, 천동일<sup>2</sup>, 이상현<sup>3</sup>, 조재호<sup>1,3</sup>

<sup>1</sup>강원대학교 의과대학 해부학교실, <sup>2</sup>순천향대학교 서울병원 정형외과학교실

<sup>3</sup>한림대학교 의과대학 춘천성심병원 정형외과학교실

**간추림** : 이 선행 연구는 발꿈치힘줄의 급성 파열에서 수술적 치료 시에 봉합사의 종류에 따라 임상적 및 기능적 평가 결과를 비교하기 위해 수행하였다. 연구에는 발꿈치힘줄의 급성 파열로 개방적 힘줄 봉합술을 시행하였던 20명의 환자를 대상으로 하였다. 환자는 수술적 치료 시에 사용하였던 봉합사의 종류에 따라 두 군으로 구분하였다. 10명에서는 비흡수성 봉합사인 Ethibond<sup>®</sup>를 이용하여 건 봉합술을 시행하였고, 다른 10명에서는 흡수성 봉합사인 Vicryl<sup>®</sup>을 이용하여 건 봉합술을 시행하였다. 수술 후 마지막 추시 관찰에서 Korean version of the Foot and Ankle Outcome Score (FAOS)를 이용하여 임상적 및 기능적 결과를 평가하였고, 수술 후 합병증에 대해 조사하였다. 비흡수성 봉합사를 사용한 군에서는 평균 FAOS 점수가 89.8점, 흡수성 봉합사를 사용한 군에서는 82.7점으로 두 군 간에는 유의한 차이를 보이지 않았다. 수술 후 합병증은 비흡수성 봉합사 군에서 2례(20%), 흡수성 봉합사 군에서 1례(10%)로 차이를 보였지만, 통계적으로 유의하지는 않았다. 이 선행 연구의 결과로 볼 때, 발꿈치힘줄의 수술적 치료 시에 비흡수성 봉합사와 흡수성 봉합사를 사용할 경우 유사한 임상적 및 기능적 결과를 보였다. 하지만, 흡수성 봉합사를 사용하는 경우 비흡수성 봉합사를 사용하는 경우에 비해 수술 후 합병증의 발생은 낮을 것으로 추정된다. 따라서, 이러한 선행 연구의 결과를 입증하기 위해 보다 많은 환자들을 통한 무작위 대조 연구가 필요할 것으로 사료된다.

**찾아보기 낱말** : 발꿈치힘줄, 급성 파열, 봉합사