

The Tendinous Slip of the Flexor Digitorum Longus for the Great Toe: An Anatomic Variation

Ju-Young Lee¹, Mi-Sun Hur²

¹Department of Biomedical Engineering, Catholic Kwandong University

²Department of Anatomy, College of Medicine, Catholic Kwandong University

(Received 2 March 2017, revised 16 March 2017, accepted 20 March 2017)

Abstract : This report describes a variation of the tendinous slip of the flexor digitorum longus (FDL) for the great toe. In addition, compositions of the long flexor tendons for all five toes were examined. The tendons of the FDL in the foot were investigated in 66 specimens of embalmed Korean adult cadavers. The tendons of the flexor hallucis longus (FHL) and the FDL with the lumbrical muscles were cut at the calcaneus and the metatarsophalangeal joints and were removed *en bloc* specifically to observe the FDL and the FHL tendons of the great toe. The tendinous slip of the FDL for the great toe was found bilaterally in the foot of a 52-year-old male. Its prevalence was two of 66 specimens (3.0%). The tendinous slip of the FDL for the great toe passed forward the great toe, and it constituted the superficial portion of the long flexor tendon for the great toe. The tendon of the FHL passed forward to constitute the deep portion of the long flexor tendon for the great toe. Thus, both the tendinous slip of the FDL and the tendon of the FHL composed the long flexor tendon for the great toe. The tendinous slip of the FDL and the tendon of the FHL for the great toe were similar in thickness; thus, each tendinous slip of the FDL and the tendon of the FHL were approximately one-half of the long flexor tendon for the great toe in thickness.

The present study demonstrated an anatomical variation of the interconnection between the FHL and the FDL tendons, which will be useful for various surgeries and biomechanical research.

Keywords : Flexor digitorum longus, Flexor hallucis longus, Great toe, Tendinous slip, Tendon

Introduction

There have been several reports regarding various connections between the flexor digitorum longus (FDL) and the flexor hallucis longus (FHL) tendons in the foot [1-4].

*This research was supported by Basic Science Research Program through the National Research Foundation of Korea (NRF) funded by the Ministry of Education (201605150001). This work was supported by research fund of Catholic Kwandong University (CKURF-201604370001).

The author(s) agree to abide by the good publication practice guideline for medical journals.

The author(s) declare that there are no conflicts of interest.

Correspondence to : Mi-Sun Hur (Room 503, Department of Anatomy, Catholic Kwandong University College of Medicine, Gangneung, Korea)

E-mail : mshur@cku.ac.kr

The region of cross-connection between the FDL and FHL tendons has been termed the “master knot” [5]. The different anatomical variations of the connection between the FDL and FHL tendons may affect movements of the toes and outcome of surgical intervention in this area.

Tendon transfer of the FHL and FDL is widely used as a treatment for Achilles tendinitis, Achilles tendinosis, rupture of the Achilles tendon, and dysfunction of the tibialis posterior muscle [6-11]. When a connection between the FHL and the FDL tendons is present, it can preserve distal function if one of the tendons is used for transfer. In addition, it serves as a “natural” tenodesis, avoiding the

need to surgically perform one [2].

The FDL and the FHL are the extrinsic toe flexors [12]. The action of the FDL is to flex the distal phalanges of the four lateral toes. The FDL tendon passes forward as four separate tendons, one each for the second to fifth toes [12,13]. The FHL is a primary flexor of the great toe, and it runs forward to an insertion on the distal phalanx of the great toe [13]. The FDL and the FHL become very active during toe-off and tip-toe movements. When the foot is off the ground, both muscles flex the phalanges of the toes, acting primarily on the distal phalanges [12]. In addition, the FDL and the FHL play an important role in stabilizing the longitudinal arch and supporting high fore-foot loads during the stance phase of gait [14].

This report describes a variation of the tendinous slip of the FDL for the great toe. In addition, compositions of the long flexor tendons for all five toes were examined, thereby providing data that would be useful for the tendon transfer for surgical treatments and biomechanical research.

Materials and Methods

The tendons of the FDL in the foot were investigated in 66 specimens of embalmed Korean adult cadavers (19 males, 14 females; mean age 65.8 years, age range 33~103 years). The skin and subcutaneous tissue of the sole were removed. The plantar aponeurosis and the tendons of the flexor digitorum brevis muscle were cut at the metatarsophalangeal joints and were reflected inferiorly to expose the FHL and the FDL tendons. A detailed dissection was performed by focusing on the FDL and the FHL tendons of the great toe. The tendons of the FHL and the FDL with the lumbrical muscles were cut at the calcaneus and the metatarsophalangeal joints and were removed *en bloc* specifically to observe the FDL and the FHL tendons of the great toe.

Results

The tendinous slip of the FDL for the great toe was found bilaterally in the feet of a 52-year-old male (Fig. 1). Its prevalence was two of 66 specimens (3.0%). The dividing pattern and course of the tendinous slip of the FDL

were similar on the left and right sides of this cadaver. The tendinous slip of the FDL for the great toe was divided from the tendon of the FDL before its division into four tendons for the second to fifth toes. The tendinous slip of the FDL for the great toe passed forward the great toe, and it constituted the superficial portion of the long flexor tendon for the great toe. The tendon of the FHL passed forward to constitute the deep portion of the long flexor tendon for the great toe. Thus, both the tendinous slip of the FDL and the tendon of the FHL composed the long flexor tendon for the great toe. The tendinous slip of the FDL and the tendon of the FHL for the great toe were similar in thickness; thus, each tendinous slip of the FDL and the tendon of the FHL were approximately one-half of the long flexor tendon for the great toe in thickness.

The tendinous slip of the FHL was observed on the left and right sides (52-year-old male). It was divided from the tendon of the FHL, and it was similar in thickness to the tendon of the FHL for the great toe. The site where the tendinous slip of the FHL was divided from the FHL tendon was similar to that where the tendinous slip of the FDL for the great toe was divided from the FDL tendon. The tendinous slip of the FHL extended to divide into two separate slips to constitute the deep portions of the long flexor tendons for the second and third toes. Thus, the tendon and tendinous slip of the FHL and the tendon and tendinous slip of the FDL composed the long flexor tendon for the great toe to the third toe.

In this cadaver, the tendon of the quadratus plantae muscle (QP) constituted the deep portion of the long flexor tendon for the fourth toe, while the tendon of the FDL constituted the superficial portion of the long flexor tendon for the fourth toe. Thus, the tendons of the FDL and the QP composed the long flexor tendon for the fourth toes. Therefore, only the tendon of FDL contributed to the long flexor tendon of fifth toe.

Discussion

The FHL and the FDL tendons were often connected in the foot, and they comprised the long flexor tendons for the toes. The tendinous slip of the FDL for the great toe is one of the anatomic variations of the interconnection between the FHL and the FDL tendons. In lower mammals, there is much variation in the toes to which the tibial and

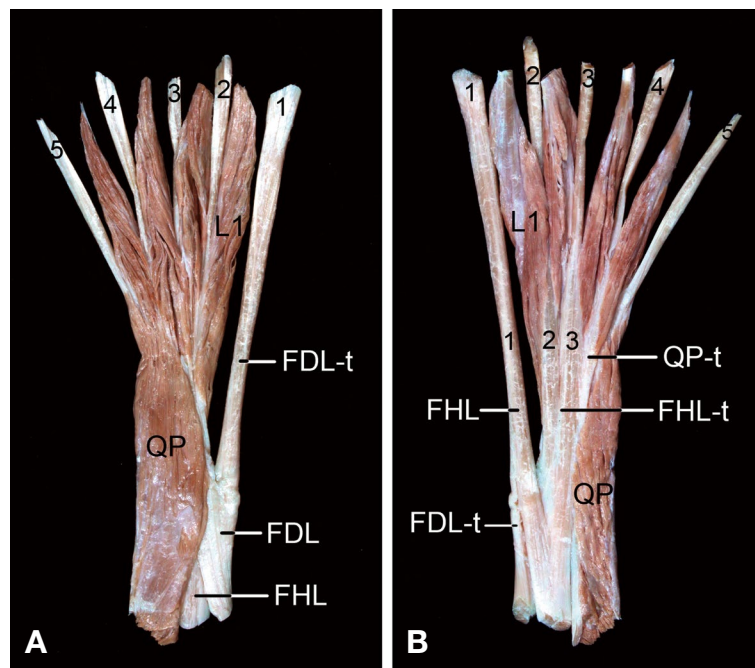


Fig. 1. The tendinous slip of the flexor digitorum longus (FDL) for the great toe. A: The tendinous slip of the FDL (FDL-t) passed forward the great toe in the plantar view of the tendon of the FDL (right foot). B: The tendon of the flexor hallucis longus (FHL) passed forward to constitute the deep portion of the long flexor tendon for the great toe. The tendinous slip of the FDL for the great toe constituted the superficial portion of the long flexor tendon for the great toe. Both the tendinous slip of the FDL (FDL-t) and the tendon of the FHL composed the long flexor tendon for the great toe in the dorsal view of the tendon of the FDL (right foot). FHL-t, tendinous slip of the FHL; L1, first lumbrical muscle; QP, quadratus plantae muscle; QP-t, tendon of quadratus plantae muscle; 1, first long flexor tendon; 2, second long flexor tendon; 3, third long flexor tendon; 4, fourth long flexor tendon; 5, fifth long flexor tendon.

fibular flexors are distributed [15]. These connections of the tendons in the foot are thought to make the structures of the foot move together and link the movements for weight bearing, balance, and locomotion.

The interconnection between the FHL and the FDL tendons have been usually classified into four types [1-4,16]; Type I, tendinous slip from the FHL to FDL tendon in 41.7~97%; Type II, tendinous slip from the FHL to FDL and an additional slip from the FDL to FHL (crossed connection) in 1~41.7%; Type III, tendinous slip from the FDL to FHL in 0~30%; and Type IV, no connection between the FHL and FDL in 0~16.7%. The case of the present study corresponded to type II. Its prevalence was 3% in the present study; thus, it was similar to studies of Plasss et al. (2013) [16] and Edama et al. (2016) [4].

The tendinous slip of the FDL for the great toe was not smaller than the tendons of the FDL for the other toes on this cadaver. Thus, the action of the tendinous slip of the FDL for the great toe likely will not be weaker than those of the tendons of the FDL for the other toes. The inter-

phalangeal joint of the great toe is flexed by the FHL [13]. If the FHL tendon is transected at the region proximal to its connection with the tendinous slip of the FDL for the great toe, the interphalangeal joint of the great toe can still flex through the pull of the FDL.

In this cadaver, the FDL likely flexes all five toes. The tendinous slip of the FHL extended and divided into the second and the third toes, thus the FHL and its tendinous slips may flex the first to third toes. Therefore, it is thought that both the FDL and the FHL can flex all the joints of the great toe to the third toes in this cadaver.

In the previous studies, the tendinous slip of the FHL constituted the long flexor tendon only for the second toe in 8~41.2%; it developed into two slips to the tendons for the second and third toes in 47.1~64% and into three slips to the tendons for the second, third, and fourth toes in 7~28% [3,4,16-18]. Thus, it seems that the tendinous slip of the FHL is not a rare variation. The tendinous slip of the FHL may distribute the load of the great toe to the second toe and to the third or fourth toe in the forefoot, especially

during toe-off, increasing the weight-bearing area in the forefoot [18]. In addition, a connection between the FHL and FDL tendons might contribute to residual function of the lesser toes after transfer of the FHL tendon [4].

In the propulsive phase of running, jumping or walking, the FDL pulls the toes firmly downwards towards the ground to achieve the maximum grip and thrust during the toe-off phase. The FHL is of great importance, as it produces much of the final thrust from the foot during walking. In this cadaver, the FDL can flex the great toe with the other toes to grip the ground, and it also likely assists in producing the final thrust with the FHL [19].

Muscles play an important role in maintaining the medial longitudinal arch. The FHL acts as a bowstring. The FDL, abductor hallucis and the medial half of the flexor digitorum brevis also contribute but to a lesser extent [12]. Thus, the tendinous slip of the FDL for the great toe can also help to support the medial longitudinal arch of the foot.

The present study demonstrated an anatomical variation of the interconnection between the FHL and the FDL tendons, which will be useful for various surgeries and biomechanical research.

Conflict of interest

The authors declare that they have no conflict of interest.

REFERENCES

- O'Sullivan E, Carare-Nnadi R, Greenslade J, Bowyer G. Clinical significance of variations in the interconnections between flexor digitorum longus and flexor hallucis longus in the region of the knot of Henry. *Clin Anat.* 2005; 18:121-5.
- LaRue BG, Anctil EP. Distal anatomical relationship of the flexor hallucis longus and flexor digitorum longus tendons. *Foot Ankle Int.* 2006; 27:528-32.
- Mao H, Shi Z, Wapner KL, Dong W, Yin W, Xu D. Anatomical study for flexor hallucis longus tendon transfer in treatment of Achilles tendinopathy. *Surg Radiol Anat.* 2015; 37:639-47.
- Edama M, Kubo M, Onishi H, Takabayashi T, Yokoyama E, Inai T, et al. Anatomical study of toe flexion by flexor hallucis longus. *Ann Anat.* 2016; 204:80-5.
- Henry AK. *Extensile exposure.* 3rd ed. Edinburgh: Churchill Livingstone; 1995.
- Monroe MT, Dixon DJ, Beals TC, Pomeroy G, Crowley DL, Manoli A. Plantarflexion torque following reconstruction of Achilles tendinosis or rupture with flexor hallucis longus augmentation. *Foot Ankle Int.* 2000; 21:324-9.
- Martin RL, Manning CM, Carcia CR, Conti SF. An outcome study of chronic Achilles tendinosis after excision of the Achilles tendon and flexor hallucis longus tendon transfer. *Foot Ankle Int.* 2005; 26:691-7.
- DiPaola M, Raikin SM. Tendon transfers and realignment osteotomies for treatment of stage II posterior tibial tendon dysfunction. *Foot Ankle Clin.* 2007; 12:273-85.
- Wegrzyn J, Luciani JF, Philippot R, Brunet-Guedj E, Moyon B, Besse JL. Chronic Achilles tendon rupture reconstruction using a modified flexor hallucis longus transfer. *Int Orthop.* 2010; 34:1187-92.
- Schon LC, Shores JL, Faro FD, Vora AM, Camire LM, Guyton GP. Flexor hallucis longus tendon transfer in treatment of Achilles tendinosis. *J Bone Joint Surg Am.* 2013; 2: 95:54-60.
- McAlister JE, DeMill SL, So E, Hyer CF. Surgical planning for flexor digitorum longus tendon transfers: an anatomic study. *J Foot Ankle Surg.* 2017; 56:47-49.
- Standring S. *Gray's Anatomy.* 41st ed. New York: Elsevier/Churchill Livingstone; 2016.
- Jenkins DB. *Hollinshead's Functional Anatomy of the Limbs and Back.* 9th ed. Philadelphia: Saunders; 2009.
- Hofmann CL, Okita N, Sharkey NA. *Clin Biomech (Bristol, Avon).* Experimental evidence supporting isometric functioning of the extrinsic toe flexors during gait. 2013; 28:686-91.
- Morris H. *Morris' Human Anatomy: A Complete Systematic Treatise.* 10th ed. Philadelphia: Blakiston Co; 1947.
- Plaass C, Abuharbid G, Waizy H, Ochs M, Stukenborg-Colsman C, Schmiegl A. Anatomical variations of the flexor hallucis longus and flexor digitorum longus in the chiasma plantare. *Foot Ankle Int.* 2013; 34:1580-7.
- Wapner KL, Hecht PJ, Shea JR, Allardyce TJ. Anatomy of second muscular layer of the foot: considerations for tendon selection in transfer for Achilles and posterior tibial tendon reconstruction. *Foot Ankle Int.* 1994; 15:420-3.
- Hur MS, Kim JH, Woo JS, Choi BY, Kim HJ, Lee KS. An anatomic study of the quadratus plantae in relation to tendinous slips of the flexor hallucis longus for gait analysis. *Clin Anat.* 2011; 24:768-73.
- Palastanga N, Soames R. *Anatomy and human movement: Structure and function.* 6th ed. New York: Elsevier/Churchill Livingstone, 2012.

엄지발가락으로 가는 긴발가락굽힘근 힘줄: 해부학적 변이 연구

이주영¹, 허미선²

¹가톨릭관동대학교 의료공학과, ²가톨릭관동대학교 의과대학 해부학교실

간추림 : 이 연구는 엄지발가락으로 가는 긴발가락굽힘근 힘줄 변이를 관찰하여 기술하였고, 또한 다섯 발가락으로 가는 긴굽힘근 힘줄의 구성을 확인하였다. 재료는 한국 성인 시신 발 66쪽을 사용하였다. 발꿈치뼈와 발허리발가락관절에서 긴엄지굽힘근 힘줄과 긴발가락굽힘근 힘줄들을 벌레근과 함께 자른 후, 특히 엄지발가락으로 가는 긴엄지굽힘근 힘줄과 긴발가락굽힘근의 힘줄들을 관찰하였다. 발에서 긴발가락굽힘근 힘줄로부터 힘줄가닥이 갈라져 나와 엄지발가락으로 들어가는 경우가 52세 남성 시신의 양쪽 발에서 관찰되었다. 이 경우는 66쪽의 발에서 2예 (3.0%)의 빈도로 나타났다. 엄지발가락으로 가는 긴발가락굽힘근 힘줄가닥은 엄지발가락으로 가는 긴굽힘근 힘줄의 얇은 부분을 구성하였고, 긴엄지굽힘근 힘줄은 엄지발가락으로 가는 긴굽힘근 힘줄의 깊은 부분을 구성하였다. 이 연구는 긴엄지굽힘근 힘줄과 긴발가락굽힘근 힘줄 사이 연결의 해부학적 변이를 나타내었으며, 이 결과는 다양한 수술과 생체역학 연구에 유용할 것으로 생각된다.

찾아보기 낱말 : 긴발가락굽힘근, 긴엄지굽힘근, 엄지발가락, 힘줄가닥, 힘줄