

An Anatomical Description of the Anomalous Nasi Muscle

Ju-Young Lee¹, Mi-Sun Hur²

¹*Department of Biomedical Engineering, Catholic Kwandong University*

²*Department of Anatomy, Institute for Clinical and Translational Research, Catholic Kwandong University College of Medicine*

(Received 23 July 2017, revised 7 September 2017, accepted 8 September 2017)

Abstract : The aim of the present study was to describe a variation of the anomalous nasi muscle in relation to the surrounding structures. The anomalous nasi muscle was found in the left face of a 40-year-old female during dissection. The anomalous nasi muscle lay on the lateral side of the nose, and it originated from the frontal process of the maxilla. The origin of the anomalous nasi muscle was located medial to the middle part of the levator labii superioris alaeque nasi muscle. It ascended superomedially to blend with the deep and lateral fibers of the superficial layer of the procerus below the level of the medial palpebral ligament. The length and width of the anomalous nasi muscle were 11.9 mm and 2.8 mm, respectively. This report demonstrated a variation of the anomalous nasi muscle, which will be helpful for understating the nasal movements and nasal wrinkles.

Keywords : Anomalous nasi muscle, Nose, Procerus, Wrinkles, Nasal movements

Introduction

The muscles of the nose vary considerably in extent of development, and one or more may be absent. Some authors explained differently about the muscles [1]. And some nasal muscles extended to the adjacent structures, possibly resulting in connected movements [2,3].

Anomalous, inconstant, nasal muscles include anomalous nasi, attached to the frontal process of the maxilla, procerus, transverse part of nasalis and the upper lateral cartilage, and compressor narium minor, which passes between the anterior part of the lower lateral cartilage

and the skin near the margins of the nares. The existence of a small levator septi nasi has been questioned [4]. The anomalous nasi muscle is not always present [5], and there were few reports about its anatomy such as frequency and morphological patterns. And Vaiman et al. (2003) [6] and Baker (2011) [7] showed that the anomalous nasi muscle occupied the whole area between the transverse part of the nasalis and the levator labii superioris alaeque nasi muscle (LLSAN).

The aim of the present study was to describe a variation of the anomalous nasi muscle in relation to the surrounding structures, which may be helpful for understanding the nasal movements and designing botulinum toxin type A (BTX-A) therapies.

Case Report

The anomalous nasi muscle was found in the left face of a 40-year-old female during dissection (Fig. 1). The

*This research was supported by Basic Science Research Program through the National Research Foundation of Korea (NRF) funded by the Ministry of Education (NRF-2016R1D1A1B03930402).

*This work was supported by research fund of Catholic Kwandong University (CKURF- 201601840001).

The author(s) agree to abide by the good publication practice guideline for medical journals.

The author(s) declare that there are no conflicts of interest.

Correspondence to : Mi-Sun Hur (Room 503, Department of Anatomy, Catholic Kwandong University College of Medicine, Gangneung, Korea)

E-mail : mshur@cku.ac.kr

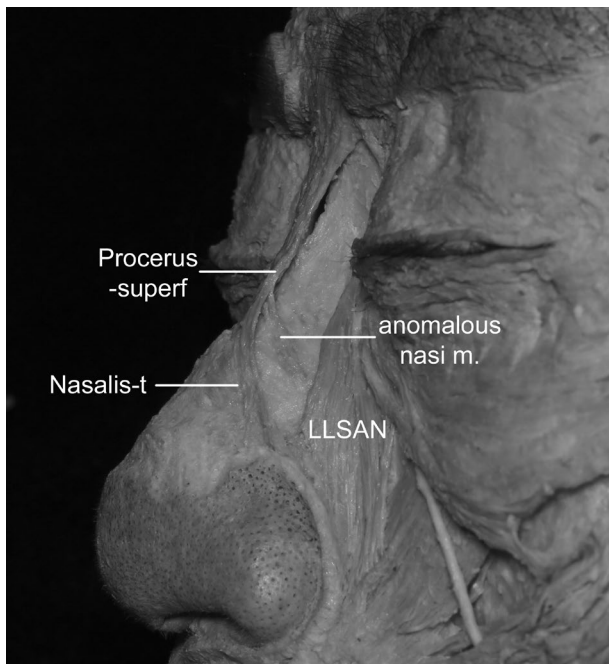


Fig. 1. A photograph showing a variation of the anomalous nasi muscle (anomalous nasi m.). The anomalous nasi m. originated from the frontal process of the maxilla, and ascended superomedially to blend with the deep and lateral fibers of the superficial layer of the procerus (Procerus-superf) below the level of medial palpebral ligament. Nasalis-t, transverse part of the nasalis; LLSAN, levator labii superioris alaeque nasi muscle.

anomalous nasi muscle lay on the lateral side of the nose, and it originated from the frontal process of the maxilla. The origin of the anomalous nasi muscle was located medial to the middle part of the LLSAN. It ascended superomedially to blend with the procerus below the level of the medial palpebral ligament. The anomalous nasi muscle blended with the deep and lateral fibers of the superficial layer of the procerus. The length and width of the anomalous nasi muscle were 11.9 mm and 2.8 mm, respectively.

Discussion

It has been described that the anomalous nasi muscle has an origin from the frontal process of the maxilla, and it inserts into the nasal bone, the upper lateral cartilage, the procerus, and the transverse part of the nasalis [5,7]. And Morris (1947) [1] stated that the anomalous nasi muscle is a longitudinal muscle strip occasionally found running from the frontal process to the body of the maxilla

near the lateral margin of the nasal aperture. Vaiman et al. (2003) [3] described that the anomalous nasi muscle run beneath transverse part of nasalis. But in the present study it was located above the transverse part of the nasalis.

In literature, the anomalous nasi muscle has been explained that it is closely related with the nasal movements and respiration. Baker (2011) [7] and Stucker et al. (2009) [8] described that the anomalous nasi muscle is an elevator of the nose with the procerus and the LLSAN. And Vaiman et al., 2003) [6] described that during forced nasal inspiration in subjects with extremely effective coordination of nasal muscles, the transverse part of nasalis, anomalous nasi, alar nasalis, and dilator naris anterior were active.

In the present study, the anomalous nasi muscle lay on the frontal process of the maxilla and the nasal bone and blended with the superficial layer of the procerus. Hur (2017) [3] described that the superficial layer of the procerus extended to the transverse part of the nasalis and the nasal ala. Thus contraction of the anomalous nasi muscle might assist in pulling the glabellar region inferolaterally, especially when the superficial layer of the procerus was pulled inferiorly due to contraction of the transverse part of the nasalis. In reversed action resulting from the reversal of the origin and insertion of the anomalous nasi muscle, it might pull the frontal process of the maxilla when the superficial layer of procerus elevates and shortens the nose via its extended fibers to the nose. However, the anomalous nasi muscle in the present study had thin and small muscle fibers, attaching to the frontal process of the maxilla. Thus it seems to have few functions for the nasal movements and respiration.

Contraction of the anomalous nasi muscle might produce nasal wrinkles on the lateral nasal wall between the transverse part of the nasalis and the LLSAN. And connection of the anomalous nasi muscle with the superficial layer of the procerus may affect patterns of the nasal wrinkles. Since there are several muscles on the lateral nasal wall, the anatomic data of the nasal muscles including the anomalous nasi muscle will be helpful to distinguish corresponding wrinkles during treatment for the wrinkles.

This report demonstrated a variation of the anomalous nasi muscle, which will be helpful for understating the nasal movements and nasal wrinkles.

Conflict of Interest

The authors declare that they have no conflict of interest.

REFERENCES

1. Morris H. Morris' Human Anatomy: A Complete Systematic Treatise. 10th ed. Philadelphia: Blakiston Co; 1947.
2. Hur MS, Hu KS, Park JT, Youn KH, Kim HJ. New anatomical insight of the levator labii superioris alaeque nasi and the transverse part of the nasalis. *Surg Radiol Anat.* 2010; 32:753-6.
3. Hur MS. Anatomical relationships of the procerus with the nasal ala and the nasal muscles: transverse part of the nasalis and levator labii superioris alaeque nasi. *Surg Radiol Anat.* 2017; 39:865-9.
4. Standring S. *Gray's Anatomy.* 41st ed. New York: Elsevier/Churchill Livingstone; 2016.
5. Clark MP, Greenfield B, Hunt N, Hall-Craggs M, McGrouther DA. Function of the nasal muscles in normal subjects assessed by dynamic MRI and EMG: its relevance to rhinoplasty surgery. *Plast Reconstr Surg* 1998; 101:1945-55.
6. Vaiman M, Eviatar E, Segal S. Intranasal electromyography in evaluation of the nasal valve. *Rhinology.* 2003; 41:134-41.
7. Baker SR. *Principles of nasal reconstruction.* 2nd ed. New York: Springer; 2011.
8. Stucker FJ, Souza CD, Kenyon GS, Lian TS, Draf W, Schick B. *Rhinology and facial plastic surgery.* Berlin: Springer; 2009.

코근이상의 1예의 해부학적 분석

이주영¹, 허미선²

¹가톨릭관동대학교 의료공학과, ²가톨릭관동대학교 의과대학 해부학교실

간추림 : 이 연구의 목적은 코근이상 한 예를 주위 구조와 관련하여 해부학적으로 기술하는 데 있다. 코근이상이 40세 여성 시신 왼쪽 얼굴에서 발견되었다. 코근이상은 코의 가쪽벽에 놓여 있었으며, 윗턱뼈 이마돌기에서 일어났다. 코근이상의 이는곳은 위입술콧방울올림근의 중간부분의 안쪽에 위치하였다. 이 근육은 위안쪽으로 올라가 안쪽눈꺼풀인대의 아래 높이에서 눈살근 앞은층 가쪽과 깊은 섬유와 합쳐졌다. 코근이상의 길이와 너비는 각각 11.9 mm와 2.8 mm였다. 이 자료는 코의 움직임과 코의 주름을 이해하는 데 도움이 될 것으로 생각된다.

찾아보기 낱말 : 코근이상, 코, 눈살근, 주름, 코의 움직임