

Spinal Nerve Position and Morphometric Analysis with Silicon Molds in the Cadaveric Lumbar Intervertebral Foramen

Soonwook Kwon 

Department of Anatomy, School of Medicine, Catholic University of Daegu

(Received 4 December 2018, revised 14 December 2018, accepted 17 December 2018)

Abstract : The intervertebral foramen is formed by two adjacent vertebrae and an intervertebral disc. Previous studies examining the foramen have been performed using various methods. The author obtained characteristics of the intervertebral foramen based on silicon mold. The author used 18 cadavers and dissected the lumbar intervertebral foramen. First, positional levels of the spinal nerve in the intervertebral foramen were measured. Second, after being removed all tissues covering the intervertebral, bony foramen was filled with melted silicon to mold the cross section. Subsequently, the solidified silicon mold was removed and stamped on a paper. The paper was scanned and analyzed area, perimeter, height and width of the intervertebral foramen on a computer. Area (average, 9.43 mm²) and perimeter (average, 48.02 mm) did not show any statistical significant pattern for any lumbar vertebral levels. However, the height and width significantly differed at the fifth lumbar vertebra, which had the shortest height (the fifth, 13.00 mm; average, 15.78 mm) and longest width (the fifth, 8.61 mm; average, 7.87 mm), although there were similar patterns in case of area and perimeter of the first to fourth lumbar vertebra. Height had a decrease tendency while width had an increase tendency both from the second to fifth lumbar vertebra. Spinal nerves went through near the intervertebral disc level from the first to fourth lumbar vertebra, although they passed below the disc at the fifth level. This study provides a different view of methodology for the 3-dimensional aspect for the intervertebral foramen. Results of this study may indicate that height and width of the intervertebral foramen changed along all lumbar vertebral levels; nevertheless, area and perimeter of the intervertebral foramen remained constant.

Keywords : Intervertebral foramen, Silicon mold, Spinal nerve, Morphometry

Introduction

The vertebral column is specially designed to provide support to the body. It is composed of bony vertebral parts, the intervertebral discs, and connecting ligaments. Between two vertebrae, there is an intervertebral disc, which

links two vertebral bodies and acts as a cushion between them. Each vertebra has a symmetric pair of the intervertebral foramina (IVFs) through which nerves, blood vessels, and lymphatics pass. Particularly, the nerves from the spinal cord occupy about 50% of the IVF [1]; therefore, pain occurs even with relatively small changes in joint movement [2]. The IVF is formed by the superior and inferior pedicles, two vertebral bodies, an intervertebral disc anteriorly, and superior and inferior facet joints posteriorly. Specifically, the IVFs in the lumbar vertebral column are oval-, auricle-, or eye shaped [3].

The author(s) agree to abide by the good publication practice guideline for medical journals.

The author(s) declare that there are no conflicts of interest.

Correspondence to : Soonwook Kwon (Department of Anatomy, School of Medicine, Catholic University of Daegu)

E-mail : anatomy3@cu.ac.kr

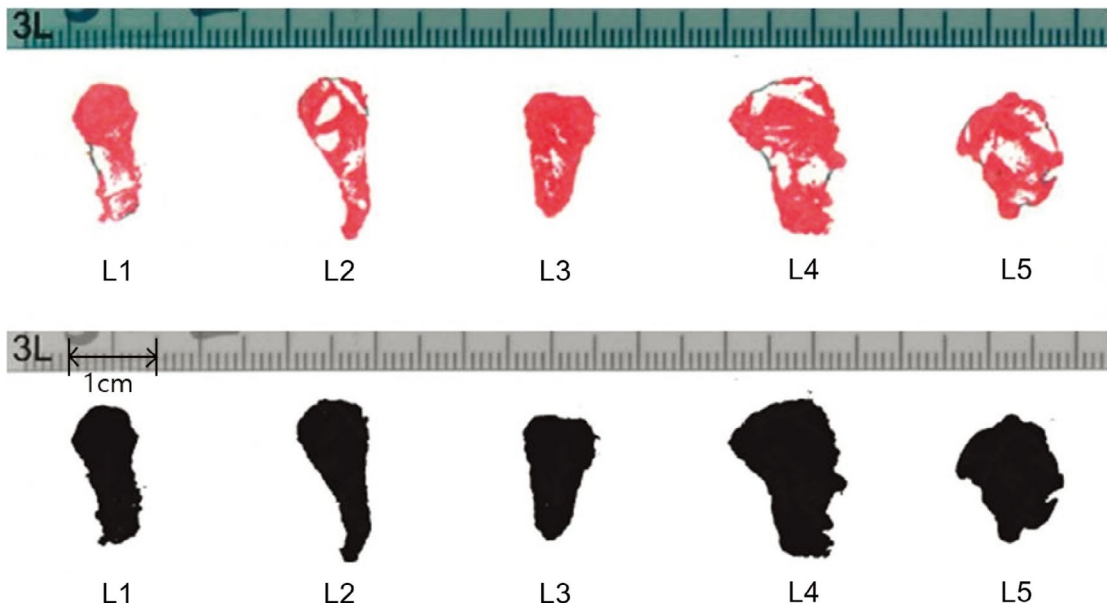


Fig. 1. Stamp of silicon molds for measurements. The IVF stamps (red, upper) of the cross sections were edited and recreated as gray scale TIFF formats (black, lower). Area, perimeter, height and width of the IVF were measured in the image via the NIH image tool.

A few previous studies have reported the areas, heights, and widths of the IVFs in dry bones of cadavers measured using a caliper or imaging studies, such as computed tomography (CT) or magnetic resonance imaging (MRI). Due to its three dimensional property of dry bone, a simple planar measurement for the structure revealed several limitations. These barriers were common in measurement with CT or MRI because computerized images were viewed in a sagittal or an axial plane which only showed two dimensional plane. Therefore, these previous studies showed their limitations for measurement of three dimensional structures. Moreover, the results of the lumbar vertebrae showed inconsistency, which seemed to arise from differences in methodologies [4-8].

The author presents a method to measure the areas, heights, widths, and perimeters of the IVFs in the lumbar region, from L1 to L5, using silicon molds. As silicon can be molded as shape of the structure until it is solidified, this advantage could be used to mimic the same morphology of a complex bony structure to reveal three dimensional properties [9]. After being removed from the bone, the silicon can be cut to show its cross section that might explain real three dimensional structures. Thus, this method might provide the three-dimensional parameters of the IVFs that are close to the original values *in vivo*.

Materials and Methods

Cadavers

The author studied 15 male and 6 female cadavers after approval of the ethics committee. All cadavers were proved to have no identification for each of them to protect human rights. All cadavers were formalin-fixed in the supine position with no distortion, lateral rotation, flexion, or extension. After preparation of cadavers, three male cadavers damaged by the students were excluded from this study. The average age of the cadavers was 58 (58.0 ± 15.5) years (range 25~84 years). None had a history of vertebral pathology or physical trauma. Before dissection for the bony foramen, the center of the spinal nerve was defined as the point through which the nerve exited the vertebral canal in the sagittal plane. All centers of the spinal nerves surrounded *in situ* by fat or connective tissue in the IVF were examined to measure their positional levels. The *en bloc* lumbar vertebral columns of 18 cadavers were carefully examined from T12-S1. The author defined the foramen between the L1-L2 vertebrae as L1. All the blood vessels, ligaments, and connective tissues were dissected to expose the bony vertebral column.

Silicon molding of foraminal space

To determine the narrowest cross-section of the IVF, melted silicon glue (Microfil; Flow Tech Inc., Carver, MA) was poured into each foramen and kept until it hardened. The hardened mold did not show any contraction or expansion in the foramen. The author defined the narrowest part of the foramen when the author measured the smallest value of the perimeter of the foramen with three times trials. After extraction, the narrowest part of each mold was carefully examined visually in various views, marked with a pen, and sliced gently using a sharp saw. Each of the narrowest section was stamped with ink on a recording paper and scanned for the digital imaging process. Some of the scanned images showed holes, which were filled in black using Adobe Photoshop CS. The areas, perimeters, and supero-inferior (height) and antero-posterior (width) diameters of all the digital images were measured using the National Institute of Health (NIH) image software (Fig. 1). All the procedures were performed bilaterally, although both right and left side data were combined for statistical analyses.

Statistical analysis

The author fitted a linear mixed model to the data considering the repeated measures in the left and right sides. In order to test the difference of the means of each levels, the author performed a multiple comparison analysis of the means of the areas, perimeters, heights, and widths measured in the five lumbar foramina (from L1 to L5) using the Bonferroni's adjustment respectively. In addition, the author performed the linear-by-linear association test to reveal any trend or association between the five lumbar foramina and the location level of the nerves passing

through the IVFs. All probability values of under 0.05 were considered to be statistically significant. The SAS software (version 9.4, SAS Institute Inc., Cary, NC, USA) was used for all statistical analyses.

Results

Area and perimeter of the lumbar intervertebral foramen

The means of the areas and perimeters of the IVFs showed a stable pattern at all the lumbar vertebral levels. The means of the areas showed no statistical difference in

Table 1. Area and perimeter of the intervertebral foramina (unit: mm² for area and mm for perimeter).

Level		Area			Perimeter		
		Left	Right	Total	Left	Right	Total
L1	N	15	15	30	15	15	30
	Mean	9.46	8.73	9.10	48.91	45.29	47.10
	S.D.	1.78	1.69	1.74	7.13	5.43	6.49
L2	N	15	16	31	15	16	31
	Mean	10.09	9.35	9.71	51.19	47.67	49.37
	S.D.	1.79	2.13	1.97	6.43	7.24	6.98
L3	N	15	16	31	15	16	31
	Mean	10.55	9.36	9.94	52.92	48.36	50.57
	S.D.	2.98	2.83	2.92	6.44	9.48	8.35
L4	N	17	16	33	17	16	33
	Mean	9.45	9.04	9.25	48.52	46.33	47.46
	S.D.	2.54	3.67	3.09	7.79	13.68	10.93
L5	N	12	16	28	12	16	28
	Mean	8.98	9.25	9.14	45.41	45.27	45.33
	S.D.	3.09	4.26	3.74	8.85	12.16	10.68
Total	N	74	79	153	74	79	153
	Mean	9.73	9.15	9.43	49.53	46.60	48.02
	S.D.	2.46	3.01	2.77	7.54	9.93	8.95

S.D.: standard deviation

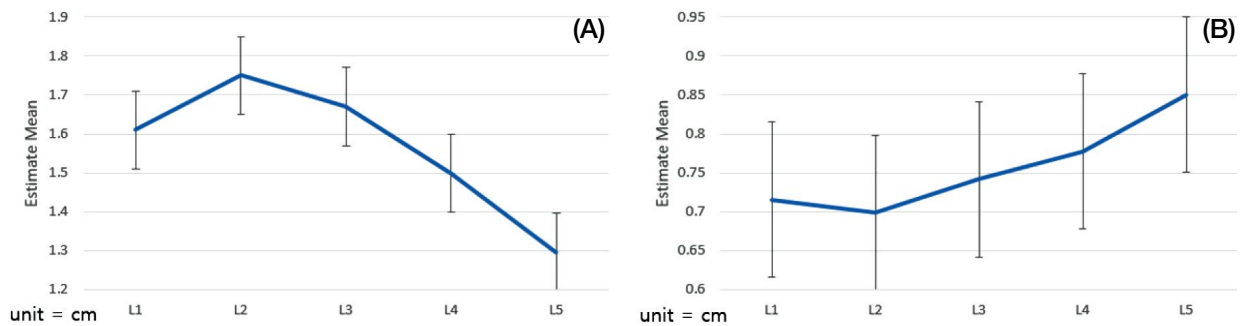


Fig. 2. Height (A) and width (B) patterns of the IVFs. The heights in L1-L5, L2-L5, L3-L5 have different values and show statistical significance among them. The width shows similar statistical significance in L1-L5 and L2-L5. Standard errors are shown as whiskers at each level.

the right and left sides, whereas the means of the perimeters showed statistical difference between the right and left sides ($p=0.034$). The area of the section at the L3

Table 2. Height and width of the intervertebral foramina (unit: mm).

Level	Height			Width			
	Left	Right	Total	Left	Right	Total	
L1	N	15	15	30	15	15	30
	Mean	16.75	15.68	16.22	7.18	7.07	7.13
	S.D.	1.812	2.18	2.04	0.94	0.94	0.93
L2	N	15	16	31	15	16	31
	Mean	18.29	16.88	17.56	6.99	7.01	7.00
	S.D.	1.95	2.95	2.58	0.72	0.72	0.71
L3	N	15	16	31	15	16	31
	Mean	17.68	16.15	16.89	7.55	7.29	7.41
	S.D.	2.99	3.92	3.53	1.27	0.83	1.05
L4	N	17	16	33	17	16	33
	Mean	15.33	14.69	15.02	7.87	7.68	7.78
	S.D.	3.36	4.84	4.09	1.19	1.27	1.21
L5	N	12	16	28	12	16	28
	Mean	13.08	12.94	13.00	8.56	8.66	8.61
	S.D.	2.76	3.32	3.04	2.06	2.74	2.43
Total	N	74	79	153	74	79	153
	Mean	16.33	15.26	15.78	7.60	7.55	7.57
	S.D.	3.14	3.74	3.50	1.35	1.59	1.47

S.D.: standard deviation

Table 3. Results of linear mixed models for height and width and of testing for equality of effects in each model.

Variable	Test of Effects				
	Effect	Num DF	Den DF	F value	Probability > F
Height	Side	1	67	4.71	0.0335*
	Level	4	79	6.08	0.0003*
Width	Side	1	67	0	0.9733
	Level	4	79	3.71	0.0081*

Num DF: degrees of freedom for the numerator
Den DF: degrees of freedom for the denominator

Table 4. Results of least square means (denoted by estimate) and multiple comparisons.

Vertebral Level		Height			Weight		
Level	Level	Estimate	Standard Error	Adjusted P-value	Estimate	Standard Error	Adjusted P-value
L1	L2	-0.140	0.101	1.000	0.017	0.044	1.000
L1	L3	-0.060	0.101	1.000	-0.260	0.044	1.000
L1	L4	0.112	0.101	1.000	-0.620	0.044	1.000
L1	L5	0.314	0.102	0.029*	-0.135	0.045	0.034*
L2	L3	0.080	0.100	1.000	-0.043	0.044	1.000
L2	L4	0.252	0.099	0.134	-0.079	0.043	0.730
L2	L5	0.454	0.101	0.000*	-0.152	0.044	0.009*
L3	L4	0.172	0.099	0.886	-0.036	0.043	1.000
L3	L5	0.374	0.101	0.004*	-0.109	0.044	0.157
L4	L5	0.202	0.100	0.475	-0.073	0.044	1.000

level ($9.94 \pm 2.92 \text{ mm}^2$) was the largest among the areas of all the lumbar vertebral levels. The order of decrease in average area was $L3 > L2 > L4 > L5 > L1$, although the data showed no statistical significance. The perimeter of the section at the L3 level ($50.57 \pm 8.35 \text{ mm}$) was also the largest. The order of decrease in average perimeter was $L3 > L2 > L4 > L1 > L5$, with no statistical significance (Table 1).

Height and width of the lumbar intervertebral foramen

The means of the heights and widths showed no statistical difference in the right and left sides. The L5 IVF was the shortest ($13.00 \pm 3.04 \text{ mm}$) and widest ($8.61 \pm 2.43 \text{ mm}$) (Fig. 2). The means of the heights showed the following order: $L2 > L3 > L1 > L4 > L5$. The means of the widths showed the following order: $L5 > L4 > L3 > L1 > L2$ (Table 2). From L1 to L4, the heights and widths of the IVFs showed a stable pattern that was similar to the areas and perimeters regarding the statistical significance. However, in multiple comparison analysis of the IVFs of all the lumbar levels, differences were observed (Table 3). A multiple comparison analysis using the Bonferroni's correction revealed that the height differences in L1-L5, L2-L5, and L3-L5 and width differences in L1-L5, and L2-L5 showed statistical significance, while the differences in the lumbar vertebrae (L1 to L4) showed no statistical significance (Table 4).

Position Levels of Nerve Exit in the IVFs

The levels of the spinal nerve pathways through the IVFs revealed a pattern similar to the heights of the IVFs.

Table 5. Nerve location levels in the intervertebral foramina.

	L1	L2	L3	L4	L5
Above disc	4	0	0	0	0
U 1/3	11	5	2	4	0
M 1/3	14	13	14	12	5
L 1/3	7	15	15	17	6
Below disc	0	3	5	3	24
Total Number	36	36	36	36	35

U = upper, M = middle, and L = Lower 1/3 of the intervertebral disc, no nerves were described as zero

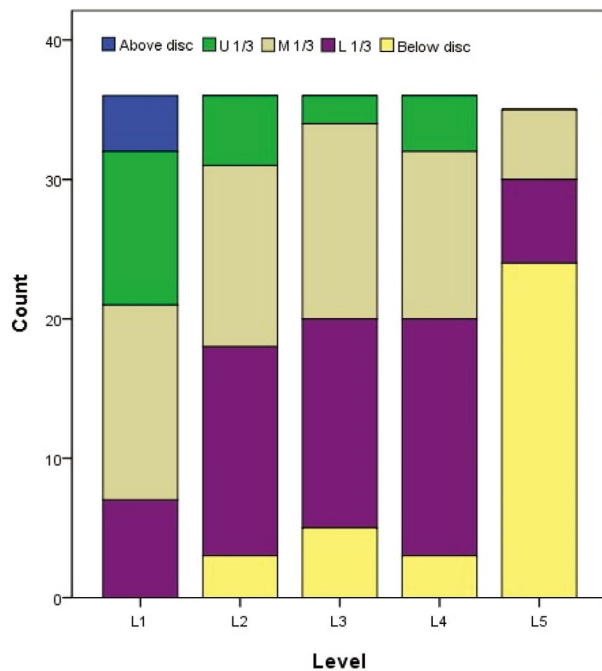


Fig. 3. Nerve location levels in the IVFs. From L1 to L5, lower lumbar level tends to have lower position of nerve pathways. The L5 has many nerve pathways running below the intervertebral disc level (U = upper, M = middle, and L = Lower 1/3 of the intervertebral disc).

A linear-by-linear association test revealed that the location levels of the nerve pathways had an association with the lumbar levels ($p < 0.0001$). Only in the L1, the spinal nerves were located above the intervertebral disc (four cases), whereas at the other lumbar levels this was not observed. The ratio of the upper and middle levels of the intervertebral disc at L1 was about two-thirds. The middle and lower levels formed a majority in L2, and a similar pattern was observed in L3 and L4. However, in L5, two-thirds of the nerves were located below the intervertebral disc (Table 5, Fig. 3).

Discussion

The means of the areas and perimeters of the IVFs showed no statistical differences at all the lumbar levels, although the heights and widths of the IVFs changed. From L1 to L4, there were no statistically significant differences in the heights; however, a decreasing tendency of the height was observed from L2 to L5. As L5 was the shortest, a multiple comparison analysis at the lumbar levels, L1-L5, L2-L5, and L3-L5, showed height differences. In contrast to the result of the height, the widths of the IVFs tended to increase from L2 to L5, and L5 was the widest. The lumbar differences, at L1-L5 and L2-L5, showed statistical differences, but with no differences from L1 to L4. Although the values of IVF at L4-L5 showed no statistical significance, it seemed to exhibit a transitional state to L5 regarding the height and width. These results may indicate that the heights and widths of the IVFs changed at each lumbar levels, whereas, the areas and perimeters of the IVFs remained constant. As the lumbar vertebrae support the upper body, it might explain consistence of morphology or volumes of the bone. These might show a similar pattern of the IVFs from L1 to L4. However, as it goes to the L5 and the sacrum level, function of body supporting could be changed, which might show that the height and width of IVF at the L5 differed from those of other levels. The spinal nerves revealed a pattern similar to the heights, and were observed from a higher to lower position in the IVF along the L1-L5 lumbar vertebrae. The spinal nerves tended to have a high position at a high lumbar level (L1) and a low position at a low lumbar level (L5). This pattern seemed to indicate that the L5 spinal nerve was specifically lower because the L5 IVF height was shorter than the IVF heights at other lumbar levels.

Although previous studies were performed with calipers because of their practical limitation in measurement of the IVFs, this study provided a three-dimensional method to measure the parameters of the IVFs. Because an IVF has a complex morphology, which is difficult to measure due to its three-dimensional characteristics [10], the author made silicon molds fitting the IVFs. When silicon model is solidified, it shows hardness but has flexibility like a rubber. Thus, silicon model remembers and returns to its shape after torsion, twist, or other changes. Moreover, before silicon is solidified, it could be melted to fit a shape to mold. With this flexible property, the author filled the lumbar

IVFs with silicon. The silicon molds of the IVFs were not grossly different from the spaces of the IVFs. The author measured the smallest area and perimeter of the silicon mold when it was examined because the author understood the importance of a narrowing foramen which might cause compression of nerves or blood vessels. Therefore, several times trials were adapted before cutting the mold to measure the smallest perimeter as a definition of the narrowest values of the IVFs. Using scanned molds, computerized analyses were applied to measure the areas, perimeters, heights, and widths of the IVFs. Previous reports regarding IVFs have shown that the average range of IVF height was 11~19 mm and the average width was about 7 mm in cadavers or dry bones measured using calipers [11].

Recent *in vivo* study that used 3D CT also revealed that foraminal height was between 15.9 mm and 18.0 mm and foraminal width was between 5.0 and 7.2 mm. Moreover, the height order reported in this study ($L2 > L1 > L3 > L4 > L5$) was very similar to my result ($L2 > L3 > L1 > L4 > L5$) with a slight difference [10]. Previous reports have shown varied results because the IVFs were of various shapes and sizes [4-8]. Other imaging studies using CT or MRI have shown different measurements methods; however, they only studied the two-dimensional aspect because of their sectional plane [5,7,12]. The author selected and cut the smallest area of the molds by careful visual inspection of the sagittal plane; therefore, the results of this three-dimensional analysis using silicon molds resembling the IVFs could provide precise results of IVF characteristics.

The overall areas and perimeters of the IVFs showed no statistical difference from L1 to L5. This result was different from former results that observed that the areas of the sections were different at each vertebral levels. Using MRI, various studies have revealed that the average sizes of L1-L2-L3-L4 were similar; however, L5 was the smallest in both men and women of all ages [4,5,12]. Unlike some results showing that the area of the section increased from the L1 to L5 level, another result revealed that the area of L5-S1 was smaller than that of L3-4 or L4-5 and similar to that of L2-L3 [13]. Other studies have shown that the average cross-sectional area decreases in the following order: $L5-S1 > L3-L4 > L2-L3 > L4-L5 > L1-L2$ [14]. A comparison of CT and MRI results revealed that the height of the IVF was the tallest at L1 or L2 and shortest at L5, thus showing a decreased tendency from L1 to

L5, similar to my results [7,12]. Moreover, an MRI study showed that the average height of the IVFs was 20.90 ± 1.70 mm and revealed a dependent lumbar level pattern in men aged 20 to 50 years old [11]. Although this study did not perform a multiple comparison analysis among the lumbar levels, its results of the decreasing tendency and the L5 height were similar to my results. In a Japanese study that evaluated MRI results, the height range of the IVFs was similar to that observed in my results from L1 to L4, except at L5 (L1-L2, 17.1 ± 2.0 mm; L2-L3, 18.4 ± 1.7 mm; L3-L4, 18.1 ± 1.5 mm; L4-L5, 17.3 ± 1.8 mm; L5, 17.1 ± 3.6 mm) [5]. The heights of the IVFs in my study were as follows: from L1 to L4, 16.4 ± 3.0 mm; L5, 13 ± 3.0 mm, which was within the range of 11~19 mm observed in previous studies [11,15]. These correlations might reveal the reliability of my method. Magnusson observed that the average IVF width was 7 mm, which supported my results (7.5 mm) [15]. In contrast to this results showing that L5 IVF was the shortest in height and widest in width, some previous studies mentioned that the heights and widths of the IVFs were similar at all the vertebral levels [5,16]. Moreover, in a dry bone study, conducted in Switzerland, regarding the widths of the IVFs revealed that the L5 width was narrower than that of L1, showing results contrary to my results. These differences among the results of IVF studies might be due to differences in age, sex, and number of subjects, and differences in demography and the methods used for the studies.

This study had several limitations with regard to age-, and sex distribution and the number of cadavers due to donation problems. Aging in humans could make the intervertebral disc shrink, thus shortening the heights of the IVFs. Moreover, previous studies reported that alteration of height of IVFs and disc were related, which might mean that the intervertebral disc could also affect all aspects of morphology of the IVFs [10,16-18]. Therefore, a further research based on a classification according to the ages would be effective in analyses. Furthermore, men are generally larger than women; however, the Switzerland study observed that the widths of female IVFs in the lumbar region were somewhat larger than that of male IVFs [19]. Thus, a subsequent study to investigate the relationship of sex differences and parameters of the IVFs should be conducted. Additionally, the perimeter only showed a difference in the right and left sides, which was not found with regard to the area, height, and width. This phenomenon

should be verified in a future study including a large sample sizes. Moreover, in a future study, the results should be verified using vertebral movements, which could indicate dimensional alterations to the IVF and the nerve location level in the IVF [2,20].

The lumbar IVFs characteristics were studied using silicon molds in this research; the cervical or thoracic vertebral columns should be analyzed in future. The author hopes that a further study will be conducted using three-dimensional analyses of imaging studies with silicon molds of cadavers to improve the methodology. The results of this study could be used to perform precise surgery on the lumbar vertebral fracture or other bone deformities. In addition, more accurate knowledge on the IVF might be used a new development of medical devices or nerve root blocks near the IVF.

REFERENCES

1. Sunderland S. Meningeal-neural relations in the intervertebral foramen. *J Neurosurg.* 1974; 40:756-63.
2. Fujiwara A, An HS, Lim TH, Haughton VM. Morphologic changes in the lumbar intervertebral foramen due to flexion-extension, lateral bending, and axial rotation: an in vitro anatomic and biomechanical study. *Spine.* 2001; 26:876-82.
3. Inman VT, Saunders JBdM. The clinico-anatomical aspects of the lumbosacral region. *Radiology.* 1942; 38:669-78.
4. Cramer GD, Cantu JA, Dorsett RD, Greenstein JS, McGregor M, Howe JE, et al. Dimensions of the lumbar intervertebral foramina as determined from the sagittal plane magnetic resonance imaging scans of 95 normal subjects. *J Manipulative Physiol Ther.* 2003; 26:160-70.
5. Hasegawa T, Mikawa Y, Watanabe R, An HS. Morphometric analysis of the lumbosacral nerve roots and dorsal root ganglia by magnetic resonance imaging. *Spine.* 1996; 21:1005-9.
6. Karabekir HS, Gocmen-Mas N, Edizer M, Ertekin T, Yazici C, Atamturk D. Lumbar vertebra morphometry and stereological assesment of intervertebral space volumetry: a methodological study. *Ann Anat.* 2011; 193:231-6.
7. Smith GA, Aspden RM, Porter RW. Measurement of vertebral foraminal dimensions using three-dimensional computerized tomography. *Spine.* 1993; 18:629-36.
8. Torun F, Dolgun H, Tuna H, Attar A, Uz A, Erdem A. Morphometric analysis of the roots and neural foramina of the lumbar vertebrae. *Surg Neurol.* 2006; 66:148-51.
9. Knapik DM, Abola MV, Gordon ZL, Seiler JG, Marcus RE, Liu RW. Differences in cross-sectional intervertebral foraminal area from C3 to C7. *Global Spine J.* 2018; 8:600-6.
10. Senoo I, Espinoza Orias AA, An HS, Andersson GB, Park DK, Triano JJ, et al. In vivo 3-dimensional morphometric analysis of the lumbar foramen in healthy subjects. *Spine.* 2014; 39:E929-35.
11. Epstein BS, Epstein JA, Lavine L. The effect of anatomic variations in the lumbar vertebrae and pinal canal on cauda equina and nerve root syndromes. *AJR Am J Roentgenol.* 1964; 91:1055-63.
12. Al-Hadidi MT, Abu-Ghaida JH, Badran DH, Al-Hadidi AM, Ramadan HN, Massad DF. Magnetic resonance imaging of normal lumbar intervertebral foraminal height. *Saudi Med J.* 2003; 24:736-41.
13. Min JH, Kang SH, Lee JB, Cho TH, Suh JG. Anatomic analysis of the transforaminal ligament in the lumbar intervertebral foramen. *Neurosurgery.* 2005; 57:37-41.
14. Inufusa A, An HS, Lim TH, Hasegawa T, Haughton VM, Nowicki BH. Anatomic changes of the spinal canal and intervertebral foramen associated with flexion-extension movement. *Spine.* 1996; 21:2412-20.
15. Magnuson PB. Differential diagnosis of causes of pain in the lower back accompanied by sciatic pain. *Ann Surg.* 1944; 119:878-91.
16. Cinotti G, De Santis P, Nofroni I, Postacchini F. Stenosis of lumbar intervertebral foramen: anatomic study on predisposing factors. *Spine.* 2002; 27:223-9.
17. Miller JA, Schmatz C, Schultz AB. Lumbar disc degeneration: correlation with age, sex, and spine level in 600 autopsy specimens. *Spine.* 1988; 13:173-8.
18. Schlegel JD, Champine J, Taylor MS, Watson JT, Champine M, Schleusener RL, et al. The role of distraction in improving the space available in the lumbar stenotic canal and foramen. *Spine.* 1994; 19:2041-7.
19. Rühl FJ, Müntener M, Henneberg M. Human osseous intervertebral foramen width. *Am J Phys Anthropol.* 2006; 129:177-88.
20. Kitagawa T, Fujiwara A, Kobayashi N, Saiki K, Tamai K, Saotome K. Morphologic changes in the cervical neural foramen due to flexion and extension: in vivo imaging study. *Spine.* 2004; 29:2821-5.

허리의 척수신경위치와 실리콘을 이용한 척추사이구멍에 대한 형태학적 분석

권순욱

대구가톨릭대학교 의과대학 해부학교실

간추림 : 척추사이구멍은 인접한 두 척추뼈와 그 사이의 척추사이원반으로 구성된다. 이전의 척추사이구멍에 대한 연구들은 다양한 방법으로 수행이 되었다. 이번 연구에서는 실리콘 주형을 이용해서 척추사이구멍의 특징을 알아보았다. 시신18구를 해부하여 허리의 척추사이구멍을 해부하였다. 첫째로는 척수신경의 위치를 측정하였다. 둘째로는 척추사이구멍을 덮고있는 모든 조직을 제거하여 척추사이구멍 단면의 가장 좁은 부위를 측정하였다. 조직이 제거된 척추사이구멍은 실리콘주형으로 채워졌다. 실리콘주형이 굳어진 다음에는 구멍에서 분리되었다. 단면으로 잘린 실리콘주형을 종이 위에 도장처럼 찍고, 그것을 컴퓨터에 저장하였다. 척추사이구멍의 주형의 면적, 둘레, 높이, 폭이 컴퓨터에서 분석되었다. 허리의 다섯 개 척추사이구멍에서 면적과 둘레는 통계학적인 차이를 보이지 않았다. 하지만 둘째에서 다섯째 허리뼈에 걸쳐서 높이는 낮아지는 경향, 폭은 넓어지는 경향을 보였다. 또한 높이와 폭은 다섯째 구멍에서 유의미한 차이가 있었다. 높이는 다른 구멍들 중에서 가장 낮았고, 폭은 가장 넓었다. 척수신경은 첫째에서 넷째허리뼈에서는 척추사이원반 근처를 지나갔고, 다섯째허리뼈에서는 척추사이원반 아래쪽으로 지나갔다. 이번 연구는 척추사이구멍의 3차원적 입체 구조를 실리콘주형으로 확인하였다. 기존의 평면적 연구에서 관찰되지 않았던 다른 성질들을 확인할 수 있었다. 즉, 허리척추뼈에서 척추사이구멍의 면적과 둘레는 일정하였으나 높이와 폭은 전체적으로 변화하는 양상을 보였다.

찾아보기 낱말 : 척추사이구멍, 실리콘 주형, 척수신경, 형태 계측