

Variation of the Axillary Arch in Korean Cadaver

Hyun-Seok Jeong^{1,†}, Seong-Woo Jo^{1,†}, Jae-Ho Lee²

¹Medical Course, Keimyung University School of Medicine, Daegu, Republic of Korea

²Department of Anatomy, Keimyung University School of Medicine, Daegu, Republic of Korea

(Received 7 September 2018, revised 20 October 2018, accepted 22 October 2018)

Abstract : Axillary arch is relatively common variation of muscle in the axilla. There were several attentions on axillary arch due to its anatomical and surgical importance. During educational dissection, a variant muscle was found in right arm of 68-year-old female cadaver. The variation of muscle originated from the lateral edge of the latissimus dorsi muscle as muscular form. And then, it crossed the axillary artery and median nerve as tendinous form. Finally it became wide as muscular form and inserted into the pectoralis major. We reported this variant muscle and discussed its clinical significances.

Keywords : Axillary arch, Langer's muscle, Latissimus dorsi, Pectoralis major, Variation

There were several attentions on axillary arch, known as Langer's axillary arch for several years due to its anatomical and surgical importance [1]. The axillary arch extends between the latissimus dorsi and the pectoralis major muscles usually as long bridge-like form [2]. Its insertion varied as pectoralis minor, lesser tubercle, teres major, biceps brachii, coracobrachialis, and coracoid process [1-4]. The prevalence of this variation muscle is near 7~8%, however, it was various according to the populations [4]. Its size may vary from 70 to 100 mm in length and 5~15 mm [5]. Therefore, the shape, size, and insertion of the arch can vary widely [1-5].

In this report, we introduced a rare pattern of axillary arch muscle and explained its clinical implications. Though

most of axillary arch is usually asymptomatic, the clinicians should consider its clinical significance associated with neurovascular structures [6].

Case Report

During educational dissection in Keimyung University School of Medicine, the upper limbs were dissected and observed carefully to study the anatomical structures of the axilla in right arm of 68-year-old female cadaver. The skin, superficial and deep fasciae were removed to expose the pectoral region and axilla. The pectoralis major and the latissimus dorsi muscles and its variant muscular slip was noted. There was no gross evident pathology or evidence of past surgical procedures involving the axilla, the shoulder or the anterior thoracic wall.

A slip muscle originated from the lateral border of the latissimus dorsi and crossed the axilla obliquely. Therefore, we defined this muscular variation as axillary arch (Fig. 1). This muscle originated from the lateral edge of the latissimus dorsi muscle as muscular form. And then, it crossed

[†]These authors contributed equally to this work.

*This study was performed during Student internship program of 4th grade student in medical college.

The author(s) agree to abide by the good publication practice guideline for medical journals.

The author(s) declare that there are no conflicts of interest.

Correspondence to : Jae-Ho Lee (Department of Anatomy, Keimyung University School of Medicine, 1095 Dalgubeol-daero, Dalseo-gu, Daegu 42601, Republic of Korea)

E-mail : anato82@dsmc.or.kr

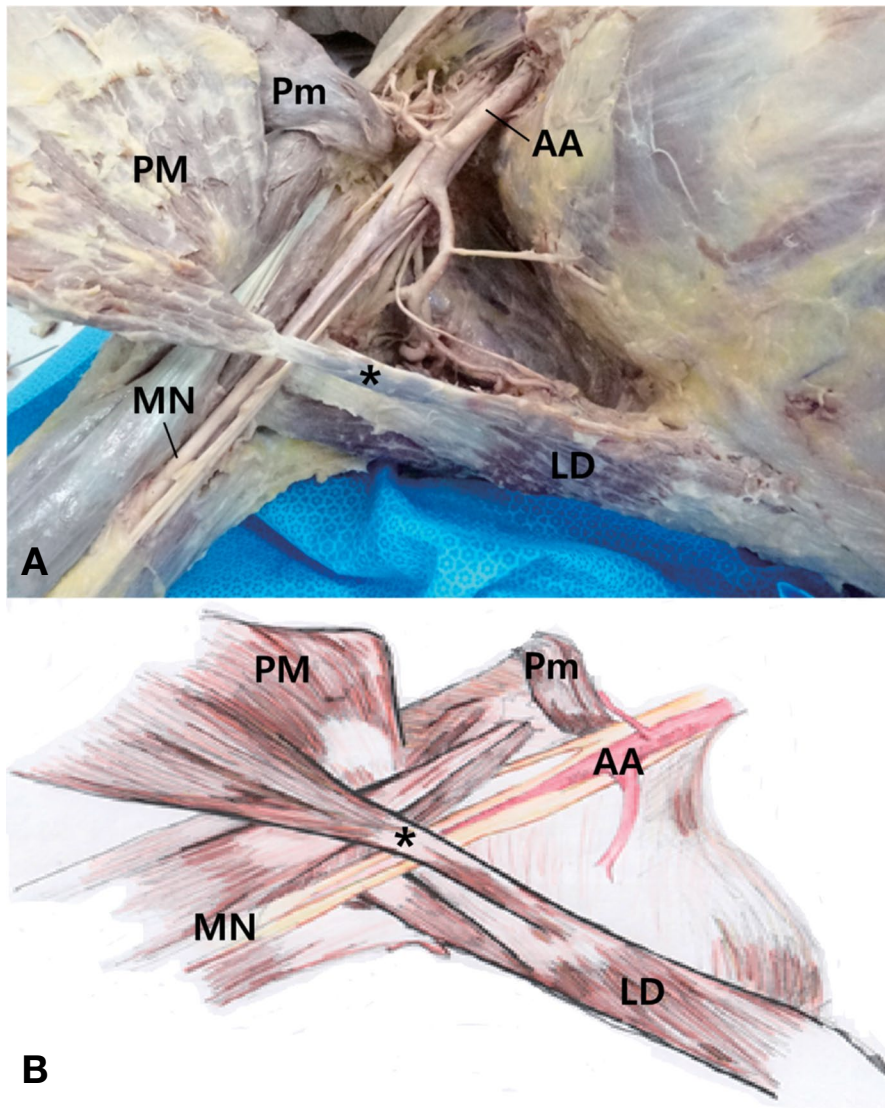


Fig. 1. Photograph (A) and schematic drawing (B) of the right axilla showing the axillary arch (*). It extended from the latissimus dorsi (LD) to the pectoralis major (PM) and crossed the axillary artery (AA) and median nerve (MN). Pm, pectoralis minor.

the axillary artery and median nerve as tendinous form. This part measured 3.3 mm in length and 0.5 mm in width. And then, it became wide and linked to the lower part of the pectoralis major muscle. Its upper part inserted into the lateral lip of the bicipital groove of the humerus. There were no other variations, especially chondroepitrochlearis. And the origin and insertion of the pectoralis major and latissimus dorsi muscles in the left axilla were normal.

Discussion

The first description of axillary arch was attributed to

Ramsay in 1795 and it was confirmed by Langer in 1864 [2]. Its frequency varied from the 0.25% to 37.5%, depending on the ethnic groups [4]. In Korean, axillary arch was found in 7.4% (79/1,069) of patients with breast cancer [7], which is similar with Europeans and Japanese; lower in the Turkish population and more prevalent in the Chinese population [4]. Embryological origin of the axillary arch has not been identified yet. Axillary arch may be rudimentary remnants of homologous structures in other species, as panniculus carnosus which is well developed in some lower mammalian species [8]. However, additional information about its embryological aspect should be established further.

Axillary arch originated from either latissimus dorsi, whereas its insertion was extremely varied. Testut proposed the classification of axillary arch as complete and incomplete according to its insertion [3]. The complete form inserted to the pectoralis major tendon near its insertion site on the humerus; in the incomplete form, the axillary arch extended to the axillary fascia, biceps brachii muscle, coracobrachialis muscle, the distal end of the bicipital groove, the inferior edge of the pectoralis minor muscle, or the coracoid process. Recent meta-analysis showed that one third of axillary arch was considered as the complete form [9]. Present case is complete form as inserted to pectoralis major muscle directly. Interestingly, axillary arch in our case showed a transition from muscle belly to tendinous form on neurovascular structures. Previous cases also showed a change as narrow or tendon near neurovascular structures [10,11]. It was suggested that additional muscle as axillary arch tend to be reduced near neurovascular structures in axilla due to limited space. Further study should be needed to clarify this hypothesis.

Axillary arch has medical implication such as neurovascular compression syndrome, hyperabduction syndrome, vein thrombosis, a high tense pectoralis minor tendon, thoracic outlet and shoulder instability syndrome [4,6]. This variation is also important in surgical field. During lymphadenectomy, it may obscure lymph nodes so that it leads inadequate clearance and increase recurrence [7,9]. In breast reconstruction using latissimus dorsi myocutaneous flap, if the arch is divided not properly it may result in flap ischemia [10]. As axillary arch muscle may be palpable in living subjects, physicians may have a misdiagnosis it as tumor during clinical examination of the axilla [4,9]. Moreover, axillary arch tended to coexist other muscular variation, especially chondroepitrochlearis, extended from the pectoralis major to the medial epicondyle [12]. Though other variant muscle was not shown in our case, their co-existence may induce unexpected and uncommon clinical conditions [6,7]. Therefore, clinician should be aware of knowl-

edge about these variations due to their close relationship to the neurovascular structures in the axilla.

REFERENCES

1. Bergman RA, Thompson SA, Afifi AK, Saadeh FA. Compendium of human anatomic variation. Baltimore-Munich: Urban & Schwarzenberg; 1998.
2. Langer K. Zur anatomie des musculus latissimus dorsi. Oester Med Wochenschrift. 1846; 15:16.
3. Testut L. Les anomalies musculaires chez l'homme. Paris: Masson; 1884.
4. Loukas M, Noordeh N, Tubbs RS, Jordan R. Variation of the axillary arch muscle with multiple insertions. Singapore Med J. 2009; 50:e88-e90.
5. Standring S. Gray's anatomy: the anatomical basis of clinical practice. 41st ed. New York: Elsevier; 2016.
6. Daniels IR, della Rovere GQ. The axillary arch of Langer - the most common muscular variation in the axilla. Breast Cancer Res Treat. 2000; 59:77-80.
7. Kil WH, Lee JE, Nam SJ. Clinical significance of the axillary arch in sentinel lymph node biopsy. J Breast Cancer. 2014; 17:244-9.
8. Yuksel M, Yuksel E, Surucu S. An axillary arch. Clin Anat. 1996; 9:252-4.
9. Tattera D, Henry BM, Zarzecki MP, Sanna B, Pękala PA, Cirocchi R, et al. Prevalence and anatomy of the axillary arch and its implications in surgical practice: A meta-analysis. Surgeon 2018 May 22 [Epub]. DOI: 10.1016/j.surge.2018.04.003.
10. Mérida-Velasco JR, Rodríguez Vázquez JF, Mérida Velasco JA, Sobrado Pérez J, Jiménez Collado J. Axillary arch: potential cause of neurovascular compression syndrome. Clin Anat. 2003; 16:514-9.
11. Miguel M, Llusá M, Ortiz JC, Porta N, Lorente M, Götzens V. The axillopectoral muscle (of Langer): report of three cases. Surg Radiol Anat. 2001; 23:341-3.
12. Bergman RA. Doubled pectoralis quartus, axillary arch, chondroepitrochlearis and the twist of the tendon of pectoralis major. Anat Anz. 1991; 173:23-6.

한국인 시신에서 랑거겨드랑활의 변이

정현석¹, 조성우¹, 이재호²

¹계명대학교 의학과, ²계명대학교 의과대학 해부학교실

간추림 : 랑거겨드랑활은 겨드랑에서 흔히 나타나는 변이다. 랑거겨드랑활의 해부학적 그리고 임상적 중요성 때문에 이에 대한 관심이 많다. 학생실습과정에 68세 여성 시신의 오른쪽 팔에서 근육변이가 관찰되었다. 이 근육은 넓은등근의 가쪽모서리에서 근육의 형태로 일어났다. 그 후 힘줄의 형태로 겨드랑동맥과 정중신경을 가로질러 지나간 후 넓어지며 다시 근육의 형태로 큰가슴근에 부착되었다. 우리는 이 근육변이를 소개하고 이것의 임상적 의의에 대해 논의하였다.

찾아보기 낱말 : 랑거겨드랑활, 넓은등근, 큰가슴근, 변이