

Complex Variations of the Sciatic Nerve Branch and Morphological Variation of the Piriformis Muscle: a Case Report

Han-Gyu Jeong¹, Jae-ho Lee¹, Soo-Jung Jung^{2,3}, Sa-Beom Park⁴, Kwang Rak Park¹

¹Department of Anatomy, Keimyung University School of Medicine

²Department of Physiology, Kyungpook National University School of Medicine

³Cell and Matrix Research Institute, Kyungpook National University

⁴Center of Biohealth Convergence and Open Sharing System, Hongik University

Abstract : The sciatic nerve (SN) is the largest peripheral nerve in the body and comes from nerve branches from L4 to S3. We observed a variation of two slips of the piriformis muscle (PM) and abnormal branching pattern of the sciatic nerve in the left gluteal region of an 84-year-old woman. The muscle belly of PM was divided into two parts, superior and inferior (sPM and iPM). The common fibular nerve (CFN) was divided into two nerve branches, major common fibular nerve (mCFN) and accessory common fibular nerve (aCFN), and then, the tibial nerve (TN) had one nerve branch. TN and aCFN exited below the iPM, and mCFN passed between the sPM and iPM. And then, CFN and TN were merged at the level of femur neck. Here, we introduced rare variation of the sciatic nerve and the piriformis muscle, and discussed its clinical and embryological significance.

Keywords : Sciatic nerve, Common fibular nerve, Tibial nerve, Piriformis muscle, Variation

INTRODUCTION

The sciatic nerve (SN) is the largest peripheral nerve in the body and comes from nerve branches from L4 to S3. It then passes through the greater sciatic foramen, exits from the pelvic to the gluteal region, and runs posteriorly to the femur. It reaches the popliteal fossa and branches into the tibial nerve (TN) and the common fibular nerve (CFN).

The author(s) agree to abide by the good publication practice guideline for medical journals.

The author(s) declare that there are no conflicts of interest.

Received: September 6, 2022; **Revised:** November 9, 2022;

Accepted: November 14, 2022

Correspondence to: Kwang Rak Park (Department of Anatomy, Keimyung University School of Medicine, 1095, Dalgubeoldaero, Dalseo-gu, Daegu 42601, Republic of Korea)

E-mail: airboba@naver.com

Then, the TN runs straight and the CFN passes around the neck of the fibula. Usually, the SN exits from the nerve branches and then travels under the piriformis muscle (PM).

The PM is the uppermost muscle in the deep group of the gluteal region. It originates from the anterior sacral foramen on the anterior aspect of the sacrum, and emerges downward through the greater sciatic foramen. Then, it inserts onto the greater trochanter of the femur. Its function is lateral rotation at the hip joint. It is innervated by the nerves to the piriformis which arises from the fifth lumbar nerve (L5) and the first and second sacral nerves (S1, S2) [1]. Beaton and Anson [2] proposed the following six classifications to define and discuss SN variants in PM: Type A: Nerves pass undivided under the muscle, Type B: Branched nerves pass between and down muscles, Type C: Nerves

branch up and down with respect to the muscle and pass through, Type D: penetrate the muscle, Type E: Branching nerves pierce one muscle up and the other through the muscle, Type F: Unbranched nerves pass above the muscles.

Sumalatha et al. [3] suggested a variation in which CFN passes through the PM with a double branch, then the thin branch innervates the gluteus maximus muscle and finally fuses with the thick branch again to become CFN. Park et al. [4] showed a complex variation of CFN penetrating the PM and branching the inferior gluteal nerve. Warner et al. [5] reported double slip in TN and CFN, in which branches of TN passed through the PM and branches of CFN came out to the inferior border of the PM.

As such, many researchers have reported a variety of previously undefined SN variations, which are being used as basic data to understand the pathological mechanisms of gluteal diseases such as piriformis syndrome and sciatica. In this report, we showed two slips of PM and branch variation of SN.

CASE REPORT

We observed a variation of PM and SN in the left gluteal region of an 84-year-old woman. Left gluteal region was dissected in the prone position. Skin peeling proceeded along the skin incision, and the subcutaneous tissue was removed.

The cadaver was dissected and the gluteus maximus muscle was observed after the skin of the gluteal region was removed. After the gluteus maximus was turned laterally, the nerves and vessels were revealed. The anatomical structures of the SN and PM, superior gluteal artery and nerve, inferior gluteal artery and nerve were clearly identified (Fig. 1).

The muscle belly of PM was divided into two parts, superior and inferior (sPM and iPM). The SN is respectively separated into the CFN and the TN, exits the pelvis and descends to the posterior thigh. CFN showed variation in the form of dividing into two nerve branches, the major common fibular nerve (mCFN) and the accessory common fibular nerve (aCFN). The lateral branch with a thick diameter was set as the main branch of the CFN branch, and the medial branch was set as an accessory branch. TN and aCFN exit below the iPM, respectively, and mCFN passes through between the sPM and iPM (Fig. 2).

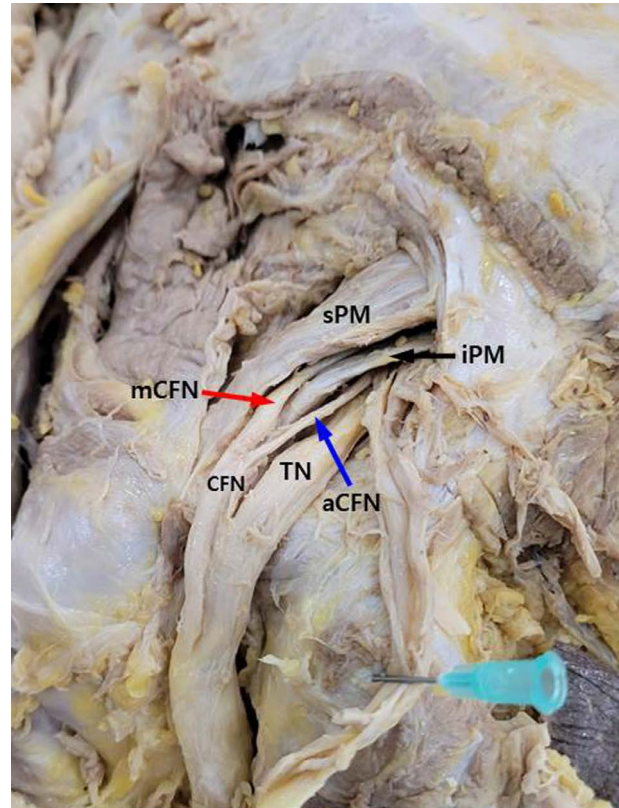


Fig. 1. Posterior view of the left gluteal region. CFN, common fibular nerve; mCFN (red arrow), major CFN; aCFN (blue arrow), accessory CFN; PM, piriformis muscle; sPM, superior slip of PM; iPM (black arrow), inferior slip of PM.

The length and thickness of PM, mCFN, aCFN, and TN were measured using a caliper (Sincon corporationTM), and the minimum unit of measurement was 0.1 mm. The thickness and width of the PM were measured at the midpoint of origin and insertion. The length of the TN was measured from the point where it exits the PM to the point where it meets the CFN, and the lengths of mCFN and aCFN were measured from the point where the two nerves meet from the point where they exit the PM. The thickness of all nerves was measured at the midpoint of the measured length. As a result, the thickness and width of sPM were 3.5 mm and 16.8 mm, respectively. And those for iPM were 2.7 mm and 8.5 mm, respectively. The widths of TN, mCFN, and aCFN were 7.9 mm, 3.2 mm, and 1.3 mm, respectively. The lengths of TN, mCFN, and aCFN were 21.2 mm, 10.1 mm, and 15.7 mm, respectively. On the right, both CFN and TN showed a normal anatomical shape in which both CFN and TN came out of the inferior margin of the PM.

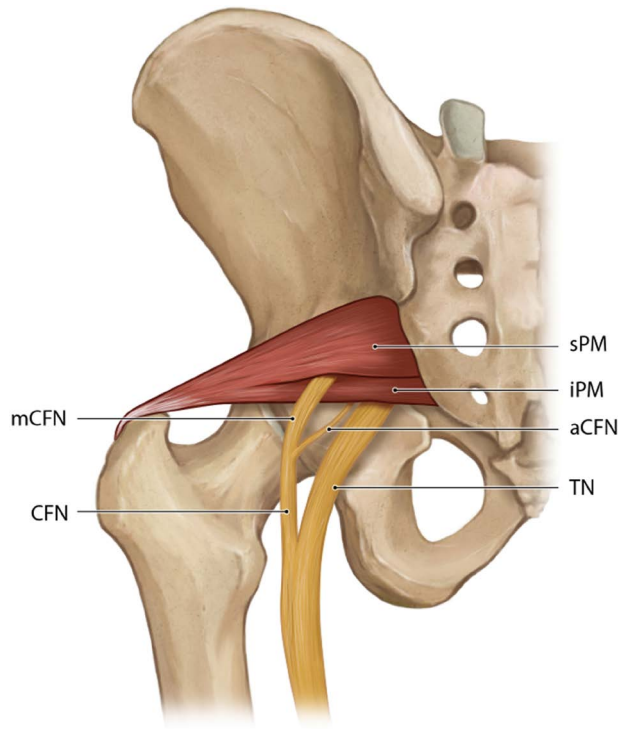


Fig. 2. Schematic diagram of complex variations of the left gluteal region. CFN is divided into mCFN and aCFN, and mCFN exits through the PM (between sPM and iPM). CFN, common fibular nerve; mCFN, major CFN; aCFN, accessory CFN; PM, piriformis muscle; sPM, superior slip of PM; iPM, inferior slip of PM.

DISCUSSION

In this case, we found that mCFN, the thick branch of the lateral one of the two branches of CFN, passed between the variation in which PM was divided into two slips, superior and inferior (sPM and iPM). The possibility that the nerve exiting between these muscles becomes nerve entrapment due to the spasm or contraction of the PM can not be excluded. Piriformis syndrome can be caused by nerve entrapment due to muscle spasm or contraction of the PM and gemellus superior muscles when the sciatic nerve passes through the gluteal region. In this case, symptoms of loss of sensation along the back of the thigh or numbness and tingling in the soles of the feet may occur [6,7]. This is similar to the symptoms of sciatica, so caution is needed in diagnosis and treatment. In particular, a variation that passes through one muscle may generate a greater force than the compression obtained between two different muscles.

Treatment methods for piriformis syndrome include cor-

rection of biomechanical factors, muscle stretching exercise, injection therapy, and surgery. In case of not responding to conservative treatment, injection therapy using local anesthetic or steroid injection is mainly applied. However, as in our case, when mCFN comes out through the PM, the possibility that the needle may invade the exit of mCFN in the PM should be considered when injecting treatment into the PM [8-10].

In this case, SN was separated into CFN and TN, and CFN was again separated into mCFN and aCFN, and mCFN showed a variation in the form of penetrating the PM. Poutoglidou et al. [11] performed a systematic review and meta-analysis of previous studies that classified the anatomical relationship with PM into 6 types when SN exits through the gluteal region. As a result, the incidence was 8% for type B, 2% for type C, and 1% for type D. However, E and F types were only 0.05% with 4 each out of 8,257 samples. Interestingly, in Asian population including China, Taiwan, and Japan, E and F types were not found at all in 987 samples. Considering the frequency of occurrence of types, it is necessary to establish new standards for classification and variation. Therefore, additional research on morphological classification targeting a large-scale Korean population is required.

In this case, the width of TN, mCFN, and aCFN were TN 7.9 mm, mCFN 3.2 mm, and aCFN 1.3 mm, respectively. In a previous study, the width of the TN was 6.42 (± 1.49) mm in males and 4.78 (± 0.84) mm in females [12]. Also, the width of CFN was 3.69 (± 0.86) mm in males and 3.12 (± 0.54) mm in females. Compared to this study, TN in our case was wider though CFN width was similar. It was not known exactly whether the difference in width was due to the branching of nerves into several branches or whether it was a race-related difference. Further studies are needed to provide a cause for this width difference.

Park et al. [4] reported a variation that SN was divided into CFN and TN, and TN passed under the inferior margin of the PM. Then, CFN penetrated the PM and ran down the branch of the inferior gluteal nerve. They argued that the nerves of the lower extremities can be isolated from each other at various levels because SNs originate from two plexuses during embryological development, and this can appear in the form of variations. Our case was also judged to be a result of these developmental characteristics, but the exact embryological mechanism could not be identified.

In conclusion, CFN originates from two slips, and mCFN,

one of main branch, exits through the PM. The gluteal region may be vulnerable to iatrogenic injury in surgical approaches, and in order to minimize such damage, the diversity of muscle and nerve types should be considered. It is judged that our case can be used as basic data for reference in such cases.

REFERENCES

1. Drake R, Drake RL, Vogl W, Mitchell AW: Gray's basic anatomy. Philadelphia: Elsevier Health Sciences; 2012.
2. Beaton LE, Anson BJ. The relation of the sciatic nerve and of its subdivisions to the piriformis muscle. *Anat Rec.* 1937; 70:1-5.
3. Sumalatha S, AS DS, Yadav JS, Mittal SK, Singh A, Kotian SR. An unorthodox innervation of the gluteus maximus muscle and other associated variations: A case report. *Australas Med J.* 2014;7:419-22.
4. Park KR, Kim MS, Lee YS, Lee JH. Complex Variations in the Course of the Sciatic Nerve and Origin of the Inferior Gluteal Nerve: A Case Report. *Anat Biol Anthropol.* 2021; 34:143-5.
5. Warner T, Iwanaga J, Loukas M, Dumont AS, Tubbs RS. Previously Unreported Sciatic Nerve Variation: Case Report. *Kurume Med J.* 2022;67:53-5.
6. Porta M. A comparative trial of botulinum toxin type A and methylprednisolone for the treatment of myofascial pain syndrome and pain from chronic muscle spasm. *Pain.* 2000; 85:101-5.
7. Robinson DR. Piriformis syndrome in relation to sciatic pain. *Am J Surg.* 1947;73:355-8.
8. Ling ZX, Kumar VP. The course of the inferior gluteal nerve in the posterior approach to the hip. *J Bone Joint Surg Br.* 2006;88:1580-3.
9. Skalak AF, McGee MF, Wu G, Bogie K. Relationship of inferior gluteal nerves and vessels: target for application of stimulation devices for the prevention of pressure ulcers in spinal cord injury. *Surg Radiol Anat.* 2008;30:41-5.
10. Windhofer C, Brenner E, Moriggl B, Papp C. Relationship between the descending branch of the inferior gluteal artery and the posterior femoral cutaneous nerve applicable to flap surgery. *Surg Radiol Anat.* 2002;24:253-7.
11. Poutoglidou F, Piagkou M, Totlis T, Tzika M, Natsis K. Sciatic Nerve Variants and the Piriformis Muscle: A Systematic Review and Meta-Analysis. *Cureus.* 2020;12:e11531.
12. Mbaka G, Osinubi A. Morphometric study of sciatic nerve and its topographic anatomical variations in relation to landmark structures around pelvis: a Nigerian population study. *Folia Morphol (Warsz).* 2020;81:44-51.