

Case Report

Eruptive xanthomas: Might be traditional hawthorn vinegar induced?

Müzeyyen Gönül^{1,*}, Seray Külcü Çakmak², Esra Özhamam²

¹*Dışkapı Yıldırım Beyazıt Education and Research Hospital, Dermatology Department, Ankara;* ²*Ankara Numune Education and Research Hospital, Dermatology Department, Ankara, Turkey*

ABSTRACT

Eruptive xanthomas that are characterized by yellowish red papules results from hyperlipidemia, particularly hypertriglyceridemia. The hyperlipidemia responsible for this disorder can be caused by a primary genetic defect, a secondary disorder, or both. Some medications such as estrogen or retinoid treatments may cause eruptive xanthomas by increasing serum lipids. We present a case eruptive xanthomas triggered by hawthorn vinegar.

Keywords eruptive xanthomas, hawthorn, hyperlipidemia

A 38-year-old man attended with papular lesions on both forearms and back. The lesions began on extensor surfaces of forearms 10 days ago, subsequently spreading to his back. The patient described mild pruritus. There was hyperlipidemia in his and his family's (his mother and uncle) medical history. He denied a family history for similar lesions. His previous levels of cholesterol and triglyceride were about 400 and 800 mg/dL respectively. He did not have history of using any drug for hyperlipidemia or another health problem. He told that he had begun to drink hawthorn vinegar 50 mL/day for three weeks. Dermatological examination showed multiple pinkish-yellow papules over the extensor aspects of forearms and the back and some of them had lobulated appearance (Figs. 1-2).

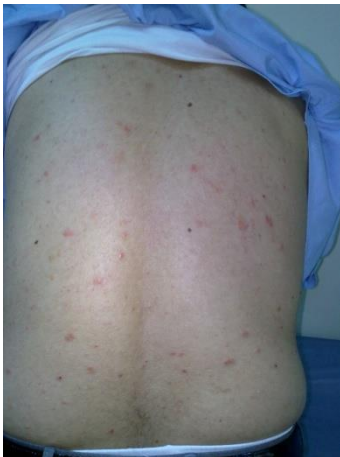

Fig. 1. Multiple yellowish papules on the back

His laboratory tests showed high levels of cholesterol (1320 mg/dL, N: < 200 mg/dL) triglyceride (8840 mg/dL N: < 200 mg/dL) and blood glucose (393 mg/dL N: 70 - 109 mg/dL). AST was 60 U/L (N: < 50U/L) ALT was 60 U/L (N: < 50U/L). Renal, and thyroid function tests and hemogram were within

normal limits. The skin biopsy revealed foamy macrophages which have an eccentric nucleus and a large amount of cytoplasm infiltrating the dermis. They were stained with CD 68 (Figs. 3-4). Eruptive xanthoma was diagnosed with clinical, laboratory and pathological findings. He was consulted to endocrinology and hawthorn vinegar was stopped and diet for hyperlipidemia and hyperglycemia was suggested. Blood glucose level decreased to normal limit and lipid levels prominently diminished and the lesions improved in 1 week with only diet. It was thought that hawthorn vinegar might have triggered the increase of lipid and glucose levels on the base on familial hyperlipidemia in this patient.

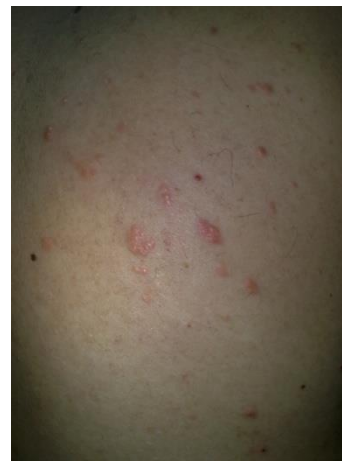

Fig. 2. Closer appearance of the papules

Hyperlipidemia is classified in 2 groups as primary form caused by genetic abnormalities and secondary form resulting from other diseases or medications such as diabetes mellitus, hypothyroidism, nephrotic syndrome, estrogen or retinoid treatments and alcohol abuse. Xanthomas are the localized lipid depositions in the skin. It is divided to 4 types as eruptive, tendinous, tuberous, and planar, by anatomical localization of the lesions and mode of development (Park et al., 2005). Eruptive xanthoma, the most common type, appears as crops of discrete yellowish papules and localizes on hands, extensor surfaces and buttocks. Early lesions may have erythematous base and associated pruritus (Henning and Fazio, 2011; Merola

*Correspondence: Müzeyyen Gönül
E-mail: muzeyyengonul@gmail.com

Received September 6, 2013; Accepted October 23, 2013; Published November 30, 2013

doi: <http://dx.doi.org/10.5667/tang.2013.0025>

© 2013 by Association of Humanitas Medicine

et al., 2008). Histopathologically, foamy macrophages with an infiltration of lymphocytes and neutrophils are present in dermis (Merola et al., 2008; Naik, 2001). Lesions usually resolve spontaneously over weeks and may result in hypertrophic scars (Naik, 2001).

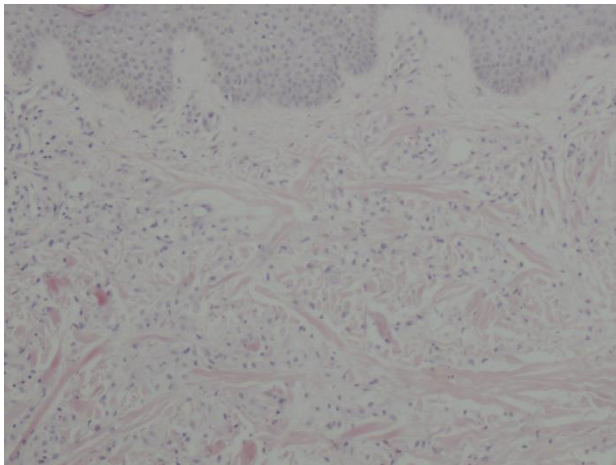


Fig. 3. Foamy macrophages which have an eccentric nucleus and a large amount of cytoplasm infiltrating the dermis (H&E x 100)

Eruptive xanthomas typically occur in patients with severe hypertriglyceridemia, increased chylomicron and increased very low density lipoprotein (VLDL) cholesterol, most commonly type V hyperlipidemia (Park et al., 2005). Also, eruptive xanthoma may develop due to the secondary hyperlipoproteinemia (Henning and Fazio, 2011; Park et al., 2005). Moreover, familial hyperlipidemia may be exacerbated by factors that may cause secondary hyperlipidemia (Park et al., 2005). The present case had familial hyperlipoproteinemia but the levels of cholesterol and triglyceride had not increased over 1000 mg per dL until he drunk hawthorn vinegar. Because of this, we think that hawthorn vinegar might have exacerbated acute increase in levels of lipids and glucose.

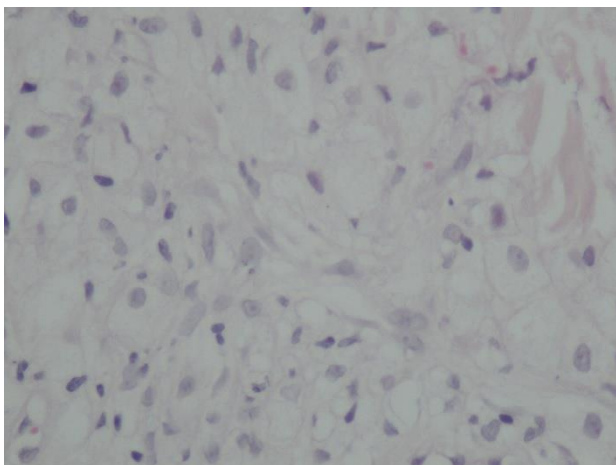


Fig. 4. Closer appearance of histopathological findings (H&E x 400)

Hawthorn, the genus *Crataegus* included more than 250 species is believed to have originated from northern temperate regions. The species are widely distributed in western Asia, North America and Europe. The wild *Crataegus* plants grow naturally in Turkey, mostly in the Aegean, East Mediterranean, Southern Anatolia and Northeast Anatolia. Hawthorn plants have a high morphological diversity, particularly in leaf, flower, and fruit characteristics (Yilmaz et al., 2010).

Hawthorn is generally used for health treatment in Turkey because of its positive effects on the cardiovascular system, atherosclerosis, arthritis and hypertension. It also cures colds, upper respiratory infection, bronchitis, pneumonia. It is believed that it is a good vitamin supplier. While its flowers consist tocopherols and ascorbic acid and fatty acids, its fruits contain carbohydrates, sugars and saturated fatty acids (Barros et al, 2011). There is no data that hawthorn causes increase in serum lipids and eruptive xanthoma. Moreover, it has been reported that hawthorn had antilipidemic effects (Lin et al, 2011). However, we thought hawthorn vinegar might have caused the increase of lipid and glucose levels because there was not any factor to explain the acute increase of lipids that were remained moderate for a long time. In literature, paradoxical side effects have been reported, for example; although infliximab and adalimumab are effective drugs in the psoriasis treatment also, they may trigger development of psoriasis with unknown mechanism (Joyau et al, 2012). We do not know how the hawthorn vinegar triggered acute hyperlipidemia and hyperglycemia in the present case. The contents of its fruits might have caused hyperglycemia and hyperlipidemia because the patient had genetic predisposition. Some new substances may stem from fermentation of fruits of hawthorn vinegar. Any unknown substance in the vinegar of hawthorn might have shown enzymatic effect that might have changed the metabolism of lipids and glucose in the present case. We do not know whether hawthorn vinegar increase lipids and glucose levels in human as there is not any knowledge about this item in the literature. This effect of hawthorn vinegar may be idiosyncratic adverse reaction in the present case.

ACKNOWLEDGEMENTS

None.

CONFLICT OF INTEREST

None to declare.

REFERENCES

- Barros L, Carvalho AM, Ferreira IC. Comparing the composition and bioactivity of *Crataegus Monogyna* flowers and fruits used in folk medicine. *Phytochem Anal.* 2011;22:181-188.
- Henning JS, Fazio MG. Yellowish papules on a middle-aged man. Eruptive xanthoma. *Am Fam Physician.* 2011;83:73-74.
- Joyau C, Veyrac G, Dixneuf V, Jolliet P. Anti-tumour necrosis factor alpha therapy and increased risk of de novo psoriasis: is it really a paradoxical side effect?. *Clin Exp Rheumatol.* 2012;30:700-706.
- Lin Y, Vermeer MA, Trautwein EA. Triterpenic Acids Present in Hawthorn Lower Plasma Cholesterol by Inhibiting Intestinal ACAT Activity in Hamsters. *Evid Based Complement Alternat Med.* 2011;8:9.
- Merola JF, Mengden SJ, Soldano A, Rosenman K. Eruptive xanthomas. *Dermatol Online J.* 2008;14:10.
- Naik NS. Eruptive xanthomas. *Dermatol Online J.* 2001;7:11.

Park JR, Jung TS, Jung JH, Lee GW, Kim MA, Park KJ, Kim DR, Chang SH, Chung SI, Hahm JR. A case of hypothyroidism and type 2 diabetes associated with type V hyperlipoproteinemia and eruptive xanthomas. *J Korean Med Sci.* 2005;20:502-505.

Yilmaz KU, Yanar M, Ercisli S, Sahiner H, Taskin T, Zengin Y. Genetic relationship among some hawthorn (*Crataegus* spp.) species and genotypes. *Biochem Genet.* 2010;48:873-878.