

Case Report

Clinical Effectiveness of a Unani Regimen in the Management of *Hasāh al-kuliya* (Nephrolithiasis): A Case Report

Ifra Abdul Qaiyyum¹, Mohammad Nawab^{2*}

¹Research Scholar, ²*Reader, Department of Moalajat (Medicine), National Research Institute of Unani Medicine for Skin Disorders, Erragadda, Hyderabad, Telangana, India

ABSTRACT

Hasāh al-kuliya (Nephrolithiasis) is a common disease with a worldwide prevalence of about 12%. A 64 years old male patient, who visited the outpatient department of National Research Institute of Unani Medicine for Skin Disorder (NRIUMSD), Hyderabad, presented with complaints of mild dull pain in right flank region and burning micturition for one month. The ultrasonography of whole abdomen confirmed that there was one stone of 5 mm in calyceal region of each kidney. The patient was treated with the Unani regimen comprising of three formulations Majoon, Hajrul Yahood (5 gm), Jawarish Zarooni Sada (5 gm) and Habb-i-Mudir (1000 mg) for 6 months. The patient did not report any acute pain during the therapy. After 6 months of treatment the ultrasonography of whole abdomen showed absence of the stone from each kidney, ureters and bladder. There was no recurrence of the disease during next 6 months of post treatment follow up. This case report documented the successful medical treatment and prevention of recurrence of bilateral nephrolithiasis through Unani medicines. It concluded that the Unani regimen was effective and safe in the management of bilateral nephrolithiasis.

Keywords *Hasāh al-kuliya*, Majoon Hazrul Yahood, Nephrolithiasis, Renal Stone, Unani medicine.

INTRODUCTION

Hasāh al-kuliya (Nephrolithiasis) is a common clinical condition affecting around 12% of world population (Aleign & Petros, 2018). The trends of rising prevalence and recurrence rates of this disease has been reported in the literature (Knoll, 2010; Soni, Saboo, Bhansali, & Barnela, 2012). In Indian population, about 12% of them are expected to have urinary stones and out of which 50% may end up with loss of kidney functions (Joseph, Parekh, & Joshi, 2005). It occurs more frequently in male than female. The multiple risk factors which help in genesis of kidney stones have been identified. Medieval literature describes several hypotheses for formation of renal stones. Majusi, a renowned Unani stalwart explained that the *khilt ghaliz* (viscous humour) such as phlegm, pus and viscous blood gets concentrated by intense innate energy of the body and solidify into stone (Mohammed Tabarak Hussain, Ahmed, Jahan, & Adiba, 2016; Al Majusi, 1889). But Galen hypothesized that the gaseous matter trapped in spaces of the kidneys consolidates into stones. Sometimes ulceration inside the kidney and urinary tract causes pus to accumulate and solidify into renal stones. A nidus formation in renal tract and kidneys also helps in stone formation (Mohammed Tabarak Hussain et al., 2016).

Hasāh al-kuliya is a systemic disorder linked to the metabolic syndrome. It has been associated with an increased risk of chronic kidney diseases, end-stage renal failure,

cardiovascular diseases, diabetes mellitus and hypertension (Aleign & Petros, 2018). It is a preventable and curable disease. Pharmacological treatment has several limitations. Renal stones of <5 mm passes spontaneously in 90% cases. Urological intervention is required in 95% cases where stone is larger than 8 mm (Portis & Sundaram, 2001). Calyceal and pelvic stones can be managed by surgical intervention. The recurrence rate of this disease is about 50% (Butterweck & Khan, 2009).

Patient information

A 64 years old male patient who visited outpatient department of National Research Institute of Unani Medicine for Skin Disorders, Hyderabad on 9th May, 2019 with complaints of mild pain in right flank region and burning micturition for one month. The pain was localized, infrequent and dull in nature which alleviated after taking analgesic drug. There was no radiation of pain and association with muscular movement. Frequency of micturition (6-7 times during day and once at night) was slightly increases with mild burning sensation. There was no past history of renal stone, diabetes mellitus and hyperparathyroidism. But he had past history of hypertension (stage-I). There was no history of renal stone in his family. He was a grocer, married and non-vegetarian. He had no addiction of alcoholism, pan chewing, smoking and sleeping pill. In treatment history he had been taking oral Telmisartan 40 mg once daily since last two year. The patient signed the informed consent form for publication of this report.

General examination

The patient was alert, oriented and apparently healthy. The built of the patient was average (Height: 1.67 m: Weight: 65 kg, BMI: 23 kg/m²) There were no pallor, icterus and palpable lymph nodes. The vitals were stable (Pulse: 78/minute, Temperature:

*Correspondence: Mohammad Nawab

E-mail: ccrumnawab@gmail.com

Received June 27, 2020; Accepted July 17, 2020; Published Aug 31, 2020

doi: <http://dx.doi.org/10.5667/CellMed.2020.0023>

©2020 by CellMed Orthocellular Medicine Pharmaceutical Association

This is an open access article under the CC BY-NC license.

(<http://creativecommons.org/licenses/by-nc/3.0/>)

97.8°F, Respiratory Rate: 16/minute: Systolic Blood Pressure: 138 mmHg and Diastolic Blood Pressure: 84 mmHg) at baseline. Cardio-vascular, respiratory and nervous systems were normal at base line.

Examination of Genito-urinary system

The genitalia were normal in shape, size and structure. There was circumcised penis with urinary meatus at normal site. Reducible swelling on left side of scrotum i.e, left inguinal hernia was present. There were no sign of hydrocele, varicocele and hypogonadism. On physical examination of whole abdomen, it was observed that the shape of abdomen was scaphoid. The umbilicus was central and inverted. There was no scar mark on the abdomen. Mild tenderness was present on suprapubic region but there was no tenderness at renal angles. Liver, spleen and kidneys were not palpable. Any other palpable lump was not present in the abdomen and pelvis. Inguinal lymph nodes were not palpable, too.

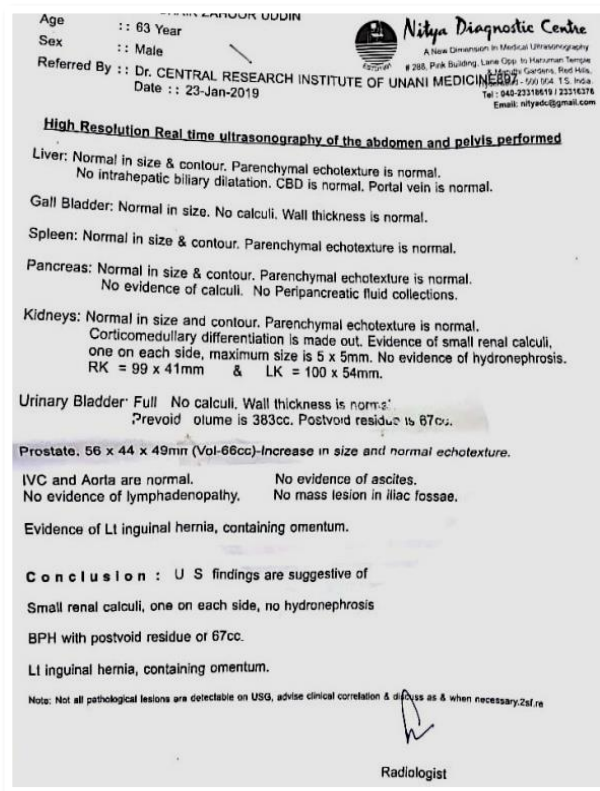
Investigations

The patient was diagnosed on the basis of ultrasonography (USG) of whole abdomen. The legend 1 is the report of the high resolution and real time USG of whole abdomen and pelvis done on 23/01/19 before start of the treatment. This report confirmed that there was one stone of 5x5 mm in each kidney and the prostate gland was enlarged (56x44x49 mm) with post void residue of 67 cc. Figures 1 and 2 shows that there are echogenic shadows confirming the presence of stones in each kidney. The findings of the USG also suggested that left inguinal hernia containing omentum was present. The urinalysis revealed that the urine was acidic in nature. 2-3 pus cells and a few crystals of calcium oxalate were present in the urine at baseline. But there was no RBC in the urine. Serum creatinine, blood urea nitrogen and fasting serum glucose were within normal limits. The investigations USG (whole abdomen), urinalysis, Liver Function Test, Haemogram, Kidney Function Test and Fasting Serum Glucose were performed at base-line, 3 months and post treatment (6 months). Their values at baseline and post treatment are given in table 4.

Intervention and follow up

The treatment of patient was started on 31st January, 2020. The Unani regimen containing three formulations Majoon Hajrul Yahood (MHY) in the dosage of 5 grams twice daily, Jawarish Zarooni Sada (JZS) with the dose of 5 grams twice daily and Habb-i- Mudir (HM) in the dose of 1000 mg twice daily was prescribed orally after half an hour of meals. MHY is a Unani pharmacopoeial formulation used in clinical practice for the treatment of *hasat-ul-kulya* (nephrolithiasis), *harqat-ul-baul* (burning micturition), *qillat-e-baul* (oliguria) and *hasat-e-masana* (vesical calculus) (Anonymous, 2006). The composition of MHY is given in table-1. JZS is another pharmacopoeial formulation to treat clinical conditions such as *Zof-e-kulya* (renal insufficiency), *hasat-ul-kulya* (nephrolithiasis), *hasat-e-masana* (vesical calculus) and *waja-ul kulya* (renal pain) (Anonymous, 2006). Table -2 describes the composition of JZS. The formulation HM is also a pharmacopoeial one indicated in *ehtebas-e-tams* (ammenorrhoea) and *qillat-e-baul* (oliguria) (Anonymous, 2006). The patient was a known case of hypertension, benign prostate hypertrophy and left inguinal hernia. He was regularly taking Telmisartan 40 mg once daily to control hypertension. The patient was followed up every 14 days to monitor his health condition for 6 months. The patient was supplied medicines from the dispensary of the hospital every 14 days to observe compliance to the therapy.

Legend 1. The findings of USG (whole abdomen) at base line



Legend 2. The finding of USG (whole abdomen) at post treatment.

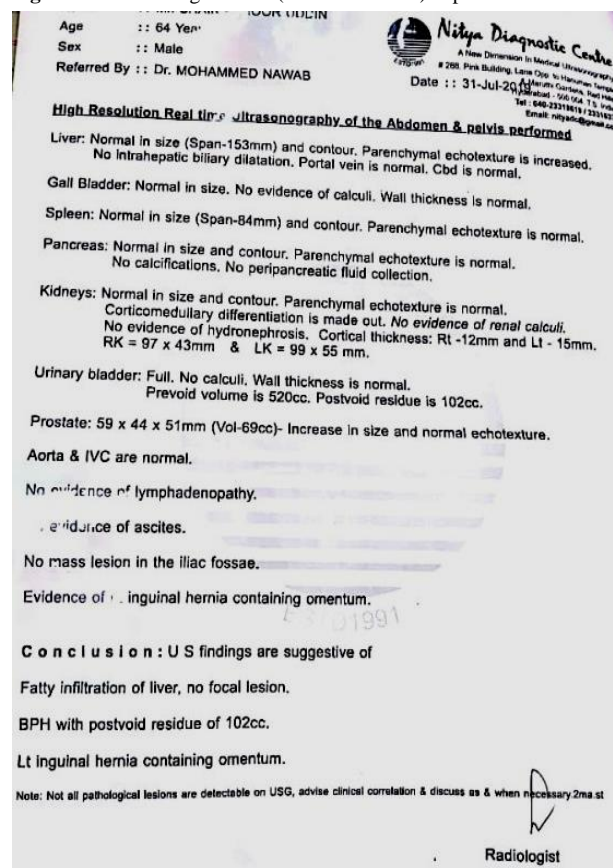

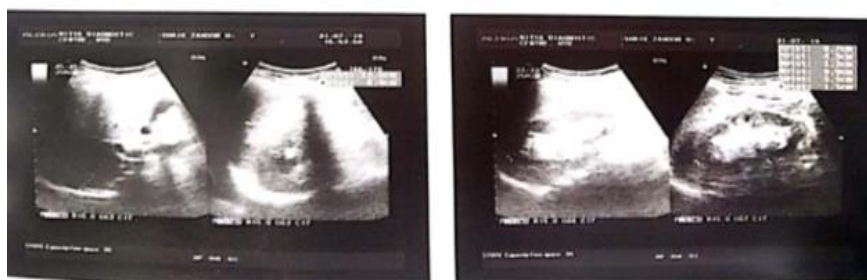


Fig. 1 & 2 USG (Kidneys) showing echo-genic shadows at baseline

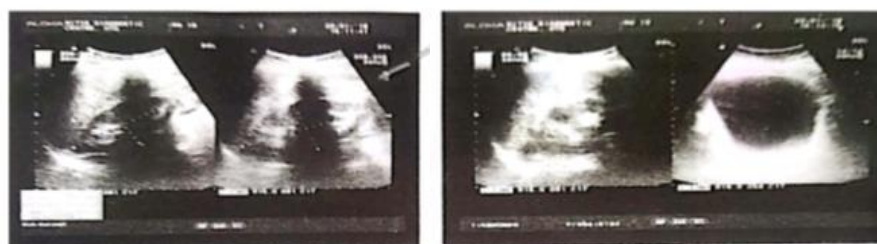

Fig. 3 & 4 USG (Kidneys) showing normal echo-texture of kidney at post treatment

Observations and Outcomes

It was observed that the patient had the complaints of mild flank pain and burning micturition at base line which improved after 14 days of treatment at first follow up. The patient remained asymptomatic after 14 days of treatment till end of the treatment and post treatment follow up period of 6 months. The vitals of the patient remained stable during course of observation and treatment. There was no episode of acute renal colic. The patient did not report any fever, nausea, vomiting and pain in abdomen. After 6 months of treatment, USG (whole abdomen and pelvis) report as mentioned in legend 2 confirmed that no stone was seen in both kidneys and urinary tract. The size of kidneys and their echo-texture were normal as shown in figures-3 & 4. But the prostate gland was enlarged (59x44x51 mm) with normal echo-texture. Left inguinal hernia containing omentum was also present. The kidney function (serum creatinine and blood urea nitrogen), liver function profile (SGOT, SGPT, Serum Alkaline Phosphatase, Serum bilirubin) and fasting serum glucose at base line and post treatment were within normal limits as shown in table-4. It was also observed that there no adverse drug reaction during the treatment period.

Table 1. Composition of the Majoon Hajrul Yahood (Anonymous, 2006)

S.No	Majoon-e-Hajrul Yahood	Quantity
1	Hajr-ul-yahood (<i>Fossil Encrinata</i>)	100 gm
2	Anisoon (<i>Pimpinella anisum</i>)	10 gm
3	Asaroon (<i>Asarum europeum</i>)	10 gm
4	Magz-i-Tukhme kharbuza (<i>Cucumis melo</i>)	10 gm
5	Tukhm-i-Karafs (<i>Apium graveolens</i>)	10 gm
6	Kaknaj (<i>Physalis alkekengi</i>)	10 gm
7	Magz-i-Tukhme Khiyar (<i>Cucumis sativa</i> Linn)	10 gm
8	Magz-i-Tukhme Kaddu (<i>Cucurbita moschata</i>)	10 gm
9	Magz-i-Tukhme Qurtum (<i>Carthamus tinctorius</i>)	10 gm
10	Magz-i-Tukhme Tarbooz (<i>Citrullus lanatus</i>)	10 gm
11	Tukhme-i-Gazar (<i>Daucus carota</i>)	10 gm
12	Qand (<i>sugar</i>)	600gm

Table 2. Composition of the Jawarish Zarooni Sada (Anonymous, 2006)

S. No	Jawarish-e-Zarooni Sada	Quantity
1	Qaranful (<i>Syzygium aromatic</i>)	30 gm
2	Tukhm-i- Karafs (<i>Apium graveolens</i>)	30 gm
3	Magz-i-Tukhme kharbuza (<i>Cucumis melo</i>)	30 gm
4	Zafran (<i>Crocus sativa</i>)	10 gm
5	Post-i-Bekh-i-Karafs (<i>Apium graveolens</i>)	30 gm
6	Aqarqarha (<i>Anocylus pyrethrum</i>)	10 gm
7	Ood-i-Hindi (<i>Aquilaria agallocha</i>)	10 gm
8	Tukhm-i-Aspand (<i>Peganum hermala</i>)	
9	Filfil Siyah (<i>Piper nigrum</i>)	30 gm
10	Tukhme-i-Gzar (<i>Daucus carota</i>)	30 gm
11	Badiyan (<i>Foeniculum vulgare</i>)	30 gm
12	Bisbasa (<i>Myristica fragrans</i>)	10 gm
13	Darchini (<i>Cinnamomum zeylanicum</i>)	10 gm
14	Mastagi (<i>Pistacia lentiscus</i>)	10 gm
15	Nankhwah (<i>Trachyspermum ammi</i>)	30 gm
16	Qand (<i>sugar</i>)	1 kg

Table 3. Composition of the Habb-i-Mudir (Anonymous, 2006)

S.No	Habb-i-Mudir	Quantity
1	Sibr (<i>Aole barbadensis</i>)	2 gm
2	Zafran (<i>Crocus sativa</i>)	1gm
3	Hirakasis (Green Vitrol; Ferous Sulphate)	1gm

Table 4. Effect of the Unani Regimen on Haematological, Biochemical and Urinalysis Parameters

S.No	Investigation	Baseline	Post Treatment
1.	Haemoglobin	14.6 gm/dl	15.6 gm/dl
2.	RBC	5.3 Million/ cu.mm	5.4 Million/ cu.mm
3.	WBC	5900/cu.mm	7200/cu.mm,
4.	Platelets	2.5 lakh/ cu.mm	2.5 lakh/ cu.mm
5.	Neutrophil	48%	50%
6.	Lymphocyte	48%	45%
7.	Eosinophil	02%	03%
8.	Monocyte	02%	02%
9.	Basophil	0	00
10.	ESR 1 st hour	10 mm	12 mm
11.	ESR 2 nd hour	22 mm	24 mm
12.	Fasting plasma glucose	94 mg/dl	109 mg/dl
13.	Blood Urea Nitrogen	11.2 mg/dl	10.8 mg/dl
14.	Serum Creatinine	1.0 mg/dl	1.1 mg/dl
15.	Serum bilirubin	1.36 mg/dl	1.26 mg/dl
16.	Serum Alanine Amino Transferase (SGPT)	19 IU/L	25 IU/L
17.	Serum Aspartate Amino Transferase (SGOT)	17 IU/L	32 IU/L
18.	Serum Alkaline Phosphatase	86 IU/L	64 IU/L
19.	Urine PH	Acidic	Acidic
20.	Urine :Pus cell	2-3/HPF	1-2/HPF
21.	Urine: crystals	A FEW	NIL

DISCUSSION

In this case report, it was observed that the Unani regimen comprising of three formulations MHY, JZS and HM was effective and safe in the management of bilateral nephrolithiasis. This Unani regimen was formulated keeping in mind the principles of treatment for nephrolithiasis as per therapeutic approach of Unani System of Medicine. Lithotriptic, nephroprotective and diuretic drugs are used for the management of nephrolithiasis. The pathogenesis of renal stone formation is incompletely understood (Alelign & Petros, 2018). The effectiveness of the Unani regimen in this case might be explained in terms of pharmacological actions of the formulations in the regimen. MHY, a compound herbo-mineral formulation, has diuretic and lithotriptic properties (Arzani, 2009; Anonymous 2006; Makbul, Jahan, & Ahmad, 2018)). It is hypothesized that MHY prevents the crystallization process and supersaturation of urine which ultimately helps to get dissolved renal stones in urine and in this way pass out of the urinary tract. The formulation JZS is best known nephroprotective and diuretic drug that keeps the function of the kidneys to normal (Anonymous, 2006). In a preclinical study, JZS showed significant diuretic, natriuretic and kaliuretic effects. The study demonstrated that diuretic effect of JZS can be compared with the known diuretic furosemide. The study also revealed that JZS possess nephroprotective effect against GM-induced nephrotoxicity (Afzal, Khan, Ghufraan, Iqbal, & Inamuddin, 2004). The diuretic, natriuretic, kaliuretic and nephroprotective potential of JZS may prevent supersaturation of urine and crystal

formation in kidneys and urinary tract which allow the kidney stone to get dissolve in urine. These properties of JZS may also reduce the chance of reformation of stones in kidney and urinary tract. In this way recurrence of renal stones could be minimized. The formulation HM is also an effective diuretic (Arzani, 2009; Anonymous, 1993). It helps in diuresis and increases the production of urine. Low urine output is also one of the risk factor for stone formation (Alelign & Petros, 2018). The diuretic action of HM prevents stone formation in urinary tract. Renal stone is linked with metabolic disorders, dietary habits and life style of the individual (Knoll, 2010). In this case any metabolic disorder was not apparently present. In other words it may be said that we could not ascertain the exact cause or risk factor of nephrolithiasis in this patient. Dietary modification such as high protein and mineral diet was restricted during the treatment and post follow up period to get early treatment effect and to check recurrence of the disease as it has been established that high protein diet has significant role in formation of uric acid renal stone (Alelign & Petros, 2018). Any life style modification was not suggested. Extensive investigation to find out the probable risk factor(s) in this case was not required. Because, Past history and recurrence of nephrolithiasis during follow up were not reported. It may be hypothesized that the treatment effect of the Unani regimen may hamper reformation of stone in the kidney. The literature says that proper medication may reduce the chances of recurrence of nephrolithiasis (Alelign & Petros, 2018; Worcester & Coe, 2008).

The Unani regimen was found safe as there was no report of adverse drug reaction during the course of the therapy. Liver and kidney functions were within normal limit at base line and post treatment.

CONCLUSION

Hasāh al-kuliya is a common ailment in urinary diseases. It is considered as a self-limiting disease and treated by surgical intervention and laser lithotripsy. Medical treatment has many limitations. There are serious complications of nephrolithiasis such as hydronephrosis and renal failure. Recurrence of this disease is also very common. In the given situations, the claims of traditional medicine for successful medical therapy of nephrolithiasis are to be scientifically documented. This case report is one of such documents which reveal that Unani regimen comprising of three formulations was safe and effective in the management of bilateral nephrolithiasis, a complicated medical condition where chance of recurrence is quite high. This report also highlights the potential of the Unani medicine in health care. This case report may also draw the attention of Unani practitioners, researchers and policy makers to do extensive research in the areas of nephrolithiasis.

CONFLICT OF INTEREST

Authors declared that there was no conflict of interest.

ACKNOWLEDGEMENT

Authors are thankful to Prof. Munawwar Husain Kazmi, Director In-charge, National Research Institute of Unani Medicine for Skin Disorders, Hyderabad for his kind co-operation, encouragement and patronage.

REFERENCES

Afzal M, Khan NA, Ghufraan A, Iqbal A, & Inamuddin M. Diuretic and nephroprotective effect of Jawarish Zarooni Sada - A polyherbal unani formulation. *Journal of Ethnopharmacology*, 2004;91(2-3);219-223.

Alelign T & Petros B. Kidney Stone Disease: An Update on Current Concepts. *Advances in Urology*, 2018.

Al-Majūsī. Ibn ‘Abbās. Tarjumā-i Kāmilus Sanā’ (Urdu Trans. by Ghulam Hussain Kantoori), Vol. 1&2. 1889

Anonymous, National Formulary of Unani Medicine, part-1, (New Delhi, India; Central Council for Research in Unani Medicine), pp.24, 106, 127, 2006.

Arzani AM. Qarabadeen-e-qadri, (New Delhi, India; Council for Research in Unani Medicine), pp.517, 2009

Butterweck V & Khan SR. Herbal medicines in the management of urolithiasis: Alternative or complementary? *Planta Medica*, 2009;75(10);1095-1103.

Joseph KC, Parekh BB & Joshi MJ. Inhibition of growth of urinary type calcium hydrogen phosphate dihydrate crystals by tartaric acid and tamarind. *Current Science*, 2005;88(8);1232-1238.

Knoll T. Epidemiology, pathogenesis, and pathophysiology of urolithiasis. *European Urology, Supplements*, 2010;9(12);802-806.

Makbul SAA, Jahan N & Ahmad G. Hajrul yahood (Lapis judaicus): An important mineral drug of Unani system of medicine for the management of urolithiasis. *Journal of Ethnopharmacology*, 2018;222;165-170.

Mohammed Tabarak Hussain I, Ahmed G, Jahan N & Adiba M. Pathophysiology and Treatment of Urolithiasis in Unani Medicine. *Indian Journal of History of Science*, 2016; 51(2).

Portis AJ & Sundaram CP. Diagnosis and initial management of kidney stones. *American Family Physician*, 2001;63(7);1329-1338.

Soni S, Saboo S, Bhansali A & Barnela S. Medical management of renal stone. *Indian Journal of Endocrinology and Metabolism*, 2012;16(2);236.

Worcester EM & Coe FL. Nephrolithiasis. *Primary Care - Clinics in Office Practice*, 2008;35(2);369-391.