

## 세포교정영양요법(OCNT)을 이용한 주부 습진 환자 사례 연구

조종빈 약사

전라남도 화순군 화순읍 자치샘로 42-2 화순종로약국

## A Case Study of Ortho-Cellular Nutrition Therapy (OCNT) in a Patient with Hand Eczema

Pharmacist, Jongbin Jo

Hwasun Jongro Pharmacy, 42-2, Jachisaem-ro, Hwasun-eup, Hwasun-gun, Jeollanam-do, Republic of Korea

### ABSTRACT

**Objective:** A case report on the improvement of hand eczema through Ortho-Cellular Nutrition Therapy

**Methods:** Two years of repeated improvement and worsening of hand eczema in a 68-year-old Korean woman resulted in pain and decreased quality of life.

**Results:** After nutritional therapy, hand eczema improved.

**Conclusion:** Nutritional therapy can help patients with chronic hand eczema improve inflammation, itching, depression, and insomnia.

**Keywords** Ortho-Cellular Nutrition Therapy (OCNT), hand eczema

### Introduction

Hand eczema is eczema that affects the hand. Synonymous with dermatitis, eczema is characterized by a variety of symptoms, including erythema, papules, blisters, infiltrates, scales, and cracks.<sup>1</sup> In addition, patients experience interpersonal difficulties due to

psychological causes, as well as pain or disease-specific symptoms, or have problems such as depression and sleep disorders, resulting in a decline in quality of life. Approximately one-third of all skin diseases are eczema, and among them, hand eczema is a very common disease that affects 2% to 10% of the general population.<sup>2</sup> More than 80% of hand eczema is occupationally induced, and it is classified as either acute or chronic.

Patients with eczema undergo basic lifestyle adjustments to reduce hand irritation factors, topical treatments including skin moisturizers, topical steroids, and immunosuppressants, and systemic treatments including antihistamines.<sup>3</sup> In the early stages, many patients with hand eczema do not actively treat it, resulting in chronic disease. Due to the fact that patients with chronic hand eczema develop tolerance to topical treatments or

\*Correspondence: Jongbin Jo

**Received** Jan 31, 2023; **Accepted** Jan 31, 2023; **Published** Jan 31, 2023

doi: <http://dx.doi.org/10.5667/CellMed.spc.006>

©2023 by CellMed Orthocellular Medicine Pharmaceutical Association

This is an open access article under the CC BY-NC license.

(<http://creativecommons.org/licenses/by-nc/3.0/>)

† This report has been translated and edited by the CellMed editor-in-chief, Prof. Beom-Jin Lee.

experience side effects from long-term immunosuppressant use, safe and effective treatments are required for the treatment of patients with chronic hand eczema. In the case of this study, a patient observed to have hand eczema received nutrition therapy, and the results are reported.

## Case

### 1. Subject

The subject was a patient diagnosed with hand eczema.

**1) Name:** Ahn O O (F/68)

**2) Diagnosis:** Eczema (suspected symptom of pompholyx)

**3) Onset Date:** Autumn, 2020

**4) Treatment Period:** Sept. 22, 2022 - Present

**5) Main symptoms:** Pruritus, redness, pain, inflammation

**6) History:** Taking rheumatologist-prescribed medications for joint pain, caused by an underlying disease.

**7) Social History:** No cigarette or alcohol use. The patient adheres to a healthy diet.

**8) Family history:** The patient remembers her father as having hot dry skin.

**9) Present Illness and Medication:** The patient's eczema has been treated for two years at a dermatology and oriental clinic, but the skin condition fluctuates between improvement and deterioration. She had previously treated her hand eczema with topical steroids and antihistamines, but she visited a pharmacy to try nutritional therapy due to recurrent eczema outbreaks.

### 2. Method

#### <Nutritional Therapy>

##### - Primary Nutritional Therapy

Nutritional therapy was started with Cyaplex X Granule 101, Hwapyeongwon Granule 101, Licoplex 101, diverol 101, together with external application of Cyaplex Balm and hydro cream.

##### - Secondary Nutritional Therapy

Nutritional therapy was started with Cyaplex Granule 101, Eufaplex Sticks 101, Hwapyeongwon Granule 101, and Licoplex 101, together with external application of CyaBalm, glycyrrhizin lotion, and Cyaplex scalp revitalizing shampoo.

#### <Symptoms Score>

According to the EASI (Eczema Area and Severity Index) score, the number of items was reduced to four, and the patient's symptoms were expressed as a score according to date. Four items were evaluated: redness, inflammation, itching, anxiety, and insomnia. Each item was scored from 1 to 5 points, and as the score approaches 5, the severity increases.

#### Results

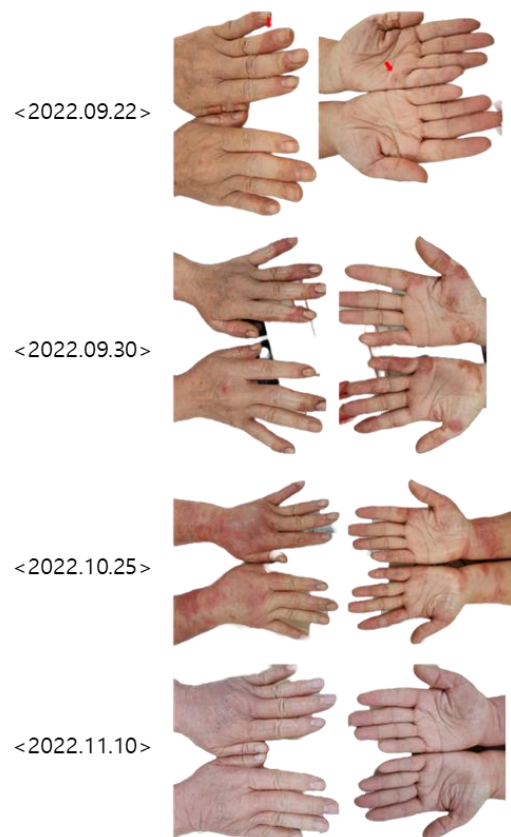
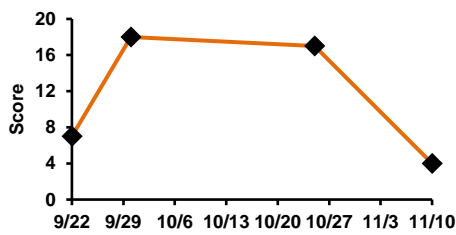


Figure 1. Changes in eczema over time before and after nutritional therapy



**Figure 2. Symptom score before and after nutritional therapy.**

The patient visited a pharmacy while receiving treatment for hand eczema for two years with ongoing dermatitis with repeated improvement and exacerbation. At the time of the visit, the prescribed use of external corticosteroids and antihistamines had severely diminished the patient's quality of life, and there was eczema with dark red skin at the fingertips and chronic keratinized dermatitis at the palm margins. **(Fig 1)**. Eight days after the primary nutritional therapy, the patient's eczema became more severe than it had been prior to treatment, and she complained of anxiety and discomfort regarding the possibility of side effects. Due to the fact that she began dying her hair in her twenties, her forehead and face were severely swollen. On 22.10.19, the second nutritional therapy with a slightly altered composition was initiated, and 5 days after taking an additional dose of Eufaplex, which repairs damaged cell membranes, the redness of the skin progressed to the point where ooze dripped from the back of the hand. **(Fig 1, Fig 2)** As the skin flare-up progressed, the patient pondered whether to seek dermatological treatment again, but determined that she could not live the rest of her life with dermatitis, so she decided to continue nutritional therapy. **(Fig 2)** Currently, the condition on the fingers and palms has improved, while the wrist region is being corrected and the skin is maintained in a healthy state.

### Discussion

Hand eczema is a disease that significantly diminishes

patients' quality of life due to mental and social factors such as depression and anxiety, in addition to inflammation-induced itching and pain. Due to two years of repeated hand eczema, the patient in this case suffered from eczema accompanied by dark red pigmentation on the fingertips and hyperkeratosis on the edge of the palm, as well as anxiety and insomnia. This case's nutritional therapy was based on Cyaplex and improved immunity and inflammation by enhancing intracellular toxin detoxification and blood circulation. <sup>4</sup>Cyaplex Balm, hydro cream, and glycyrrhizin lotion hydrated the skin, supplied eczema skin with nutrients, and soothed skin irritation. Unlike symptomatic therapies derived from chemicals used to treat modern diseases, nutritional therapy derived from food is beneficial to patients suffering from physical and mental suffering; therefore, this report was obtained with the patient's permission.

### References

- 1 Lee, J., Lee, M.-j. & Hwang, M.-w. A Clinical Case Report of Soeumin Patient with Chronic Hand Eczema. *Journal of Sasang Constitutional Medicine* **33**, 161-170 (2021).
- 2 Elston, D. M., Ahmed, D. D., Watsky, K. L. & Schwarzenberger, K. Hand dermatitis. *Journal of the American Academy of Dermatology* **47**, 291-299 (2002).
- 3 Lee, G. R., Maarouf, M., Hendricks, A. K., Lee, D. E. & Shi, V. Y. Current and emerging therapies for hand eczema. *Dermatologic Therapy* **32**, e12840 (2019).
- 4 Lee, J. Y. *et al.* Anthocyanin-fucoidan nanocomplex for preventing carcinogen induced cancer: Enhanced absorption and stability. *International Journal of Pharmaceutics* **586**, 119597 (2020).