

Protective effects of Hydro-alcoholic extract of the roots of *Kasondi* (*Cassia occidentalis* L.) against gentamicin-induced nephrotoxicity in albino Wistar rats

Jwariya Shamim¹, Athar Parvez Ansari^{2*}, Pankaj Goswami³, Seema Akbar¹, Huzaifa Ansari¹, Abdul Wadud⁴, Pervaiz Ahmad Dar⁵

¹Regional Research Institute of Unani Medicine, Srinagar, Jammu & Kashmir (NABH Accredited), CCRUM, Ministry of AYUSH, Govt. of India, ^{2*}Regional Research Institute of Unani Medicine, Chennai, Tamil Nadu (NABH Accredited), CCRUM, Ministry of AYUSH, Govt. of India, ³Division of Veterinary Pathology, Sher-e-Kashmir University of Agriculture Sciences and Technology of Kashmir, R. S. Pura, Jammu, India, ⁴National Institute of Unani Medicine, Bangalore, Ministry of AYUSH, Govt. of India, ⁵Department of AYUSH, Jammu & Kashmir, India

ABSTRACT

Objectives:

Cassia occidentalis L. is a weed belonging to the Caesalpiniaceae family. The root of this medicinal plant is used for the treatment of various ailments, including kidney diseases. The present study was aimed at evaluating the nephroprotective effects of HAE of the roots of *Cassia occidentalis* L. against gentamicin-induced renal toxicity in albino Wistar rats.

Methods:

The renal toxicity was induced by subcutaneous administration of gentamicin at 100 mg/kg in the rats belonging to the disease control and treatment groups from the 4th to the 8th day. The rats in the treatment group received HAE of the roots of *Cassia occidentalis* L. at 67 mg/kg b. w. orally for 8 days, while no treatment was given to the rats in the disease control and plain control groups. At the end of the experiment, renal biomarkers viz; s. creatinine, b. urea, and s. uric acid, were investigated. The histopathological examination of the kidney specimens was also carried out.

Results:

The results of the present study revealed that renal function biomarkers such as s. creatinine, b. urea, and s. uric acid were significantly reduced in the rats of the treatment group as compared to those of the disease control group. Moreover, the histoarchitecture reports of the treatment group's kidney specimens showed significant improvements.

Conclusion:

The results suggested that the HAE of *Cassia occidentalis* L. roots promisingly prevented kidney injury in gentamicin-induced nephrotoxic rats. This effect might be due to improved clearance of gentamicin from the renal tubule and decreased generation of reactive oxygen species (ROS).

Keywords: *Kasondi*; *Cassia occidentalis*; Gentamicin-induced nephrotoxicity; Nephroprotective; Unani medicine

Abbreviations:

AKI: Acute kidney injury; ANOVA: Analysis of variance; ARF: Acute renal failure; CBT: Centre for Biodiversity and Taxonomy; CPCSEA: Committee for the Purpose of Control and Supervision of Experiments on Animals; DSRU: Drug Standardization Research Unit; HAE: Hydro-alcoholic extract; HP: Himachal Pradesh; IAEC: Institutional Animal Ethics Committee; IIM: Indian Institute of Integrative Medicine; i. p: intraperitoneal; RNS: reactive nitrogen species; ROS: reactive oxygen species; rpm: Resolutions per minute; RRIUM: Regional Research Institute of Unani Medicine; SEM: Standard Error of Mean.

INTRODUCTION

Earlier, acute kidney injury (AKI) was named acute renal failure (ARF)¹, a disease in which the renal function is abruptly impaired² due to a rapid reduction in the glomerular filtration rate³ and severe tubular damage.² This condition is manifested by an increased level of urea and creatinine in the blood, oliguria, or both.^{1,3} The etiological factors of AKI are infections, septicemia, nephrotoxic drugs, failure of renal cell repair², surgery, trauma, heart diseases, acute glomerulonephritis⁴, ischemia, hypoxia, etc.⁵ Studies have reported that during the last 50 years, the mortality rate due to AKI has been found to be higher than that due to diabetes, heart failure, and breast cancer. This higher prevalence might be due to either community or hospital-related infections.⁴ Another report revealed that nearly 20% of AKI cases in hospitalized patients are associated with serious complications like electrolyte imbalance, volume overload, uremic disorders, etc.³, and are further responsible for the deaths of 9.5% of patients.² Moreover, some recent epidemiological studies have reported that the incidence of AKI has dramatically increased, particularly in hospitalized patients. The data obtained from 49 million hospitalized patients suffering from acute diseases has suggested that one in five adults and one in three children are more susceptible to developing acute kidney injury.⁶ In the present scenario, the nephrotoxicity caused by pharmaceutical agents is considered a major challenge for medical practice, hence, their misuse or overuse may be avoidable.⁷ In this regard, gentamicin, which belongs to the aminoglycoside group of antimicrobial agents, is more responsible for producing renal toxicities. After the invention of many newer, highly efficacious antibiotics, gentamicin is still preferred, especially by clinicians in developing countries, to treat several infectious diseases⁸ owing to its availability, cost-effectiveness, and potential nature.⁹ Around 3-5% of the concentration of gentamicin is reabsorbed through cells of the proximal tubules of the kidney following its administration and is responsible for necrosis, particularly in the S1 and S2 segments.⁸ Some studies have reported that such necrosis is caused by over-production of reactive oxygen species (ROS), reactive nitrogen species (RNS), low concentration of antioxidant enzymes, induced inflammatory pathway, and decreased blood supply to the kidney. Hence, it is clear that nearly 30% of gentamicin users develop renal failure.⁹

In the Unani system of medicine, renal failure or renal insufficiency is referred to as *du'f al-kulya*¹⁰, which is treated by using *muqawwī-i-gurda* (nephroprotective) drugs. According to the Unani concept, the kidney has four faculties viz; (i) *quwwat-i-hādima* (digestive faculty), (ii) *quwwat-i-jādhība* (absorptive faculty), (iii) *quwwat-i-māsika* (retentive

faculty), and (iv) *quwwat-i-dāfi'a* (expulsive faculty). These faculties play an important role in the normal functioning of the kidney. A derangement in any one of these faculties is responsible for renal diseases.¹¹ Ibn Sina (980-1037 AD), a versatile Unani scholar, stated that *muqawwī* drugs (tonics) maintain the homeostasis of all the vital organs of the body, including the kidney.¹² Moreover, drugs used in the treatment of kidney diseases should have the potential to strengthen all the above mentioned faculties.¹¹ *Kasondi* (*Cassia occidentalis* L.) (Synonym: *Senna occidentalis* (L.))³⁸, an important medicinal plant belonging to the Caesalpiniaceae family¹³, is used in Unani^{14,15}; Ayurveda^{16,17}, Siddha¹⁷, Asian and African traditional medicines for the treatment of various diseases.¹⁸ It is a common weed, straight, smooth, semi-woody, somewhat branched, foetid herb, 0.8-1.5 m in height, hard, stout, with few lateral roots on its mid section.¹⁹ This medicinal plant is found growing in India²⁰, the tropical and subtropical regions of America, Africa, Asia¹⁹, and Australia.¹⁶ The roots of *Cassia occidentalis* L. are of the tapered type, with 15-25 cm of length and 1-1.5 cm of diameter. The shape of the root is cylindrical, with a tapering at the upper extremity. The surface of the root is rough and dark brown externally and creamy internally.¹⁹ According to Unani medicine, its temperament is *hār-yābis* (hot-dry).^{21,22} It is therapeutically used as *muhallil* (resolvent), *mudirr-i-bawl* (diuretic), and *jālī* (detergent)^{14,21} for the treatment of *istisqā'* (ascites), *waja'al-mafāsīl* (arthralgia), *dīq al-nafas* (bronchial asthma), *yaraqān* (jaundice)^{14,21-23} and renal diseases. A study revealed that the aqueous extract of the leaves of *Cassia occidentalis* L. shows a significant diuretic effect as compared to furosemide and hydrochlorothiazide in rats.¹⁸ On the basis of such evidence, the present study was designed to evaluate the nephroprotective activity of HAE obtained from the root of *Kasondi* (*Cassia occidentalis* L.) against gentamicin-induced nephrotoxicity in albino Wistar rats. The hypothesis of the study was to introduce a nephroprotective herbal drug that can be used as an adjuvant therapy while treating infectious diseases with aminoglycoside antibiotics, particularly gentamicin.

MATERIAL & METHOD

1. Collection and authentication of the plant material

The root of *Kasondi* (*Cassia occidentalis* L.) was collected from the campus of Aligarh Muslim University, Aligarh, Uttar Pradesh, India, during the month of September 2019 and was authenticated by Dr. Akhtar H. Malik, Centre for Biodiversity and Taxonomy (CBT), Dept. of Botany, University of Kashmir, Jammu & Kashmir. The voucher specimen was deposited with reference number 3058 KASH for future reference.

2. Chemicals and other agents

Gentamicin was procured from Nitin Life Sciences Ltd. (marketed by Abbott Healthcare Pvt. Ltd.), Unit III, Rampur Ghat Road, Ponta Sahib, District Sirmour, Himachal Pradesh, India (173025). The batch number of gentamicin was NFF 0041; it was manufactured and expired in January 2020 and December 2021, respectively. Reagents for evaluation of

*Correspondence: Athar Parvez Ansari

E-mail: aatharparvez@gmail.com

Postal address: Regional Research Institute of Unani Medicine, 1 West Madha Church Road, Royapuram, Chennai, Tamil Nadu, India (600013)

Received Apr 04, 2023; Accepted May 08, 2023; Published May 31, 2023
doi: <http://dx.doi.org/10.5667/CellMed.2023.005>

©2023 by CellMedOrthocellular Medicine Pharmaceutical Association
This is an open access article under the CC BY-NC license.

(<http://creativecommons.org/licenses/by-nc/3.0/>)

Protective effects of Hydro-alcoholic extract of the roots of Kasondi (Cassia occidentalis L.) against gentamicin-induced nephrotoxicity in albino Wistar rats.

blood urea, serum creatinine, and serum uric acid were purchased from Erba Mannheim, Transasia Bio-Medicals Ltd., Nalagarh Road, Village Malpur, Baddi, District Solan, Nalagarh Road, Village Malpur, Baddi, District Solan, Himachal Pradesh, India (173205). Eosin was procured from Merk Life Science Pvt. Ltd., Godrej One, 8th floor, Mumbai, India (400079) and haematoxylin was procured from HiMedia Laboratories Pvt. Ltd., 23 Vadhani Ind. Est., LBS Marg, Mumbai, India (400086).

3. Preparation of hydro-alcoholic extract

The roots of *Kasondi* (*Cassia occidentalis* L.) were first dried in the shade, followed by coarse powdering, which was done by using an electric grinder. The extraction was carried out at the Drug Standardization Research Unit (DSRU) of the Regional Research Institute of Unani Medicine, Srinagar. For extraction, the sample was first defatted with petroleum ether at the boiling point (60 °C – 80 °C) in a continuous extraction apparatus using Soxhlet for 6 hours. The extract was quantitatively filtered into a tarred evaporating dish, and the solvent was evaporated on a water-bath. The residue was dried at 105 °C. The yield of pet-ether soluble extract was calculated. After defatting, the sample was subjected to hydro-alcoholic extraction (1:1) for 72 hours. The liquid extract was cooled and filtered through Whatman filter paper (40). The extract was concentrated under reduced pressure using a rotary vacuum evaporator. Thereafter, the extract was weighed and the yield percentage was calculated with reference to the weight of the crude drug, and it was preserved in an airtight glass container at 4°C for further use.³⁹

4. Dosage and route of administration

In Unani literature, the therapeutic dose of *Kasondi* (*Cassia occidentalis* L.) for humans is mentioned as 10 g, which was further calculated by multiplying with a conversion factor of 7 for rats²⁴ and it was found to be 1000 mg/kg b. w. Since the test drug was used in the form of an extract, the dose was further calculated according to the yield obtained in extraction, and it was found to be 67 mg/kg b. w., which was administered by oral route. The dose of gentamicin was given as 100 mg/kg b. w. through a subcutaneous route.

5. Experimental animals

A total of 18 albino Wistar rats of either sex weighing 150-200 g were procured from IIIM, Jammu. They were housed in the animal house of the Regional Research Institute of Unani Medicine, Srinagar, following all the CPCSEA guidelines. They were housed in polypropylene cages under standard laboratory conditions at 23°C ± 2°C and 12 h light and dark cycles. The rats were fed standard commercial food pellets and RO water ad libitum. The research protocol was approved by the Institutional Animal Ethics Committee (IAEC) of RRIUM, Srinagar, India, with Reg. No. 927/GO/Re/S/2006/CPCSEA.

6. Experimental design

The study was carried out according to the method described by Fahamiya et al., 2012 with minor modifications.²⁵ The animals were randomly divided into three groups of six animals each. The study design was as follows:

Group I (Plain control): This group was treated with 1 ml of normal saline *per os* for 8 days.

Group II (Disease control): This group was administered gentamicin at 100 mg/kg b. w. s. c. in the neck region daily from the 4th to the 8th day.

Group III (Treatment group): This group was treated with gentamicin at 100 mg/kg b. w. s. c. in the neck region daily from the 4th to the 8th day, along with the hydro-alcoholic extract of the root of *Cassia occidentalis* L. at 67 mg/kg b. w. *per os* daily for 8 days.

7. Collection of blood sample and kidney specimen

At the end of the experiment, all the animals were sacrificed by administering thiopentone sodium (50 mg/kg b. w.) i. p., after an overnight fast. The blood sample was collected through cardiac puncture and centrifuged using a centrifuge machine at 3000 rpm for 10 minutes²⁴ to separate the serum for biochemical estimation. The kidneys of all the rats were collected and preserved in a 10% phosphate-buffered formalin solution for histopathological studies.^{24,26}

8. Biochemical evaluation

The kidney function tests, including blood urea (GLDH-Urease method)²⁷, serum creatinine (Jaffe's method)²⁸, and uric acid (Modified Trinder method, End point)²⁹, were analyzed using an automatic biochemistry analyzer.

9. Histopathological examination of kidney specimens

After the collection of the kidney specimens, a gross examination was done regarding their size, shape, colour, and any other abnormal findings. The tissue sections were also examined microscopically for histopathological changes. The sliced formalin-preserved kidney tissue was processed for routine paraffin embedding, and 3-5 µ sections were stained with Mayer's haematoxylin and eosin stains, and a blinded histopathological assessment was made.^{30,31} Nikon Eclipse E 200 microscopic camera was used to take photomicrographs in this study. It is pertinent to mention that the histopathological examination was done by a histopathologist, Prof. Pankaj Goswami, who was associated with this study and is one of the co-authors of this publication.

10. Statistical analysis

The data were analyzed using the data editor of SPSS version 20.0 and GraphPad Prism software. All the data collected from the biochemical analysis are expressed as Mean ± Standard Error of Mean (SEM). A one-way ANOVA was employed for the analysis of various parameters among different groups, followed by a post hoc multiple comparison test. The p-value < 0.05 was considered statistically significant.

Protective effects of Hydro-alcoholic extract of the roots of Kasondi (*Cassia occidentalis* L.) against gentamicin-induced nephrotoxicity in albino Wistar rats.

RESULT

1. General physical examination

During the whole study period, all the rats were examined daily for any signs of toxicity, such as abnormal gait, changes in the skin and fur, changes in the colour of the mucus membrane, general behaviour, etc., but no signs of toxicity or mortality were found in any rats.

2. Kidney function biomarkers

The effects of gentamicin and HAE of the root of *Cassia occidentalis* L. on biochemical markers in rats are presented in the table. (Table 1) The s. creatinine, b. urea, and s. uric acid levels were significantly higher in disease control than in plain control. However, these biomarkers were found to be significantly reduced in the treatment group ($p < 0.001$) as compared to the disease control group.

3. Histopathological examination of kidney specimens

3.1 Gross examination

No detectable changes in the kidneys of rats belonging to the plain control group were seen. However, the kidneys of rats

in the disease control group showed necrotic changes in the cortical region. The kidneys of rats belonging to the treatment group revealed normal size with solitary pinpoint necrosis in one kidney.

3.2 Microscopic examination

The cut sections of the kidneys of rats in plain control showed normal tubular architecture with a well distributed and sufficient number of glomeruli in the cortex region, along with a normal medullary pattern with functional tubular structure. (Fig. 1) The kidneys of disease-control rats had a distorted nephron with degenerative glomeruli, severe tubular necrosis with peritubular congestion, necrosis in the cortex region, and desquamated epithelium of convoluted tubules (Fig. 2). The cut sections of the kidneys of rats in the treatment group showed a healthy cortico-medullary junction with minimal congestion of blood vessels in the cortex along with mild interstitial oedema. The glomerular tuft was also found to be in a normal position with mild tubular degenerative changes. (Fig. 3 & 4)

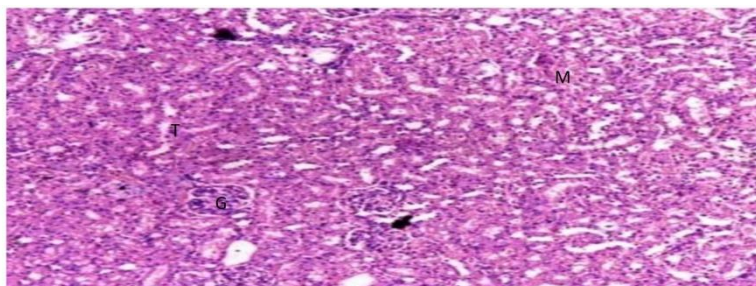


Fig. 1. (PC): Normal tubular structure (T), Glomerulus (G), Cortex and medulla (M) region. (H & E100X)

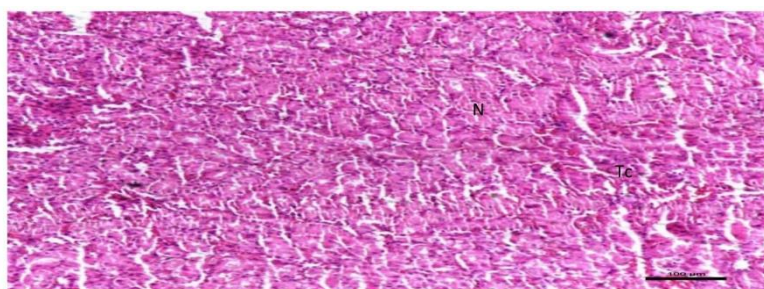


Fig. 2. (DC): Marked congestion in tubular structure, coagulative necrosis (N), desquamated epithelium of convoluted tubules & congestion (Tc) in cortico-medullary region. (H & E100X)

Table 1. Effect of HAE of root of *Cassia occidentalis* L., on biochemical parameters viz. s. creatinine, blood urea and uric acid levels in gentamicin-induced nephrotoxicity in rats

Group	S. creatinine (mg/dl)	B. urea (mg/dl)	S. uric acid (mg/dl)
PC	0.6283±0.02971	28.2633±1.18534	2.1017±0.13323
DC	2.9533±0.20440	117.7233±2.11037	13.1233±0.77102
TG	1.4333±0.19842***a	41.8967±1.31438***a	6.2567±0.28353***a

(PC: Plain control; DC: Disease control; TG: Treatment group)

Protective effects of Hydro-alcoholic extract of the roots of *Kasondi* (*Cassia occidentalis* L.) against gentamicin-induced nephrotoxicity in albino Wistar rats.

P-value < 0.001*** (highly significant) Comparison between groups was made using one-way ANOVA followed by LSD post-hoc multiple comparison test; values are expressed as Mean \pm SEM (n=6)

^aRepresents the difference of TG is significant (p-value <0.001) with DC

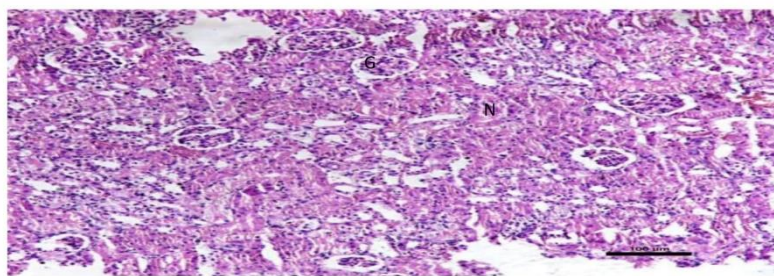


Fig. 3. (TG): Glomerular tuft turns normal (G) in positioning mild tubular nephrosis (N). (H&E100X)

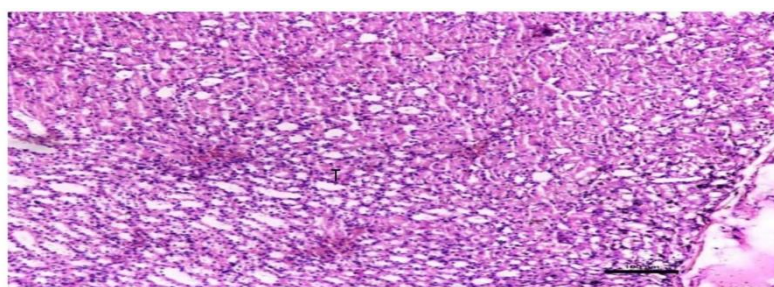


Fig. 4. (TG): Healthy cortico-medullary region evidenced by well-developed tubular structure (T) & stroma. (H & E100X)

DISCUSSION

The hydro-alcoholic extract of the root of *Cassia occidentalis* L. at 67 mg/ kg b. w. showed significant nephroprotective effects against gentamicin-induced nephrotoxicity in albino Wistar rats. The rats treated with gentamicin along with the test drug did not show any abnormal signs during physical examination. Their gait, skin, fur, mucus membranes, and general behaviour were found to be normal. The biomarkers of kidney function such as s. creatinine, b. urea, and s. uric acid levels were found to be promisingly increased in the rats of disease control as compared to those of the plain control, which indicates that gentamicin produced renal toxicity at the dose level of 100 mg/kg b. w. The histological changes of the kidney include a markedly distorted nephron with degenerative glomeruli, severe tubular necrosis along with peritubular congestion, cortical necrosis, marked congestion in tubular structure with marked oedematous stroma, and desquamated epithelium of convoluted tubules, which also supported the evidence of renal toxicity in the rats of disease control. The same biomarkers of kidney function were found to be significantly reduced in the rats of the treatment group as compared to those of the disease control group. This evidence is also supported by the improvement in the histological changes of the kidneys of rats belonging to the treatment group, like a healthy cortico-medullary junction with minimal congestion of blood vessels in the cortex with mild interstitial oedema and the normal position of the glomerular tuft with mild tubular degenerative changes.

According to Unani principles, abnormal temperament, structural anomalies, obstructions, deformities, rupture, trauma, wounds of the kidney, etc. are important causes of renal failure.³² Moreover, *Ibn Rushd* (1126-1198 AD) advocates that an imbalance or derangement in any one of the faculties of the kidney, viz; *quwwat-i-hādima* (digestive faculty), *quwwat-i-jādiba* (absorptive faculty), *quwwat-i-māsika* (retentive faculty), *quwwat-i-dāfi'a* (expulsive faculty), and *quwwat-i-mumayyazah* (distinguishing faculty), leads to renal dysfunction.^{32,33} In Unani medicine, *mudirr-i-bawl* (diuretics), *mufattit-i-ḥasāh* (lithotryptic), and *muqawwī-i-gurda* (nephroprotective) drugs are prescribed in the treatment of renal diseases.³⁴ *Kasondi* (*Cassia occidentalis* L.) possesses *muqawwi* (tonics), *mudirr-i-bawl* (diuretics), and *muqawwī-i-gurda* (nephroprotective) pharmacological properties and is responsible for the moderation of pathological changes and maintenance of the homeostasis of all vital organs¹², including the kidney. However, this important medicinal plant had not been scientifically studied previously. The present study has reported that the HAE of the root of *Cassia occidentalis* L. promisingly reduced the kidney biomarkers and improved the histological changes of nephrotoxic rats induced by gentamicin. Various mechanisms are involved in gentamicin-induced renal toxicity, but the most important one is the excessive generation of ROS, especially hydroxide and hydrogen peroxide, which further causes damage in the nephrons. Moreover, the production of antioxidant enzymatic activity in the kidney is also found to be decreased in the recipients of gentamicin, which is further responsible for lipid

Protective effects of Hydro-alcoholic extract of the roots of Kasondi (Cassia occidentalis L.) against gentamicin-induced nephrotoxicity in albino Wistar rats.

peroxidation production and derangement in the morphological and functional cells of the kidney.³⁵ A study has reported that the aqueous leaf extract of *Cassia occidentalis* L. potentially produces antioxidant activity against nitric oxide scavenging activity, β -carotene-linoleic acid model system, hydroxyl radical scavenging activity, reducing power, metal chelating activity, and superoxide radical scavenging activity. This pharmacological activity might be due to the presence of phenolic compounds in the test substance.³⁶ Another study revealed that the hydro-alcoholic extract of the leaf of *Cassia occidentalis* L. shows significant nephroprotective effects against gentamicin-induced renal toxicity in rats.³⁷ In Unani medicine, drugs obtained from natural sources are used for the treatment of several diseases.³⁸ The data of the present study showed that the HEA of the root of *Cassia occidentalis* L. significantly produces nephroprotective effects against gentamicin-induced renal toxicity in albino Wistar rats, as evident by reductions in kidney biomarkers like s. creatinine, b. urea, and s. uric acid and a promising improvement in the histological changes of the diseased kidney. Furthermore, the result of the present study also validated the claims of the healers of Unani and other traditional medicines about the use of the root of *Kasondi (Cassia occidentalis L.)* in the treatment of kidney diseases.

CONCLUSION

The present study exhibited significant nephroprotective effects of HAE of the root of *Cassia occidentalis* L. against gentamicin-induced nephrotoxicity in rats, as evident by decreased levels of renal biomarkers and improved histological changes of the kidneys in the rats belonging to the treatment group as compared to the disease control. The nephroprotective activity of the test drug is most probably due to reduction in the generation of ROS and increased production of antioxidant enzymatic activity in diseased kidneys. This mode of action may be correlated with the modulation of homeostasis theory as discussed in Unani medicine. However, the exact mechanisms of action of the test drug may be evaluated through separate and comprehensive study models.

ACKNOWLEDGEMENT

We are indebted to the Central Council for Research in Unani Medicine, Ministry of Ayush, Govt. of India, for providing financial support for the study.

RESEARCH FUNDING

This research work was funded by the Central Council for Research in Unani Medicine, Ministry of Ayush, Govt. of India.

AUTHOR CONTRIBUTION

Jwariya Shamim and **Athar Parvez Ansari**: conceptualization, methodology, data curation, investigation, and writing the original draft. **Pankaj Goswami**: involved in the histopathological study of the kidney specimens and interpreted the results with histoarchitectural changes. **Seema Akbar**, **Abdul Wadud**, and **Parvaiz A Dar**: critically reviewed the manuscript. **Huzaifa Ansari**: assisted in the pre-clinical trial.

CONFLICT OF INTEREST

The authors have no conflicting financial interests.

REFERENCES

1. Ronco C, Bellomo R, Kellum JA. Acute kidney injury. *The Lancet*. 2019; 394 (10212): 1949-64. doi:10.1016/S0140-6736 (11) 61454-61462.
2. Dachuri V, Song PH, Kim YW, Ku S, K, Song CH. Protective effects of traditional polyherbs on cisplatin-induced acute kidney injury cell model by inhibiting oxidative stress and MAPK signaling pathway. *Molecules*. 2020; 25 (23): 5641. doi:10.3390/molecules25235641.
3. Levey AS, James MT. Acute kidney injury. *Annals of Internal Medicine*. 2017; 167 (9): 66-80. doi:10.7326/AITC201711070.
4. Kellum JA, Romagnani P, Ashuntantang G, Ronco C, Zarbock A, Anders HJ. Acute kidney injury. *Nature Reviews Disease Primers*. 2021; 7 (1): 1-7. <https://doi.org/10.1038/s41572-021-00284-z>.
5. Basile DP, Anderson MD, Sutton TA. Pathophysiology of acute kidney injury. *Comprehensive Physiology*. 2012; 2 (2): 1303-53. doi:10.1002/cphy.c110041
6. Rewa O, Bagshaw SM. Acute kidney injury: Epidemiology, outcomes and economics. *Nature Reviews Nephrology*. 2014; 10 (4): 193-197. doi:10.1038/nrneph.2013.282.
7. Chinnappan SM, George A, Thaggikuppe P, Choudhary Y, Choudhary VK, Ramani Y, et al. 2019. Nephroprotective effect of herbal extract *Eurycoma longifolia* on paracetamol-induced nephrotoxicity in rats. *Evid-Based Complementary and Alternative Medicine*. 2019; 13: 1-6. <https://doi.org/10.1155/2019/4916519>.
8. Randjelovic P, Veljkovic S, Stojiljkovic N, Sokolovic D, Ilic I. Gentamicin nephrotoxicity in animals: Current knowledge and future perspectives. *EXCLI Journal*. 2017; 16: 388-399. <http://dx.doi.org/10.17179/excli2017-165>.
9. Boroushaki MT, Fanoudi S, Mollazadeh H, Boroumand-Noughabi S, Hosseini A. Reno-protective effect of *Rheum turkestanicum* against gentamicin-induced nephrotoxicity. *Iranian Journal of Basic Medical Sciences*. 2019; 22 (3): 328-333. doi: 10.22038/ijbms.2019.31552.7597.
10. Anonymous. Standard Unani Medical Terminology. (New Delhi: Central Council for Research in Unani Medicine, Department of Ayurveda, Yoga & Naturopathy, Unani, Siddha and Homoeopathy, Ministry of Health & Family Welfare, Government of India), 2012. pp. 238.

Protective effects of Hydro-alcoholic extract of the roots of Kasondi (*Cassia occidentalis* L.) against gentamicin-induced nephrotoxicity in albino Wistar rats.

11. Javaid R, Javed G, Javaid R, Anju, Khan A. Concept of kidney disorders & its treatment in Unani system of medicine. *International Journal of Health Sciences and Research*. 2020; 10 (9): 290-295.
12. Sina I. Al-Qanoon fi'l Tib, vol 2nd (Urdu translation by Kantoori GH). (New Delhi: Ejaz Publication House), 2010. pp. 258.
13. Pal S, Kumar P, Ramakrishna E, Kumar S, Porwal K, Kumar B et al. Extract and fraction of *Cassia occidentalis* L. (a synonym of *Senna occidentalis*) have osteogenic effects and prevent glucocorticoid-induced osteopenia. *Journal of Ethnopharmacology*. 2019; 10 (235): 8-18. doi: 10.1016/j.jep.2019.01.029.
14. Kabeeruddin M. Makhzan al-Mufradat. (New Delhi: Idara Kitab al-Shifa), 2014. pp. 328.
15. Jafri MA, Subhani MJ, Javed K, Singh S. Hepatoprotective activity of leaves of *Cassia occidentalis* against paracetamol and ethyl alcohol intoxicant in rats. *Journal of Ethnopharmacology*. 1999; 6: 355-361. doi: 10.1016/s0378-8741(99)00037-9.
16. Yadav JP, Arya V, Yadav S, Panghal M, Kumar S, Dhankhar S. *Cassia occidentalis* L.: A review on its ethnobotany, phytochemical and pharmacological profile. *Fitoterapia*. 2010; 81 (4): 223-230. doi: 10.1016/j.fitote.2009.09.008.
17. Kumar D, Chawla R, Dhamadaram P, Balakrishnan N. Larvicidal activity of *Cassia occidentalis* L. against the larvae of Bancroftian filariasis vector mosquito *Culex quinquefasciatus*. *Journal of Parasitology Research*. 2014. <http://dx.doi.org/10.1155/2014/236838>.
18. Ntchapda F, Barama J, Azambou DRK, Etet PFS, Dimo T. Diuretic and antioxidant activities of the aqueous extract of leaves of *Cassia occidentalis* (Linn.) in rats. *Asian Pacific Journal of Tropical Medicine*. 2015; 8 (9): 685-693. <http://dx.doi.org/10.1016/j.apjtm.2015.07.030>.
19. Al-Snafi AE. The Therapeutic importance of *Cassia occidentalis*- An overview. *Indian Journal of Pharmaceutical Sciences and Research*. 2015; 5 (3): 158-171.
20. Singh VV, Jain J, Mishra AK. Pharmacological and Phytochemical profile of *Cassia occidentalis* L: A review. *Journal of Drug Delivery and Therapeutics*. 2016; 6 (5): 91-96. <http://dx.doi.org/10.22270/jddt.v6i5.1284>.
21. Ghani N. Khazain al-Adwiya. (New Delhi: Idara Kitab al-Shifa), 2011. pp. 1047-49.
22. Khan MA. Muhit-i-Azam, vol 4th (Urdu translation by CCRUM). (New Delhi: Central council of Research in Unani Medicine, Ministry of Health & Family Welfare), 2018. pp. 190-191.
23. Saifuddin HS. Unani Adwiya Mufarida. (New Delhi: Qaumi Council Bara-i-Farogh Urdu Zubaan), 2013 .pp. 226-227.
24. Ansari AP, Wadud A, Jahan N, Nagaraj R, Irshad S, Iqbal SM. Evaluation of chronic toxicity of *Kushta Sammulfar* (calx of Arsenic trioxide). *Journal of Xenobiotics*. 2013; 3: 14-18.
25. Fahamiyan N, Aslam M, Javed K, Siddiqui A, Shiffa M, Yaqub S, et al. Nephroprotective activity of methanolic extract of *Cumin melo* Linn. in gentamicin-induced nephrotoxicity. *International Journal of Drug Formulation and Research* 2012; 3 (2): 40-53.
26. Fulzele VB, Shedage AT, Smith AA, Gaikwad TV, Kirtane SR. Comparative hepatoprotective activity of liv-52 and silymarine against hepatotoxicity induced by antiandrogen-bicalutamide in rats. *International Journal of Pharmacy and Pharmaceutical Sciences*. 2012; 4 (3): 211-213.
27. Bawakhan B, Chandru MC, Moger V. A comparison between urea reduction ratio and urea kinetic model in assessing hemodialysis adequacy in end stage renal disease. *International Journal of Clinical Biochemistry and Research*. 2018; 5 (2): 263-267. <https://doi.org/10.18231/2394-6377.2018.0054>.
28. Hoste L, Deiteren K, Pottel H, Callewaert N, Martens F. Routine serum creatinine measurements: how well do we perform. *BMC Nephrology*. 2015; 16 (21): 1-9. doi:10.1186/s12882-015-0012-x. <https://doi.org/10.1016/j.jaim.2021.06.005>.
29. Shaw H, Konidena A, Malhotra A, Yumnam N, Farooq F, Bansal V. Psychological status and uric acid levels in oral lichen planus patients- A case control study. *Indian J Dent Res* 2020; 31: 368-375. doi:10.4103/ijdr/IJDR_289_19.
30. Govindappa PK, Gautam V, Tripathi SM, Sahni YP, Raghavendra HLS. Effect of *Withania somnifera* on gentamicin-induced renal lesion in rats. *Brazilian Journal of Pharmacognosy*. 2019; 29: 234-40. <https://doi.org/10.1016/j.bjp.2018.12.005>.
31. Luna LG. Manual of Histologic Staining Method by Armed Forces Institute of Pathology, ed 3rd. New York: Mc Graw Hill Book Company; 1968. pp. 12-33.
32. Alam S, Siddiqui MA, Maaz M. Concept of chronic kidney disease and its management in Unani medicine: A review. *International Journal of Current Research*. 2015; 7 (12): 24785-88.
33. Rushd I. Kitab al-Kulliyat (Urdu translation by CCRUM). (New Delhi: Central Council of Research in Unani Medicine, Ministry of Health & Family Welfare), 1980. pp. 112-113.
34. Alam MA, Quamri MA, Siddiqui MA, Hai U, Sofi G. Nephroprotective effect and Unani Medicine: A Review. *Journal of Nephrology & Therapeutics*. 2016; 6 (1): 1-3. doi:10.4172/2161-0959.1000236.
35. Arya V, Yadav S, Kumar S, Yadav JP. Antioxidant activity of organic and aqueous leaf extracts of *Cassia occidentalis* L. in relation to their phenolic content. *Natural Product Research*. 2011; 25 (15): 1473-1479. doi: 10.1080/14786419.2010.545351
36. Gowrisri M, Sarita K, Swamy BMV, Swamy PA. Antioxidant and nephroprotective activities of *Cassia occidentalis* leaf extract against gentamicin-induced nephrotoxicity in rats. *Research Journal of Pharmaceutical, Biological and Chemical Sciences*. 2012; 3 (3): 684-694.
37. Naushad M, Urooj M, Ahmad T, Husain GM, Kazmi MH, Zakir M. Nephroprotective effect of Tukhm-e-Karafs (*Apium graveolens* L.) against Cisplatin-induced nephrotoxicity. *Journal of Ayurveda and Integrative*

Protective effects of Hydro-alcoholic extract of the roots of Kasondi (Cassia occidentalis L.) against gentamicin-induced nephrotoxicity in albino Wistar rats.

Medicine. 2021: 1-9.
<https://doi.org/10.1016/j.jaim.2021.06.005>.

38. *Cassia occidentalis* L. The Plant List. www.theplantlist.org (accessed on 18th January 2022)
39. Ansari AP, Sana SH, Dar Y, Goswami P, Ahmed NZ. Validation of Unani concept *Abdāl-i-Adwiya* (drug substitution) by physicochemical standardization and hepatoprotective activity of *Aristolochia rotunda* L. and its substitute *Curcuma zedoaria* Rosc. In albino Wistar rats. Journal of Complementary and Integrative Medicine. 2021. <http://doi.org/10.1515/jcim-2020-0378>.