

## A Case Report

# Occupational Therapy Intervention for Malunion of Distal Radial Fracture: A Case Report

Noor Mohammad<sup>1\*</sup>, Nahid Khan<sup>2</sup><sup>1\*</sup> Assistant Professor, Department of Rehabilitation Sciences, Jamia Hamdard, New Delhi, India<sup>2</sup> Assistant Professor, Department of Rehabilitation Sciences, Jamia Hamdard, New Delhi, India

## ABSTRACT

**Objective:** Malunion of distal radial fracture can result in pain, stiffness, and decreased function of the affected limb. Occupational therapy intervention can improve outcomes in these patients, but there is limited research on the effectiveness of such interventions.

**Case Description:** This case report describes the occupational therapy intervention and outcomes for a 44-year-old female patient with malunion of left distal radial fracture. The patient received 8 weeks of occupational therapy intervention consisting of therapeutic exercises, joint mobilization, and fine motor activities. The patient demonstrated significant improvements in range of motion, grip strength, and activities of daily living (ADL) in her left hand. The patient also reported less pain and greater ease in performing activities of daily living.

**Conclusion:** Occupational therapy intervention can be effective in improving outcomes for patients with malunion of distal radial fracture. This case report highlights the importance of early intervention and interdisciplinary collaboration among healthcare professionals to optimize patient outcomes. Further research is needed to explore the effectiveness of occupational therapy interventions for patients with malunion of distal radial fracture.

**Keywords** radial fracture, malunion, occupational therapy, hand function

## INTRODUCTION

Distal radial fractures are a common type of fracture, particularly in older adults.<sup>1,2</sup> Despite appropriate management and treatment, malunion of distal radial fractures can occur, resulting in pain, stiffness, and decreased function of the affected limb. Malunion is defined as healing of a fracture in a position that is not anatomically aligned. Malunion of the distal radius can lead to loss of grip strength, decreased range of motion, and difficulty performing activities of daily living (ADLs) and instrumental activities of daily living (IADLs).<sup>3-6</sup> Occupational therapy intervention can help improve outcomes for patients with malunion of distal radial fractures. This case report describes the occupational

therapy intervention and outcomes for a patient with malunion of left distal radial fracture. The purpose of this case report is to highlight the importance of early intervention and interdisciplinary collaboration among healthcare professionals in optimizing outcomes for patients with malunion of distal fractures.

## Case Report

A 42-year-old female patient presented to occupational therapy department with a history of left wrist pain and stiffness. She had a past medical history of hypertension and was involved in a fall on the left wrist 8 months ago that resulted in a left distal radial fracture. She underwent a treatment by a non-professional near her home in village. He provided an immobilization using crape bandage at the site without properly aligning the fractured site. Patient did not receive occupational therapy intervention post-treatment. The patient reported pain and difficulties with completing activities of daily living and was self-referred for occupational therapy.

\*Correspondence: Noor Mohammad

E-mail: noormohd@jamiyahamdard.ac.in

Address: 5th floor, Central Library, Department of Rehabilitation Sciences, Jamia Hamdard, New Delhi 110062

Received Apr 04, 2023; Accepted May 09, 2023; Published May 31, 2023

doi: <http://dx.doi.org/10.5667/CellMed.2023.006>

©2023 by CellMed Orthocellular Medicine Pharmaceutical Association

This is an open access article under the CC BY-NC license.

(<http://creativecommons.org/licenses/by-nc/3.0/>)

### Evaluation

At the initial evaluation, the patient reported moderate-to-severe pain in her left wrist, and stiffness with limited range of motion. x-ray finding showed the malunion at the fracture site (Figure 1). On physical examination, the patient demonstrated limited wrist extension, flexion, radial deviation and ulnar deviation with decreased grip strength. Forearm supination and pronation range was also restricted. She was also noted to have decreased fine motor functions. The patient was assessed using the Disabilities of the Arm, Shoulder, and Hand (DASH) questionnaire and scored 52.2, indicating a high level of disability.<sup>7</sup>

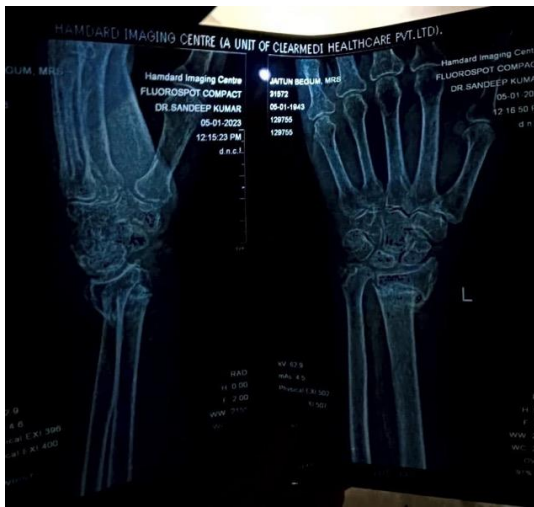


Figure 1. x-ray showing fracture.

### Intervention

The occupational therapy intervention focused on increasing range of motion, strength, and function of the left wrist. The treatment consisted of therapeutic exercises, joint mobilization, and sensory re-education. The patient was also instructed in the use of adaptive equipment to assist with activities of daily living.<sup>4,8</sup> The intervention was provided for 8 weeks, thrice per week, with each session lasting 45 minutes (Figure 2).



Figure 2. Performing task specific activity for grasp.

Joint mobilization techniques were used to improve joint range of motion and reduce pain. These techniques included joint glides and soft tissue mobilization. Therapeutic exercises specific to improve strength, range of motion, and dexterity of the hand were prescribed. These exercises included finger and thumb opposition, wrist flexion, extension, radial and ulnar deviation active assistive range of motion (AAROM) with end range stretch and hand grip exercises (Figure 3).<sup>9,10</sup>




Figure 3. Performing Nirmal hand exerciser for wrist ROM (flexion, extension and circumduction)

### Outcomes

After 8 weeks of occupational therapy intervention, the patient demonstrated significant improvements in range of motion, grip strength, and sensation in her left hand. She was able to perform activities of daily living with less pain and greater ease. The patient was reassessed using the DASH questionnaire and scored 18.2, indicating a significant improvement in function and reduction in disability.

### Discussion

This case report highlights the importance of occupational therapy intervention in the rehabilitation of patients with malunion of distal radial fracture. Early intervention can improve range of motion, strength, and function of the affected limb. The use of therapeutic exercises, joint mobilization, and sensory re-education can be effective in restoring function and reducing disability.<sup>11,12</sup> This case report also emphasizes the need for interdisciplinary collaboration among healthcare professionals to optimize patient outcomes.

### Conclusion

Occupational therapy intervention can be effective in the rehabilitation of patients with malunion of distal radial fracture. The use of therapeutic exercises, joint mobilization, and sensory re-education can improve range of motion, strength, and function of the affected limb, and reduce disability. Early intervention and interdisciplinary collaboration among healthcare professionals can optimize patient outcomes.

### ACKNOWLEDGEMENT

Thank you CellMed for helping us write our thesis.

### CONFLICT OF INTEREST

The authors have no conflicting financial interests.

### REFERENCES

- 1 Luokkala, T. *et al.* Distal radius fractures in the elderly population. **5**, 361 (2020).
- 2 Angst, F. *et al.* Prediction of grip and key pinch strength in 978 healthy subjects. **11**, 1-6 (2010).
- 3 Vannabouathong, C., Hussain, N., Guerra-Farfan, E. & Bhandari, M. J. J. o. t. A. A. o. O. S. Interventions for distal radius fractures: a network meta-analysis of randomized trials. **27**, e596-e605 (2019).
- 4 Handoll, H. H. & Elliott, J. J. C. D. o. S. R. Rehabilitation for distal radial fractures in adults.

- (2015).
- 5 Bazira, P. J. J. S. Surgical anatomy of the hand. (2022).
- 6 Sunderland, S. S. J. M. & Medicine, N. O. J. o. t. A. A. o. E. The anatomy and physiology of nerve injury. **13**, 771-784 (1990).
- 7 Gummesson, C., Atroshi, I. & Ekdahl, C. J. B. m. d. The disabilities of the arm, shoulder and hand (DASH) outcome questionnaire: longitudinal construct validity and measuring self-rated health change after surgery. **4**, 1-6 (2003).
- 8 Herren DB, S. A., Gerber H, et al. . Rehabilitation after distal radius fractures: a systematic review. *Shoulder Elbow* **8**, 83-93.
- 9 MacDermid, J. C., Donner, A., Richards, R. S. & Roth, J. H. J. J. o. c. e. Patient versus injury factors as predictors of pain and disability six months after a distal radius fracture. **55**, 849-854 (2002).
- 10 Michlovitz, S. L., LaStayo, P. C., Alzner, S. & Watson, E. J. J. o. H. T. Distal radius fractures: therapy practice patterns. **14**, 249-257 (2001).
- 11 Roll, S. C. & Hardison, M. E. J. T. A. J. o. O. T. Effectiveness of occupational therapy interventions for adults with musculoskeletal conditions of the forearm, wrist, and hand: a systematic review. **71**, 7101180010p7101180011-7101180010p7101180012 (2017).
- 12 Rozental, T. D. *et al.* Functional outcomes for unstable distal radial fractures treated with open reduction and internal fixation or closed reduction and percutaneous fixation: a prospective randomized trial. **91**, 1837-1846 (2009).