CellMed
Cellmed Orthocellular Medicine and Pharmaceutical Association

Case Report-A learning from clinical experiential history

세포교정영양요법(OCNT)을 이용한 치매 환자 개선 사례 연구

박혜란 약사
연세수약국, 경기도 안산시 단원구 고잔2길 59 신세계빌딩 203호

A Case Study on Symptomatic Improvement of a Dementia Patient Using Ortho-Cellular Nutrition Therapy (OCNT)

Pharmacist, Hye-Ran Park
Yonseisu Pharmacy, #203, Shinsegae Building, 59 Gojan 2-gil, Danwon-gu, Ansan-si, Gyeonggi-do

ABSTRACT

Objective: A case report on the improvement of dementia by Ortho-Cellular Nutrition Therapy.

Methods: A Korean woman in her 80s was suffering from dementia.

Results: Dementia improved after being treated with OCNT.

Conclusion: OCNT may help alleviate symptoms of dementia.

Keywords Ortho-Cellular Nutrition Therapy (OCNT), dementia, bedsores

Introduction

Vascular cognitive impairment defines changes in cognition ranging from subtle deficits to full-blown dementia due to cerebrovascular origin. Ischemic dementia, in which cognitive impairment occurs due to cerebrovascular pathology, accounts for at least 20% of dementia patients, second only to Alzheimer's disease.[1]

Finding an effective treatment for ischemic dementia is more challenging than for Alzheimer's disease. Although the effects are typically minimal, the drugs used for Alzheimer's disease include cholinesterase inhibitors and memantine. Among them, the effects of the three cholinesterase inhibitors, galantamine, donepezil, and rivastigmine, for ischemic dementia were minimal.[2] Although a method to completely cure ischemic dementia has not yet been found, efforts continue to delay the progression and improve patients' quality of life. In this case report, the patient had suffered from ischemic dementia after being diagnosed. After performing OCNT, the patient's ischemic dementia

*Correspondence: Hye-Ran Park
E-mail: hrpark67@naver.com
Received Sep 27, 2023; **Accepted** Sep 27, 2023; **Published** Sep 27, 2023
doi: http://dx.doi.org/10.5667/CellMed.spc.045

† This report has been translated and edited by the CellMed editor-in-chief, Prof. Beom-Jin Lee.

and bedsores were alleviated, and the result is shown in this case report with the patient's consent.

Case Details

1. Subject

One case of an ischemic dementia patient was studied.

1) Name: Kim O O (F/86 years old)
2) Diagnosis: Ischemic dementia
3) Date of onset: November 27, 2022
4) Treatment period: November 27, 2022 ~ present
5) Main complaints: ischemic dementia, bedsores (left and right hip joints)
6) Past history: Meniere
7) Social history: No drinking or smoking
8) Family history: hyperlipidemia, blood pressure
9) On-going medication: Twynsta Tab. 40/5 mg (1 tablet a day), Meniace Tab. (1 tablet twice a day), Rivotril Tab. (0.5 tablets twice a day), Gaslon N OD Tab. 4 mg (once a day), Livalo Tab. 4 mg (1 tablet per day), Spiroxide Tab. (0.5 tablet twice a day), Samjin Nimodipine Tab. (1 tablet twice a day)

2. Methods

Viva Kids (101, twice a day, one packet each time)
Cyaplex F Kids Syrup (010, once a day, 20cc per time)
Hemoplex (202, twice a day, two pills each time)
Cyaplex bamboo salt
Aqua Sac
Heartberry Black
Stemplex, etc

One packet of each was mixed with water and consumed instead of water when taking prescribed medication or whenever thirsty. Cyaplex balm was applied to the affected area where bedsores occurred.

Results

The patient suffered from ischemic dementia and could not recognize days, years, and numbers, and was unable to control her bowels and urine, wearing diapers. She spent most of her time on the bed except when eating and barely ate 2-3 spoonfuls of soup.

She expressed hunger at 3 a.m. and asked for a meal. She had bed sores shaped like a quarter on her left and right hip joints (Fig. 1A), and her lower leg ankles were swollen with edema.

Also, there was no vitality in the patient's eyes, and her face was pale, as if her blood was drained.

OCNT was implemented starting on November 27, 2022. Within two weeks, her eyes began to show vitality. Her appetite improved, and she consumed half and two-thirds of a meal.

The edema that had been present for a long time has disappeared (Fig. 2), and she was able to move around enough to go to the bathroom to urinate and defecate without wearing a diaper.

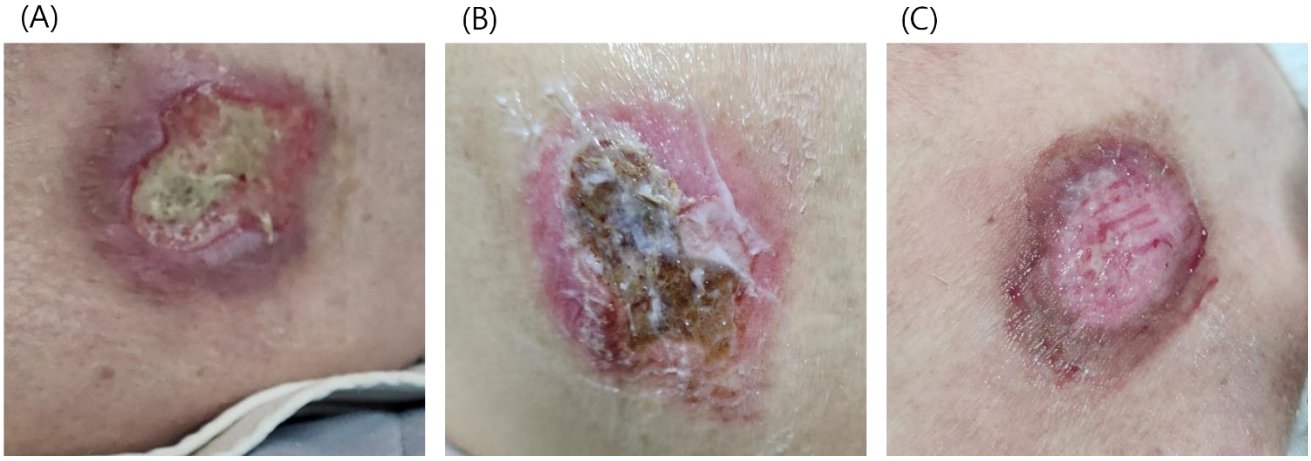

Fig. 1. Comparison of the patient's condition before and during OCNT. A. Patient's bedsore before OCNT. B, C. Patient's bedsore during OCNT.

Fig. 2. The patient's ankle recovered from edema after OCNT.

Discussion

The female patient in her 80s was living alone but was diagnosed with ischemic dementia on November 27, 2022, and moved in with her family. She had reduced cognitive function for her digits, could not walk without relying on a walker, and could not control her bowel movements, forcing her to wear diapers. She expressed severe hip pain and developed worsening bedsores. Also, she could barely eat.

OCNT was prepared in liquid form to make it easier for the elderly patient to consume.

Zinc is an essential trace element abundant in the brain. When zinc homeostasis is disrupted, it causes serious damage to neurons and is associated with various neurodegenerative diseases, including Alzheimer's disease and ischemic dementia.[3] Additionally, patients with Alzheimer's disease or ischemic dementia often lack vitamin D.[4] Viva Kids, which contains zinc and vitamin D, was added for supplementation.

The powerful antioxidant properties of anthocyanins, cyanidin glycosides from Heartberry (Black, Lemon), and polyphenols contained in

Cyaplex F Kids Syrup supplement the antioxidant micronutrients lacking in patients with ischemic dementia.[5] Additionally, fucoidan reduces cerebrovascular damage.[6]

The heme iron contained in Hemoplex is a precursor to hemoglobin, which is needed to bind oxygen in the bloodstream. It is broken down into biliverdin by spleen macrophages and carbon monoxide (CO) and Fe^{2+} ions are released in this process.[7] Some studies reported that CO has a vasodilation function, and therefore, for patients with ischemic dementia, heme iron can help relieve symptoms through its vasodilation function.[8]

Additionally, for the patient who had difficulty eating, calcium was supplemented with Aqua Sac, and nutrition was supplemented with Stemplex's horse placenta peptide and pig placenta peptide.

Finally, Cyaplex balm was applied to the bedsores. Centella asiatica and turmeric root contained in Cyaplex balm treat inflammation caused by bacteria entering wounds due to the bedsores and have an antibacterial effect that prevents secondary infections.[9-12]

Hyaluronic acid supplies moisture to the skin and moisturizes dry skin, while sunflower seed and evening primrose oil normalize the skin barrier.[13-16]

This case study discusses a single case and may not be universally applicable to other dementia patients. Nonetheless, this treatment appears to help improve the patient's symptoms. This case study is reported with the consent of the patient and the patient's legal guardian.

References

1 Iadecola, C. The pathobiology of vascular dementia. *Neuron* **80**, 844-866 (2013).

2 O'Brien, J. T. & Thomas, A. Vascular dementia. *Lancet* **386**, 1698-1706 (2015).

3 Kawahara, M. *et al.* Disruption of zinc homeostasis and the pathogenesis of senile dementia. *Metallomics* **6**, 209-219 (2013).

4 Moretti, R. *et al.* Vitamin D, homocysteine, and folate in subcortical vascular dementia and Alzheimer dementia. *Frontiers in aging neuroscience* **9**, 169 (2017).

5 Polidori, M. C. *et al.* Plasma antioxidant status, immunoglobulin g oxidation and lipid peroxidation in demented patients: relevance to Alzheimer disease and vascular dementia. *Dementia and geriatric cognitive disorders* **18**, 265-270 (2004).

6 Li, Z. *et al.* Low molecular weight fucoidan alleviates cerebrovascular damage by promoting angiogenesis in type 2 diabetes mice. *International Journal of Biological Macromolecules* **217**, 345-355 (2022).

7 Lehninger's Principles of Biochemistry *New York: W. H. Freeman and Company.* **(5th ed.)** pp. 876 (2008).

8 Hanafy, K. A., Oh, J. & Otterbein, L. E. Carbon Monoxide and the brain: time to rethink the dogma. *Curr Pharm Des* **19**, 2771-2775, (2013).

9 Goo, Y.-M. *et al.* Analysis of antibacterial, anti-inflammatory, and skin-whitening effect of Centella asiatica (L.) Urban. *Journal of Plant Biotechnology* **45**, 117-124 (2018).

10 Bulbula, D. D. Comprehensive Review on Turmeric (Curcuma longa l.) as medicinal

plant and its nutraceutical quality to human. *Cancer therapy and Oncology International Journal* **18**, 1-3 (2021).

11 Niamsa, N. & Sittiwet, C. Antimicrobial activity of Curcuma longa aqueous extract. *Journal of Pharmacology and Toxicology* **4**, 173-177 (2009).

12 Mudaliana, S. Antimicrobial activity of Centella asiatica and Gigantochloa apus. *Journal of Basic and Clinical Physiology and Pharmacology* **32**, 755-759 (2021).

13 Jegasothy, S. M., Zabolotniaia, V. & Bielfeldt, S. Efficacy of a new topical nano-hyaluronic acid in humans. *The Journal of clinical and aesthetic dermatology* **7**, 27 (2014).

14 Danby, S. G. *et al.* Effect of olive and sunflower seed oil on the adult skin barrier: implications for neonatal skin care. *Pediatric dermatology* **30**, 42-50 (2013).

15 Kaźmierska, A. *et al.* Effect of Evening Primrose Oil Supplementation on Selected Parameters of Skin Condition in a Group of Patients Treated with Isotretinoin—A Randomized Double-Blind Trial. *Nutrients* **14**, 2980 (2022).

16 Timoszuk, M., Bielawska, K. & Skrzydlewska, E. Evening primrose (Oenothera biennis) biological activity dependent on chemical composition. *Antioxidants* **7**, 108 (2018).