

세포교정영양요법(OCNT)을 이용한 사마귀 개선 사례

하영미 약사

경기도 광명시 오리로 957 예인약국

A Case Study on the Improvement of Warts Using Ortho-Cellular Nutrition Therapy (OCNT)

Pharmacist, Young Mi Ha

Yein Pharmacy, 957, Ori-ro, Gwangmyeong-si, Gyeonggi-do, Republic of Korea

ABSTRACT

Objective: To report a case of wart improvement through Ortho-Cellular Nutrition Therapy (OCNT).

Methods: OCNT was administered to a Korean man in his 30s who complained of pain and difficulty walking due to warts on his feet.

Results: After OCNT administration, wart symptoms improved, and the patient's pain and walking discomfort decreased.

Conclusion: OCNT can help improve wart symptoms.

Keywords Ortho-Cellular Nutrition Therapy (OCNT), warts, human papillomavirus, cryotherapy

Introduction

Warts are skin lesions caused by human papillomavirus (HPV) skin infection. This disease is classified according to the site of occurrence and morphology as common warts, plantar warts, flat warts, and genital warts (condyloma). To date, 225 subtypes of HPV have been identified, and some of these are known to be associated with the development of warts.¹

The HPV subtypes detected in lesion sites vary depending on the type of wart. HPV types 1, 2, 27, and 57 are mainly observed in common warts and plantar warts, while HPV types 3, 10, 27, and 41 are known to cause flat warts.^{2,3} For genital warts, types 6 or 11 are the leading causes, and studies have also detected types 16, 18, 31, 33, and 35 in lesion sites.⁴

Warts show different forms depending on their type. Common warts are mainly characterized by acanthosis (thickening of the skin compared to surrounding areas), papillomatosis (skin protruding like a lump), and punctate hemorrhage (multiple red or purple dots observed in the affected area). Plantar warts show similar symptoms but may be located deeper. Flat warts have similar symptoms but appear flatter and can be single or spread around the surrounding area.⁵

Warts are often confused with skin tags (also called acrochordons or soft fibromas) or corns due to their similar appearance, but they can be distinguished based on the

characteristics of the affected area. Skin tags are benign cell tumors that protrude from the skin in the same color as the skin and are harmless to the body except for cosmetic concerns.⁶ Corns can be diagnosed by observing significant keratinization of the surrounding area, mainly caused by repeated mechanical impacts such as friction or pressure. Uniquely, corns have the characteristic of having an observable core in the center of the lesion.⁷ Therefore, it is crucial to understand the differences between these conditions and provide appropriate treatment.

Various methods are used to treat warts. Representative methods include cryotherapy, which sprays liquid nitrogen on the wart lesion, laser therapy, treatment using ointments containing 5% imiquimod or sinecatechin, and direct injection of bleomycin into the lesion site. However, depending on the type of treatment, there may be side effects such as burning sensation, itching, and pigmentation, and there are limitations in that the applicable treatment may vary depending on the type of wart and patient characteristics.^{8,9}

In this case, the patient complained of discomfort from a wart on the sole of the foot in early 2024. Therefore, Ortho-Cellular Nutrition Therapy (OCNT) was administered, and the patient showed significant improvement in symptoms.

Case Report

1. Subject

One case of a wart patient was studied.

- 1) Name: Jeon OO (30 years old/F)
- 2) Diagnosis: Warts
- 3) Onset: Early 2024
- 4) Treatment period: July 10, 2024 ~ August 6, 2024
- 5) Chief complaint: Plantar warts, corns, difficulty walking
- 6) Past history: Wart development since childhood

*Correspondence: Young Mi Ha

E-mail: pu6229hapa@naver.com

Received Aug 30, 2024; Accepted Aug 30, 2024; Published Aug 30, 2024
doi: <http://dx.doi.org/10.5667/CellMed.spc.095>

©2024 by CellMed Orthocellular Medicine Pharmaceutical Association

This is an open access article under the CC BY-NC license.

(<http://creativecommons.org/licenses/by-nc/3.0/>)

† This report has been translated and edited by the CellMed editor-in-chief, Prof. Beom-Jin Lee.

- 7) Social history: Alcohol consumption 1-2 times a week
- 8) Family history: None
- 9) Present illness and current medications: Cryotherapy in early 2024. Taking nutritional supplements containing yeast components since May of the same year

2. Method

A single wart cream containing alpha-hydroxy acid (AHA), EGCG, tocopherol, carotene, and other ingredients was prescribed and instructed to be applied to the affected area twice daily.

Results

Initially, the patient complained of walking discomfort, with widely distributed calluses and multiple punctate hemorrhages observed. (Fig. 1A.) From May, the patient reported consuming yeast-containing supplements and showed slight symptom improvement. However, calluses and punctate hemorrhages were still observed. (Fig. 1B.)

Full-scale OCNT was implemented from July, and the prescribed ointment was applied for about a month. Upon subsequent observation, punctate hemorrhages had disappeared, and calluses had almost vanished. (Fig. 1C.)

Discussion

The case patient was a man in his 30s who developed plantar warts in early 2024, resulting in difficulty walking. He had a history of warts since childhood and reported that cryotherapy received at the hospital after wart detection was ineffective.

For plantar warts, treatment methods such as cryotherapy, laser therapy, and bleomycin injection can be used. Cryotherapy is the simplest method to apply among these treatments, but research shows that the average cure rate for plantar warts using cryotherapy was 45.61%.¹⁰ Therefore, it was deemed that cryotherapy alone had limitations, and another method suitable for the patient was needed.

Considerations in wart treatment include removing infected lesions, suppressing the virus in the lesion area, and enhancing

immunity to prevent recurrence. Alpha-hydroxy acid (AHA), the main component of the prescribed wart cream, helps lower skin pH and inhibit transferases and kinases, ultimately inducing the breakdown of cell complexes and aiding in exfoliation.¹¹ Additionally, bromelain, a natural enzyme extracted from pineapple contained in the cream, is known to help remove damaged or necrotic tissue.¹²

Among natural extracts known for excellent anti-inflammatory and antibacterial effects is epigallocatechin-3-gallate (EGCG), a type of catechin extracted from green tea. This component exerts antibacterial functions by binding to the cell membranes of various pathogens, including bacteria, inhibiting enzyme activity, and suppressing receptor and protein functions.¹³ White willow bark extract has also been shown through research to contain various beneficial components such as polyphenols, tannins, and flavonoids and to have excellent antibacterial effects.¹⁴ These components contained in the prescribed wart cream are thought to have helped suppress the activity of HPV, the cause of warts.

Warts are a condition that can recur if immunity weakens, even after treatment. Therefore, enhancing immunity in the lesion area is essential to prevent recurrence. Aloe vera components activate immune function by inducing T-cell cytotoxicity and increasing cytokines.¹⁵ It also contains a polysaccharide called acemannan, which helps proliferate leukocytes, macrophages, and dendritic cells.¹⁶ Additionally, tocopherol (vitamin E) is known to help strengthen immune function by preventing cell membrane damage and inhibiting inflammatory factors.¹⁷

The prescribed wart cream contained various components mentioned above, which are thought to have ultimately helped improve the patient's wart symptoms through multiple positive actions. It is also significant that OCNT improved areas where cryotherapy had been ineffective.

This case study has limitations in its applicability to all wart patients as it targeted a single patient. However, it is considered meaningful that OCNT significantly improved wart symptoms, reduced pain, and improved overall quality of life. Therefore, with the patient's consent, this case is being reported.

References

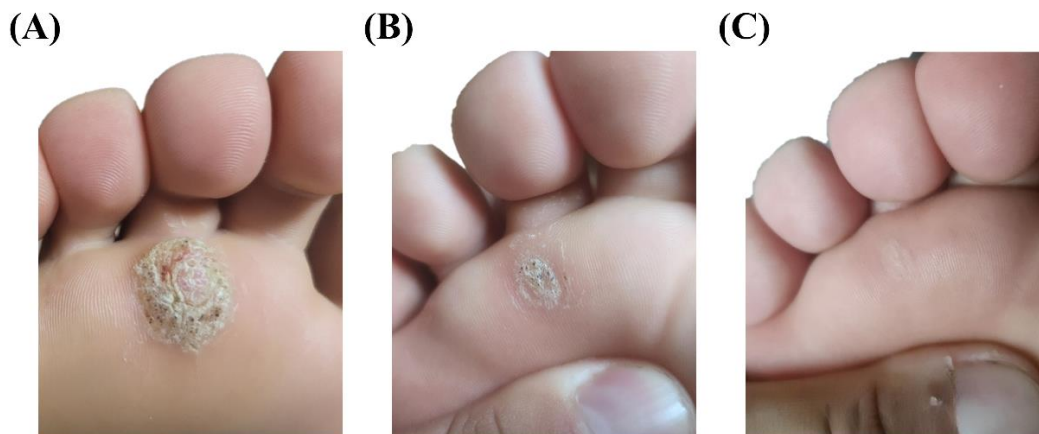


Fig. 1. Changes in the patient's plantar wart condition during OCNT administration. (A) Before OCNT in May 2024, (B) Immediately after OCNT in July of the same year, and (C) After OCNT in August of the same year. As OCNT progressed, the size of the lesion area decreased, and punctate hemorrhage disappeared.

1. Skubic L, Breznik V, Poljak M. Different skin wart types, different human papillomavirus types? A narrative review. *Acta Dermatovenerol Alp Pannonica Adriat*. Dec 2023;32(4):165-171.
2. Hogendoorn GK, Bruggink SC, de Koning MNC, et al. Morphological characteristics and human papillomavirus genotype predict the treatment response in cutaneous warts. *Br J Dermatol*. Jan 2018;178(1):253-260.
3. Pavithra S, Mallya H, Pai GS. Extensive presentation of verruca plana in a healthy individual. *Indian J Dermatol*. May 2011;56(3):324-5.
4. Garland SM, Steben M, Sings HL, et al. Natural history of genital warts: analysis of the placebo arm of 2 randomized phase III trials of a quadrivalent human papillomavirus (types 6, 11, 16, and 18) vaccine. *J Infect Dis*. Mar 15 2009;199(6):805-14.
5. Al About AM, Nigam PK. Wart. *StatPearls*. StatPearls Publishing. Copyright © 2024, StatPearls Publishing LLC.; 2024.
6. Pandey A, Sonthalia S. Skin Tags. *StatPearls*. StatPearls Publishing. Copyright © 2024, StatPearls Publishing LLC.; 2024.
7. Al About AM, Yarrarapu SNS. Corns. *StatPearls*. StatPearls Publishing. Copyright © 2024, StatPearls Publishing LLC.; 2024.
8. Zhu P, Qi RQ, Yang Y, et al. Clinical guideline for the diagnosis and treatment of cutaneous warts (2022). *J Evid Based Med*. Sep 2022;15(3):284-301.
9. Thornsberry L, English JC, 3rd. Evidence-based treatment and prevention of external genital warts in female pediatric and adolescent patients. *J Pediatr Adolesc Gynecol*. Apr 2012;25(2):150-4.
10. García-Oreja S, Álvaro-Afonso FJ, García-Álvarez Y, García-Morales E, Sanz-Corbalán I, Lázaro Martínez JL. Topical treatment for plantar warts: A systematic review. *Dermatol Ther*. Jan 2021;34(1):e14621.
11. Tang SC, Yang JH. Dual Effects of Alpha-Hydroxy Acids on the Skin. *Molecules*. Apr 10 2018;23(4)
12. Varilla C, Marccone M, Paiva L, Baptista J. Bromelain, a Group of Pineapple Proteolytic Complex Enzymes (*Ananas comosus*) and Their Possible Therapeutic and Clinical Effects. A Summary. *Foods*. Sep 23 2021;10(10)
13. Chakrawarti L, Agrawal R, Dang S, Gupta S, Gabrani R. Therapeutic effects of EGCG: a patent review. *Expert Opin Ther Pat*. Aug 2016;26(8):907-16.
14. Aleman RS, Marcia J, Duque-Soto C, et al. Effect of Microwave and Ultrasound-Assisted Extraction on the Phytochemical and In Vitro Biological Properties of Willow (*Salix alba*) Bark Aqueous and
15. Choi S, Chung M-H. A review on the relationship between Aloe vera components and their biologic effects. Elsevier; 2003:53-62.
16. Sierra-García GD, Castro-Ríos R, González-Horta A, Lara-Arias J, Chávez-Montes A. Acemannan, an extracted polysaccharide from Aloe vera: A literature review. *Nat Prod Commun*. Aug 2014;9(8):1217-21.
17. Lewis ED, Meydani SN, Wu D. Regulatory role of vitamin E in the immune system and inflammation. *IUBMB Life*. Apr 2019;71(4):487-494.