CellMed
Orthocellular Medicine and Pharmaceutical Association

Case Report

세포교정영양요법(OCNT)을 이용한 탈모 개선 사례

이태원 약사
전라남도 순천시 서문성터길 1 이조약국

A Case Study on the Improvement of Hair Loss Using Ortho-Cellular Nutrition Therapy (OCNT)

Pharmacist, Tae Won Lee
Ijo Pharmacy, 1, Seomunseongteo-gil, Suncheon-si, Jeollanam-do, Republic of Korea

ABSTRACT
Objective: Report of a case study on the improvement of hair loss symptoms through Ortho-Cellular Nutrition Therapy (OCNT).
Methods: A female in her 50s, who was receiving steroid injection therapy for hair loss symptoms, was treated with OCNT.
Results: After OCNT, the symptoms of hair loss improved, overall hair regrowth was observed, and the patient's quality of life also improved.
Conclusion: OCNT can help improve symptoms of hair loss.

Keywords: Ortho-Cellular Nutrition Therapy (OCNT), Hair Loss, Steroids, Blood Circulation

Introduction

Hair loss refers to the absence of hair where it normally grows. It can be classified into the following categories: partial hair loss due to alopecia areata, scalp ringworm, Menkes syndrome, and Trichotillomania; diffused hair loss caused by abnormal circulation during hair growth stages; and androgenic alopecia resulting from genetic predisposition or hormonal imbalances.[1]

The hair growth cycle includes the anagen, catagen, and telogen stage. Hair loss mainly occurs during the anagen phase, where premature entry into this phase can lead to abnormal hair loss resulting in alopecia. Additionally, immune dysfunction can lead to hair loss due to autoimmune attacks on healthy hair follicles by immune cells such as CD8+ T cells. Excessive action of androgens, which can activate male sex hormone functions, or hyperthyroidism or hypothyroidism can also affect hair loss. Other factors such as medications, specific infections and diseases, and nutritional status are also considered relevant to hair loss.[2]

This can determine the presence and type of hair loss based on various aspects and patterns of expression. Typical characteristics include thinning hair, an M-shaped pattern, the ratio of the number of hair follicles to the number of hairs, the degree of scalp scaling, and scarring. Trichoscopy, using a dermoscope, is commonly used for diagnosis.[3,4]

Various methods can be used for hair loss treatment depending on the patient's condition. Steroids can be used, administered orally, as a local injection, or in ointment form. However, although this method has proven short-term effectiveness, its long-term effects are uncertain and it is one of the difficult methods to apply over an extended period.[5] Other methods include using minoxidil for its anti-androgenic and immunosuppressive effects to treat hair loss, but its effectiveness is not fully proven, and it is challenging to apply to pregnant women.[6]

While hair loss does not cause physical harm, patients experiencing it often undergo psychological stress, leading to decreased quality of life and potential subsequent disorders. Feelings of shame, anger, humiliation, and loss of self-esteem are common, which can lead to anxiety, depression, and other mental health issues. Furthermore, stress can accelerate hair loss, potentially creating a vicious cycle where more stress is experienced.[7] Therefore, improving hair loss is crucial for enhancing the patient's quality of life and providing psychological support.

The patient in this case study has been experiencing stress due to hair loss symptoms that began in 2017 and has shown symptoms of depression. Significant improvements were observed following the application of Ortho-Cellular Nutrition Therapy (OCNT).

Case Study

*Correspondence: Taewon Lee
E-mail: alptpet@naver.com
Received Sep 30, 2024; **Accepted** Sep 30, 2024; **Published** Sep 30, 2024
doi: http://dx.doi.org/10.5667/CellMed.spc.097

† This report has been translated and edited by the CellMed editor-in-chief, Prof. Beom-Jin Lee.

Case study conducted on one case of hair loss patient.

1. Subject

1) Name: Shin OO (F, 59 years old)
2) Diagnosis: Hair loss
3) Date of onset: 2017
4) Treatment duration: January 2024 – Present
5) Primary symptoms: Hair loss, feelings of depression
6) Medical history: Treatment at dermatology and traditional Korean medicine clinics for hair loss
7) Social history: None
8) Family history: None
9) Medications and Treatments Applied: Scalp steroid injections for hair loss, medications for athlete's foot (eczema), osteoporosis, joint pain, and gastroesophageal reflux disease

2. Methods

- First OCNT (January 2024)
  Cyaplex X granules (101, twice daily, one sachet per dose)
  Hemoplex capsules (202, twice daily, two capsules per dose)
  Morangmorang booster capsules (101, twice daily, one capsule per dose)
  Cyaplex mineral rock salt (101, twice daily, one sachet per dose)

Instructions were given to dissolve Cyaplex X and Cyaplex mineral rock salt in 1L of water before ingestion. Dietary prescriptions included prohibiting the intake of synthetic vitamins and fish oil-derived omega-3, and limiting dairy, eggs, coffee, and foods with excessive use of cooking oil and late-night meals. Also advised to ensure at least 8 hours of sleep and perform sternocleidomastoid muscle massage twice each in the morning, afternoon, and evening.

- Second OCNT (February 2024 – April 2024)
  Prescribed the same as the first OCNT. At this point, it was advised not to receive prescribed steroids from the hospital as they could negatively affect symptom improvement.

- Third OCNT (May 2024 – July 2024)
  Cyaplex X granules (101, twice daily, one sachet per dose)
  Hemoplex capsules (202, twice daily, two capsules per dose)
  Morangmorang booster capsules (101, twice daily, one capsule per dose)
  Cyaplex mineral rock salt (101, twice daily, one sachet per dose)
  Gastron granules (101, twice daily, one sachet per dose)

Added Gastron granules to the prescription after the patient reported feeling bloated, gassy, and often experiencing indigestion.

- Fourth OCNT Phase (July 18, 2024 - July 25, 2024)
  Cyaplex X granules (101, twice daily, one sachet per dose)
  Hemoplex capsules (202, twice daily, two capsules per dose)
  Morangmorang booster capsules (101, twice daily, one capsule per dose)
  Cyaplex mineral rock salt (101, twice daily, one sachet per dose)

Gastron granules were excluded from the prescription as gastrointestinal symptoms improved.

- Fifth OCNT Phase (July 25, 2024 - August 19, 2024)
  The following OCNT treatments were added to the fourth phase:
  Resplex Alpha capsules (202, twice daily, two capsules per dose)
  Hoduplex capsules (101, twice daily, one capsule per dose)

- Sixth OCNT Phase (August 19, 2024 - Present)
  Cyaplex X granules (101, twice daily, one sachet per dose)
  Morangmorang booster capsules (101, twice daily, one capsule per dose)
  Cyaplex mineral rock salt (101, twice daily, one sachet per dose)
  Resplex Alpha capsules (202, twice daily, two capsules per dose)
  Hoduplex capsules (101, twice daily, one capsule per dose)

Results

Before starting OCNT, the patient's hair loss was so severe that she visited the pharmacy wearing a headscarf, and visually, no hair except some white strands were observed around the crown area. In February 2024, localized black hair growth was observed on the crown, which seemed to be a temporary effect of scalp steroid injections received at the hospital.

Three months after applying OCNT, in April 2024, the patient reported feeling hair growth. From May onwards, black hair started appearing in the frontal and surrounding scalp areas. By June, the patient no longer needed to wear a headscarf, indicating an overall improvement in hair coverage. From July onwards, an increase in self-esteem was also noticeable. In August, upon examining the areas where steroid injections were frequently received, a significant increase in hair density and a reduction in bald patches were observed.

The progress of the patient's hair loss improvement through OCNT is depicted in Figures 1-4.

Discussion

The patient, a woman in her 50s, has been experiencing hair loss since 2017. Despite seeking treatments from various hospitals, clinics, and pharmacies, there was no improvement in her symptoms. Her job, which involves frequent interaction with people, contributed to her depressive symptoms due to the hair loss.

Before applying OCNT, the patient had been receiving scalp steroid injections every few months. Steroid treatments like Dutasteride and Finasteride are commonly used in injections or oral forms to treat hair loss but can cause side effects such as contact dermatitis, reduced sexual function, and electrolyte imbalances. Frequent injections can also lead to folliculitis, limiting the suitability of long-term use.[8] The patient felt temporary satisfaction from the localized growth of black hair following each injection. Consequently, the hospital advised against frequent injections, yet she continued to receive them, indicating a need for alternative treatments. Therefore, an alternative method was required to replace the current treatment.

The patient’s job involves high physical activity in environments with high temperatures and humidity. Thus, it was presumed that the hair loss was caused by an imbalance in Qi and Blood leading to a state of deficient metabolism, referred to as a deficiency syndrome, and excessive sweating from the head, known medically as cranial hyperhidrosis. Additionally, poor blood circulation might have hindered the supply of oxygen and nutrients to the hair follicles. Thus, the

Fig. 1. Patient's frontal photos during the OCNT process. (A) January 2, 2024, (B) February 22, 2024, (C) July 25, 2024, show the changes in the patient's condition over time. It is believed that the black hair in the center of image (B) is a result of the steroid injections prescribed to the patient.

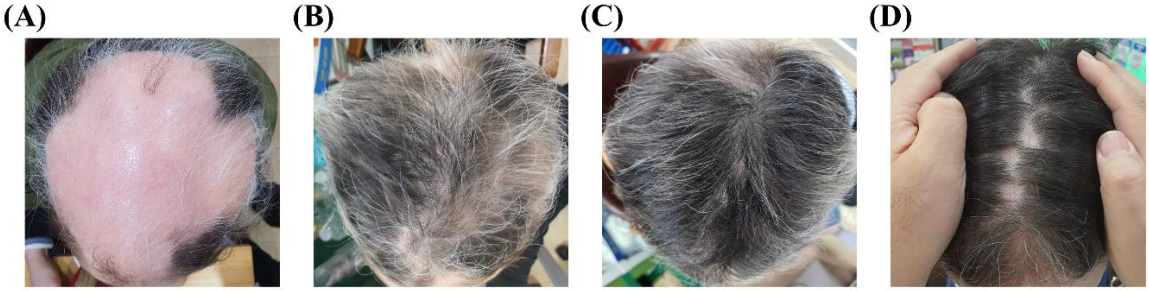

Fig. 2. Patient's parietal photos during the OCNT process. (A) January 2, 2024, (B) May 10, 2024, (C) June 24, 2024, (D) August 19, 2024. The central area in (D) where the steroid injection was administered shows slower recovery than the surrounding areas, but the overall hair growth condition appears satisfactory.

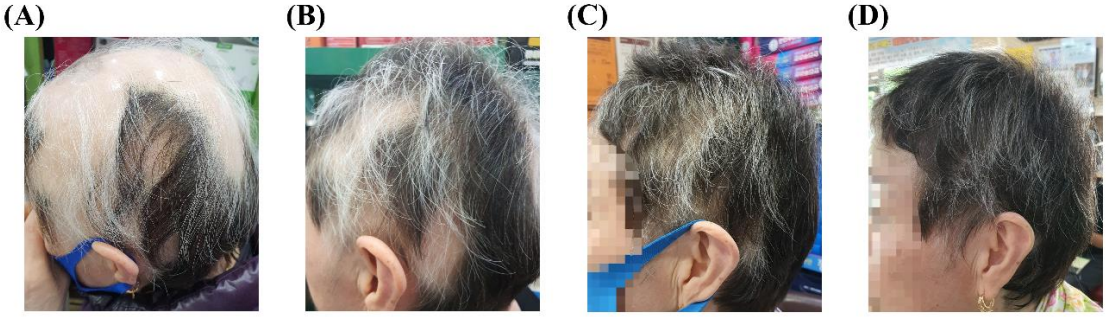

Fig. 3. Patient's temporal photos during the OCNT process. (A) February 22, 2024, (B) May 10, 2024, (C) June 24, 2024, (D) July 25, 2024.

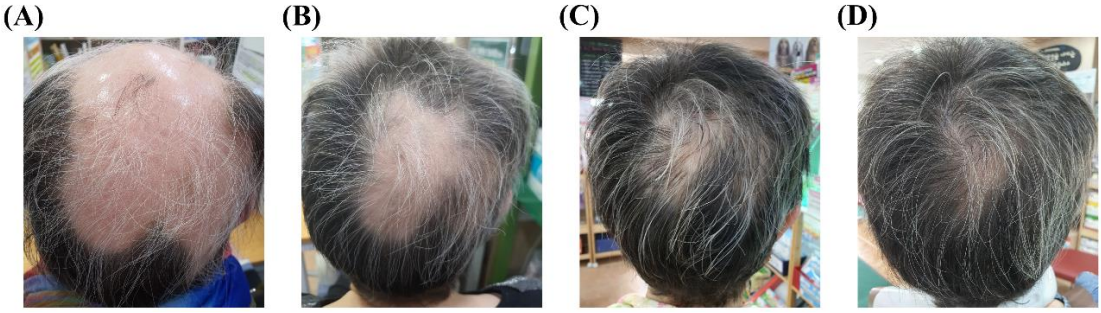

Fig. 4. Patient's occipital photos during the OCNT process. (A) January 2, 2024, (B) May 10, 2024, (C) July 18, 2024, (D) August 19, 2024.

patient aimed to improve her immune system and overall blood circulation to aid in alleviating hair loss.

Anthocyanins reduce inflammatory cytokines such as TNF-α and IL-10, and suppress the expression of MCP-1 and ICAM-1 genes involved in immune responses, thereby helping to decrease excessive immune reactions. They also lower the markers of oxidative stress such as Myeloperoxidase (MPO), and inducible Nitric Oxide Synthase (iNOS), contributing to their antioxidant effects.[9] Therefore, efforts were made to provide high-quality anthocyanins using Cyaplex X and Cyaplex Mineral Rock Salt.

Rock salt, a key component of which is Cyaplex mineral rock salt, contains a significant amount of trace minerals such as magnesium, calcium, sulfur, zinc, and iodine, which are essential nutrients for normal follicle development and immune cell function.[10,11] Given the patient's environment, which often leads to excessive sweating, it was assumed that there would be a substantial loss of minerals, necessitating supplementation.

The Morangmorang booster capsules contain biotin. A study evaluating 18 cases related to biotin and hair growth found that 8 cases involved hair loss due to biotin deficiency, and supplementation improved the symptoms of hair loss.[12] Therefore, the intake of biotin is considered beneficial for improving hair loss symptoms.

Hemoplex capsules were used to improve blood circulation in the scalp and ensure that nutrients were well transported to the scalp. Iron stimulates the production of new red blood cells and helps improve blood flow.[13] Additionally, numerous studies have shown that iron deficiency in women can increase the likelihood of hair loss.[11] Therefore, supplying high-quality iron was aimed to help improve symptoms.

The main ingredient in Resplex Alpha capsules, *Ginkgo biloba* extract, can reduce oxidative stress, inhibit platelet aggregation, and help improve overall blood circulation.[14] Furthermore, linolenic acid, the main component of Hoduplex, is abundantly found in walnuts and has been shown to improve blood pressure and overall cardiovascular functions.[15]

During OCNT, the patient complained of gastrointestinal symptoms such as bloating and gas, leading to the prescription of Gastron. The Chinese yam extract in Gastron is known to increase microbial diversity and beneficial bacteria in the gut, thereby helping to alleviate gastrointestinal discomfort.[16]

Overall, it is believed that OCNT significantly improved the long-standing symptoms of hair loss. Unlike the temporary and localized effects of steroid treatments, overall scalp hair loss showed improvement, which is considered meaningful.

This case study involved a single patient, and while it may not be universally applicable to all patients with hair loss, the significant improvement in hair loss symptoms through simple OCNT, which enhanced her self-esteem and quality of life, is deemed significant. Therefore, with the patients' consent, this case is reported.

References

1. Phillips TG, Slomiany WP, Allison R. Hair Loss: Common Causes and Treatment. *Am Fam Physician*. Sep 15 2017;96(6):371-378.

2. Lin RL, Garibyan L, Kimball AB, Drake LA. Systemic causes of hair loss. *Ann Med.* Sep 2016;48(6):393-402.

3. Mounsey AL, Reed SW. Diagnosing and treating hair loss. *Am Fam Physician*. Aug 15 2009;80(4):356-62.

4. Alessandrini A, Bruni F, Piraccini BM, Starace M. Common causes of hair loss - clinical manifestations, trichoscopy and therapy. *J Eur Acad Dermatol Venereol*. Mar 2021;35(3):629-640.

5. MacDonald Hull SP, Wood ML, Hutchinson PE, Sladden M, Messenger AG. Guidelines for the management of alopecia areata. *Br J Dermatol*. Oct 2003;149(4):692-9.

6. Gupta AK, Talukder M, Venkataraman M, Bamimore MA. Minoxidil: a comprehensive review. *J Dermatolog Treat*. Jun 2022;33(4):1896-1906.

7. Hadshiew IM, Foitzik K, Arck PC, Paus R. Burden of hair loss: stress and the underestimated psychosocial impact of telogen effluvium and androgenetic alopecia. *J Invest Dermatol*. Sep 2004;123(3):455-7.

8. Nestor MS, Ablon G, Gade A, Han H, Fischer DL. Treatment options for androgenetic alopecia: Efficacy, side effects, compliance, financial considerations, and ethics. *J Cosmet Dermatol*. Dec 2021;20(12):3759-3781.

9. Sahoo DK, Heilmann RM, Paital B, et al. Oxidative stress, hormones, and effects of natural antioxidants on intestinal inflammation in inflammatory bowel disease. *Front Endocrinol (Lausanne)*. 2023;14:1217165.

10. ul Hassan A, Din AMU, Ali S. Chemical characterisation of Himalayan rock salt. *Pakistan Journal of Scientific & Industrial Research Series A: Physical Sciences*. 2017;60(2):67-71.

11. Almohanna HM, Ahmed AA, Tsatalis JP, Tosti A. The Role of Vitamins and Minerals in Hair Loss: A Review. *Dermatol Ther (Heidelb)*. Mar 2019;9(1):51-70.

12. Durusoy C, Ozenli Y, Adiguzel A, et al. The role of psychological factors and serum zinc, folate and vitamin B12 levels in the aetiology of trichodynia: a case-control study. *Clin Exp Dermatol*. Oct 2009;34(7):789-92.

13. Frise MC, Robbins PA. Iron, oxygen, and the pulmonary circulation. *J Appl Physiol (1985)*. Dec 15 2015;119(12):1421-31.

14. Liang H, Yuan X, Sun C, et al. Preparation of a new component group of Ginkgo biloba leaves and investigation of the antihypertensive effects in spontaneously hypertensive rats. *Biomed Pharmacother*. May 2022;149:112805.

15. Sala-Vila A, Fleming J, Kris-Etherton P, Ros E. Impact of α-Linolenic Acid, the Vegetable ω-3 Fatty Acid, on Cardiovascular Disease and Cognition. *Adv Nutr*. Oct 2 2022;13(5):1584-1602.

16. Cui Y, Zhou Y, Li Y, Wang J, Li D, Chen F. Chinese Yam and Its Active Components Regulate the Structure of Gut Microbiota and Indole-like Metabolites in Anaerobic Fermentation In Vitro. *Nutrients*. Dec 14 2023;15(24)