

## 세포교정영양요법(OCNT)을 이용한 검버섯 개선 사례 보고

김미진 약사

전라남도 영암군 삼호읍 신항로 63-12 한솔온누리약국

### A Case Report on the Improvement of Seborrheic Keratosis Using Ortho-Cellular Nutrition Therapy (OCNT)

Pharmacist, Mijin Kim

Hansol Onnuri Pharmacy, 63-12, Sinhang-ro, Samho-eup, Yeongam-gun, Jeollanam-do, Republic of Korea

#### ABSTRACT

**Objective:** Skin aging can be categorized into extrinsic and intrinsic aging based on its causes. Extrinsic aging, caused by environmental factors. This leads to various skin changes, such as pigmented lesions like melasma and seborrheic keratosis, hypopigmentation such as vitiligo, and actinic keratosis. Seborrheic keratosis is a common benign epidermal tumor frequently observed in clinical settings. It typically appears as round or oval-pigmented lesions with irregular borders. The prevalence of seborrheic keratosis increases with age. Laser treatment is the most commonly used therapy in modern medicine due to its low recurrence rate and minimal scarring.

**Case Report:** This case study presents the application of Ortho-Cellular Nutrition Therapy (OCNT) in a female patient in her 70s, diagnosed with seborrheic keratosis and melasma. The patient reported that her skin darkened due to reduced sleep caused by pre-existing panic disorder and insomnia. It was determined that her underlying skin condition had worsened. As a result, lanolin, cyanidin, catechins, and hyaluronic acid were prescribed to improve the skin condition caused by seborrheic keratosis and reduce skin damage from ultraviolet (UV) exposure. After five months of OCNT, the patient's skin tone had shifted to a pinkish hue, and seborrheic keratosis noticeably diminished.

**Conclusion:** The OCNT regimen addressed the reduction in skin elasticity and moisture levels associated with the patient's age. It aimed to replenish moisture and stimulate epidermal cell regeneration, leading to an overall improvement in skin condition. Since this case study involved a personalized treatment for a single patient, its applicability to all individuals with seborrheic keratosis and related skin conditions may be limited. However, after several months of treatment, the patient's skin condition significantly improved, suggesting potential implications for future skin disease management.

**Keywords** Ortho-Cellular Nutrition Therapy (OCNT), melasma, seborrheic keratosis, keratosis, lanolin, cyanidin

#### Introduction

Skin aging can be categorized into extrinsic and intrinsic aging based on its causes. Extrinsic aging results from environmental factors such as ultraviolet (UV) exposure, air pollution, smoking, alcohol consumption, and nutritional imbalances. Skin changes associated with extrinsic aging include pigmented lesions like melasma and seborrheic keratosis, hypopigmentation like vitiligo, and actinic keratosis. In contrast, intrinsic aging is driven by genetic factors and the

natural aging process, with common signs including skin atrophy and wrinkles. Using physical and chemical UV blockers and avoiding excessive sun exposure is essential to minimize skin aging. Additionally, antioxidants such as vitamin E, vitamin C, coenzyme Q10, and glutathione play a positive role in preventing skin aging. Therefore, for individuals experiencing skin conditions related to aging, a diet rich in antioxidant-packed fruits and vegetables is recommended.<sup>1</sup>

Seborrheic keratosis is a common benign epidermal tumor observed in clinical dermatology, also known as senile wart. It typically presents as round or oval-pigmented lesions, although irregularly shaped lesions can also occur. The pigmentation varies in color, ranging from yellow and light brown to black. Seborrheic keratosis grows exophytically, forming a distinct boundary from the surrounding skin, giving the appearance of being attached to the skin's surface. Flat lesions have a smooth, velvety surface texture, and lesions may appear pedunculated in areas with skin folds, such as the axilla or groin. While these

\*Correspondence: Mijin Kim

E-mail: navi9011@hanmail.net

Received Apr 28, 2025; Revised Apr 29, 2025; Accepted Apr 30, 2025; Published Apr 30, 2025

doi: <http://dx.doi.org/10.5667/CellMed.spc.123>

©2025 by CellMed Orthocellular Medicine Pharmaceutical Association

This is an open access article under the CC BY-NC license.

(<http://creativecommons.org/licenses/by-nc/3.0/>)

† This report has been translated and edited by the CellMed editor-in-chief, Prof. Beom-Jin Lee.

lesions proliferate initially, they tend to stabilize in size. Over time, however, they may increase in size and thickness, and their color can change due to increased melanin production. Seborrheic keratosis does not resolve on its own and can be removed through various procedures.<sup>2</sup>

Seborrheic keratosis increases in prevalence with age, and in elderly individuals, hundreds of lesions can be observed. It occurs at similar rates regardless of gender or ethnicity, with frequent reports of familial influences. According to a census in Australia, the prevalence of seborrheic keratosis in individuals over 50 is nearly 100%, with an average of 70 lesions found in those over 75. On the other hand, seborrheic keratosis can also occur in younger age groups. Among individuals aged 15 to 30, approximately 15% of those under 19 and 32% of those over 25 have seborrheic keratosis. These statistics indicate that seborrheic keratosis affects not only older individuals but also younger patients.<sup>3</sup>

Seborrheic keratosis is a benign tumor, so treatment is generally not required. However, when treatment is pursued due to social factors, physical changes, or stress, the treatment method and potential complications should be carefully considered. One method of local removal is curettage, which involves scraping the skin surface with a sharp curette. This technique may lead to scarring or incomplete removal, resulting in the recurrence of the lesion. An alternative approach is shave excision, where a scalpel is used to remove the lesion, although recurrence can also occur with this method.<sup>4</sup> Cryotherapy and electrosurgery offer the advantage of minimal scarring; however, they are associated with a high recurrence rate. Laser treatment has recently garnered attention due to its ability to reduce pigmentation, improve skin texture, and accelerate healing. Although laser treatment requires multiple sessions, it can effectively remove lesions with minimal scarring and a low recurrence rate. Consequently, it has become the preferred method for treating seborrheic keratosis.<sup>5</sup>

The patient in this case study reported the onset of skin conditions, including seborrheic keratosis and melasma, beginning in 2023. Previously, she had bright and fair skin; however, as her sleep quality declined due to insomnia, localized skin changes appeared, followed by the development of seborrheic keratosis and melasma. In search of relief, the patient visited the pharmacy and opted to manage her symptoms through Ortho-Cellular Nutrition Therapy (OCNT), which led to an improvement in the lesions. This case study presents the outcomes of that treatment.

## Case Study

### 1. Subject

This case study involves a single patient with seborrheic keratosis.

- 1) Name: Lee ○○ (71 years old / F)
- 2) Diagnosis: Melasma, seborrheic keratosis
- 3) Date of onset: January 2023
- 4) Treatment period: November 18, 2024 – Present
- 5) Chief complaint: Skin abnormalities
- 6) Medical history: None
- 7) Social history: None
- 8) Family history: None

9) Current illness and medications: Panic disorder, insomnia

### 2. Method

Samagon Cream (applied once daily to the affected area in the evening)

Cyaplex Balm (applied once daily to the affected area in the evening)

## Results

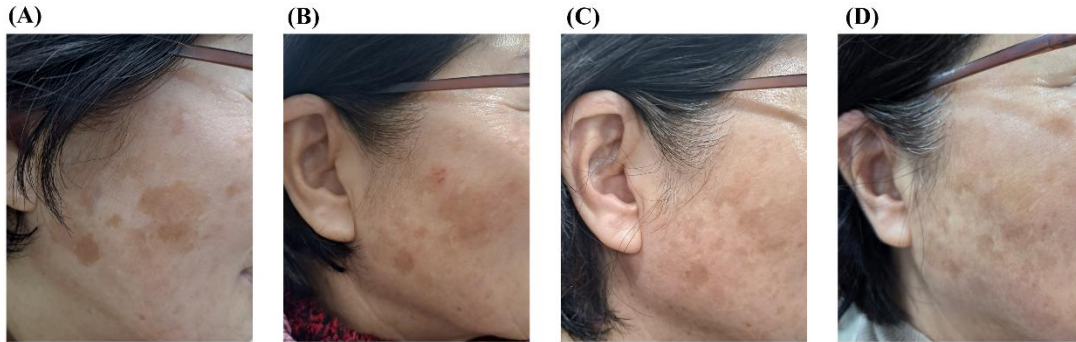
At the beginning of the treatment, numerous large and small seborrheic keratoses were observed on the patient's skin. Following the initiation of OCNT in November 2024, the patient's skin tone gradually turned pinkish, accompanied by repeated formation and shedding of scabs, indicating ongoing skin regeneration. As a result, the overall skin tone brightened, and lesions of seborrheic keratosis and melasma significantly decreased. With continued progression, the patient's skin condition improved, and she has reported consistently using the topical agents once daily in the evening. The changes in the patient's skin over the five-month OCNT regimen are presented in Figs. 1–2.

## Discussion

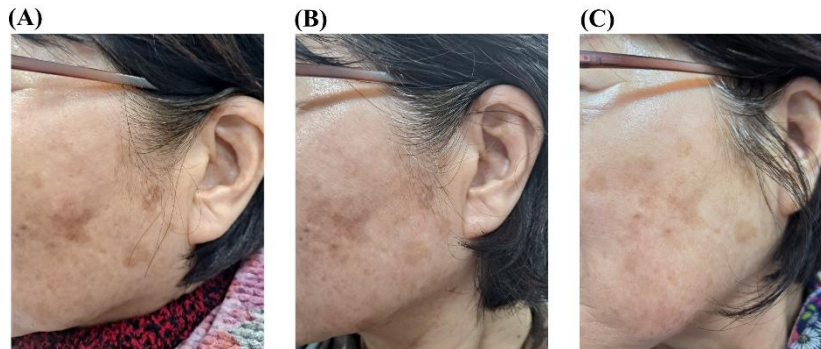
The patient in this case study originally had fair skin but reported that her skin gradually darkened over the past three years due to sleep deprivation and insomnia. Therefore, the patient visited a psychiatrist one year ago, diagnosed with panic disorder in the neurology department and started medication. This condition further exacerbated seborrheic keratosis and melasma. Therefore, OCNT was implemented to support overall skin improvement by replenishing moisture and facilitating the elimination of waste products from skin compromised by insufficient sleep.

Seborrheic keratosis is a benign epidermal tumor that occurs on the skin. Although the exact cause of seborrheic keratosis is not yet fully understood, a decline in the overall skin condition negatively impacts the development of seborrheic keratosis.<sup>6</sup> Therefore, the OCNT regimen aimed to induce changes in the stratum corneum, the outermost layer of the epidermis, to improve the existing skin condition. The stratum corneum is composed of keratinized, dead epidermal cells with no nuclei. This layer is critical in protecting the body's internal structures from the external environment, assisting with temperature regulation, and minimizing moisture loss, making it vital for skin function. The lanolin component positively affects this layer by enhancing the skin's moisture retention capacity and penetrating the stratum corneum to deliver essential oils and moisture.<sup>7</sup> Therefore, the treatment involved prescribing Cyaplex Balm, which contains lanolin, to benefit the stratum corneum and improve overall skin positively.

Long-term exposure to ultraviolet (UV) radiation increases the incidence of seborrheic keratosis. UV radiation induces skin carcinogenesis and inflammation, disrupting immune homeostasis. Additionally, reactive oxygen species (ROS) generated by UV radiation cause harmful effects on tissues, leading to the deposition of various pigments and accelerating



**Fig. 1. Changes in the patient's seborrheic keratosis on the right cheek during OCNT.** (A) Before the initiation of OCNT on November 29, 2024; (B) January 11, 2025; (C) February 7, 2025; (D) April 15, 2025. As OCNT progressed, a reduction in seborrheic keratosis and improvement in skin condition were observed.



**Fig. 2. Changes in the patient's seborrheic keratosis on the left cheek during OCNT.** (A) January 11, 2025; (B) February 7, 2025; (C) April 15, 2025. As OCNT progresses, the skin tone shifts to a pinkish hue, and pigmentation lightens.

skin aging. Cyanidin, one of the components in Cyaplex Balm, is an anthocyanin-based bioactive compound found in various fruits and vegetables. This compound exhibits potent antioxidant and anticancer properties. It also significantly inhibits the expression of several cytokines, reducing inflammation and interfering with markers related to DNA damage, thus playing a role in reducing skin tumors.<sup>8</sup> Therefore, Cyaplex Balm was prescribed to repair skin damage caused by ultraviolet radiation and to inhibit oxidative processes within the skin tissue.

The patient experienced numerous large and small pigmentations on the skin due to seborrheic keratosis. Therefore, the treatment aimed to activate skin cell synthesis and maintain connective tissue structure to improve pigmentation. Samagon Cream contains a rich amount of catechin, an extract from green tea. Catechin is a key component derived from tea leaves and is known for its potent antioxidant properties and various bioactive functions. This compound delays the breakdown of the extracellular matrix induced by ultraviolet radiation and environmental pollutants. Additionally, it directly acts on the skin to induce collagen biosynthesis and inhibits the production of matrix metalloproteinases (MMPs), which break down the skin's connective tissue structure, thus preventing skin aging. Notably, the hydroxyl structure of catechin effectively neutralizes free radicals better than conventional antioxidants, benefiting tissue damage and aging.<sup>9</sup> Therefore, the OCNT regimen included the prescription of Samagon Cream to support the synthesis of the patient's new skin tissue.

As individuals age, various skin conditions often accompany keratosis. This phenomenon occurs due to the decreased elasticity of tissue connections and the reduction in epidermal moisture, which are commonly seen in aging skin. Hyaluronic acid, which helps exfoliate keratin and moisturize the skin, is widely used in treating skin conditions. Hyaluronic acid improves actinic keratosis, reduces pigmentation, and helps maintain moisture, ultimately brightening skin tone. It also increases collagen density, assists in epidermal tissue synthesis, and affects skin elasticity, thus improving photoaged skin. Formulations containing hyaluronic acid serve as both exfoliants and moisturizers, making them valuable in treating many skin conditions.<sup>10</sup> Therefore, Samagon Cream, containing alpha hyaluronic acid (AHAs) and beta hyaluronic acid (BHAs), was prescribed to improve the patient's aged skin through moisturization and exfoliation.

In this case study, the patient's seborrheic keratosis and overall skin condition progressively improved throughout the OCNT regimen. The patient reported continued daily use of the prescribed products for ongoing improvement. However, this treatment was tailored to a single patient, and its application to all cases of seborrheic keratosis and related skin conditions may have limitations. Nevertheless, the significant improvement in the patient's skin condition over several months of treatment could hold valuable insights for future research on skin disorders. This case study is reported with the patient's consent.

## References

1. Puizina-Ivic N. Skin aging. *Acta Dermatovenerologica Alpina Panonica Et Adriatica*. 2008;17(2):47.
2. Barthelmann S, Butsch F, Lang BM, et al. Seborrheic keratosis. *J Dtsch Dermatol Ges*. Mar 2023;21(3):265-277.
3. Yeatman J, Kilkenny M, Marks R. The prevalence of seborrheic keratoses in an Australian population: does exposure to sunlight play a part in their frequency? *British Journal of Dermatology*. 1997;137(3):411-414.
4. Wood LD, Stucki JK, Hollenbeak CS, Miller JJ. Effectiveness of cryosurgery vs curettage in the treatment of seborrheic keratoses. *JAMA dermatology*. 2013;149(1):108-109.
5. Gurel MS, Aral BB. Effectiveness of erbium: YAG laser and cryosurgery in seborrheic keratoses: Randomized, prospective intraindividual comparison study. *Journal of Dermatological Treatment*. 2015;26(5):477-480.
6. Gorai S, Ahmad S, Raza SSM, et al. Update of pathophysiology and treatment options of seborrheic keratosis. *Dermatologic Therapy*. 2022;35(12):e15934.
7. Dixit S. Lanolin for silky, soft, smooth skin. *CHEMICAL WEEKLY-BOMBAY*. 2001;47(10):153-156.
8. Pratheeshkumar P, Son Y-O, Wang X, et al. Cyanidin-3-glucoside inhibits UVB-induced oxidative damage and inflammation by regulating MAP kinase and NF- $\kappa$ B signaling pathways in SKH-1 hairless mice skin. *Toxicology and applied pharmacology*. 2014;280(1):127-137.
9. Bae J, Kim N, Shin Y, Kim S-Y, Kim Y-J. Activity of catechins and their applications. *Biomedical Dermatology*. 2020;4:1-10.
10. Tören E, Mazari AA, Buzgo M. Exploring the efficacy of AHA–BHA infused nanofiber skin masks as a topical treatment for acne vulgaris. *Journal of Applied Polymer Science*. 2024;141(14):e55203.