

## 세포교정영양요법(OCNT)을 이용한 췌장암 합병증 개선 사례 보고

박정아 약사

경기도 광명시 금하로 525 인제약국

### A Case Report on the Improvement of Pancreatic Cancer Complications Using Ortho-Cellular Nutrition Therapy (OCNT)

Pharmacist, Jeonga Park

Inje Pharmacy, 525, Geumha-ro, Gwangmyeong-si, Gyeonggi-do, Republic of Korea

#### ABSTRACT

**Objective:** Pancreatic cancer is one of the leading causes of cancer-related mortality and remains among the most lethal malignant neoplasms worldwide. According to the Global Cancer Observatory estimates in 2012, pancreatic cancer accounts for more than 331,000 deaths annually, representing approximately 4% of all cancer-related deaths. Survival rates in patients with pancreatic cancer are influenced by multiple factors, including tumor type and stage at diagnosis. Currently, no recommended screening method exists for the prevention of pancreatic cancer; therefore, primary prevention is of paramount importance.

**Case Report:** The patient in this case was a Korean male in his 60s, diagnosed with pancreatic cancer in August 2022. He underwent partial pancreatectomy combined with splenectomy and cholecystectomy, followed by a total of 18 cycles of chemotherapy over six months. As a complication, the patient developed diabetes mellitus with an elevated hemoglobin A1c level. Consequently, Ortho-Cellular Nutrition Therapy (OCNT), comprising anthocyanins, *Momordica charantia* (bitter melon) extract, curcumin, and post-symbiotics, was administered. The patient has continued OCNT since November 2022, and as of September 2025, hospital examinations confirmed recovery to normal ranges.

**Conclusion:** This report is limited by its single-patient design and thus cannot be generalized to all patients with pancreatic cancer-related diabetes. Nevertheless, sustained OCNT was associated with improvements in blood glucose levels and body weight, which may represent clinically meaningful outcomes. With the patient's consent, we present this case.

**Keywords** Ortho-Cellular Nutrition Therapy (OCNT), pancreatic cancer, chemotherapy, diabetes mellitus, anthocyanins, *Momordica charantia* extract

#### 서론

Pancreatic cancer is one of the leading causes of cancer-related mortality and is among the most lethal malignant tumors worldwide. It is broadly classified into two tumor types, with approximately 85% reported as adenocarcinomas and about 5% as pancreatic neuroendocrine tumors. According to the Global Cancer Observatory estimates in 2012, pancreatic cancer causes more than 331,000 deaths annually, accounting for about 4% of all cancer-related deaths. The five-year survival rate of pancreatic cancer is less than 5%, and both incidence and mortality increase with advancing age. Although the exact etiology of pancreatic cancer has not been fully

elucidated, identified risk factors have been identified, including smoking, family history, genetic predisposition, diabetes mellitus, obesity, dietary factors, alcohol consumption, and insufficient physical activity.<sup>1</sup>

Pancreatic cancer is an extremely fatal malignancy, with a mortality-to-incidence ratio reaching approximately 98%, and survival rates show little difference between developed and developing countries. According to the United States National Cancer Institute, fewer than 10% of patients with pancreatic cancer are diagnosed at the localized stage, for which the five-year survival rate is about 30%. However, more than 52% of patients are diagnosed at the distant stage, where the five-year survival rate is only 2.6%. Survival outcomes in patients with pancreatic cancer are influenced by various factors: tumor type, stage at diagnosis, serum albumin levels, tumor size, treatment modality, age, sex, and lifestyle factors.<sup>2</sup>

According to a study conducted in the United Kingdom in 2011, approximately 30% of pancreatic cancer cases are estimated to be associated with smoking. Furthermore, a recent meta-analysis including 82 studies reported that the relative risk (RR) of pancreatic cancer was 1.7 among current smokers

\*Correspondence: Jeong-A Park

E-mail: pjfran@naver.com

Received Sep 26, 2025; Revised Sep 29, 2025; Accepted Sep 30, 2025, 2025; Published Sep 30, 2025

doi: <http://dx.doi.org/10.5667/CellMed.spc.141>

©2025 by CellMed Orthocellular Medicine Pharmaceutical Association

This is an open access article under the CC BY-NC license.

(<http://creativecommons.org/licenses/by-nc/3.0/>)

□ This report has been translated and edited by the CellMed editor-in-chief, Prof. Beom-Jin Lee.

and 1.2 among former smokers. Thus, smokers have about a 75% higher risk of pancreatic cancer compared with non-smokers, and this elevated risk persists for up to 10 years after smoking cessation. In addition, the European EPIC study in 2012 demonstrated that the risk of pancreatic cancer increases significantly with every increment of more than five cigarettes smoked per day, and passive smoking was also observed to increase the risk by approximately 50%.<sup>3</sup>

Currently, no screening method is recommended for the prevention of pancreatic cancer. Therefore, primary prevention is particularly important, and modifiable risk factors for this disease include smoking, obesity, diabetes mellitus, dietary habits, and alcohol consumption. To date, preventive strategies for pancreatic cancer have primarily focused on the mitigation of established risk factors through lifestyle modifications and systematic management of underlying health conditions.<sup>4</sup>

## Case Study

### 1. Subject

A single case of a patient with pancreatic cancer was examined.

- 1) Name: OOO (62 years/M)
- 2) Diagnosis: Pancreatic cancer
- 3) Onset: August 2022
- 4) Treatment period: November 2022 – Present
- 5) Chief complaint: Diabetes mellitus
- 6) Past medical history: None
- 7) Social history: None
- 8) Family history: Diabetes mellitus
- 9) Present illness and previous medication: Chemotherapy (Gemcitabine), Sugamet XR 2.5/850 mg

### 2. Methods

The patient underwent Ortho-Cellular Nutrition Therapy (OCNT) as follows:

#### 1) OCNT administered during chemotherapy

Cyaplex F granules (202, twice daily, 2 sachets per dose)  
Eufaplex Alpha granules (202, twice daily, 2 sachets per dose)  
Nutaplex granules (101, twice daily, 1 sachet per dose)  
Enzaplex F granules (101, twice daily, 1 sachet per dose)  
Curcuplex granules (101, twice daily, 1 sachet per dose)  
Betaplex granules (101, twice daily, 1 sachet per dose)  
Tmplex F capsules 101 (101, twice daily, 1 capsule per dose)  
Selenplex capsules (202, twice daily, 2 capsules per dose)  
Diverol F capsules (001, once daily, 1 capsule per dose)  
Aqua combination (Cyaplex mineral, Aqua SAC pure, Heartberry Black)

#### 2) OCNT administered after chemotherapy

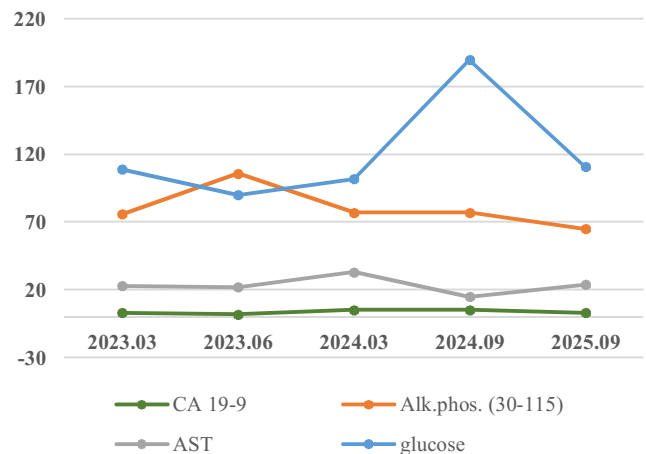
Cyaplex F granules (202, twice daily, 2 sachets per dose)  
Eufaplex Alpha granules (101, twice daily, 1 sachet per dose)  
Momoplex (101, twice daily, 1 sachet per dose)  
Enzaplex F granules (101, twice daily, 1 sachet per dose)  
Curcuplex granules (101, twice daily, 1 sachet per dose)  
Selenplex capsules (101, twice daily, 1 capsule per dose)  
Tmplex F granules (101, twice daily, 1 sachet per dose)  
Diverol F capsules (001, once daily, 1 capsule per dose)  
Aqua combination (Cyaplex mineral, Aqua SAC pure, Heartberry Black)

In addition, the current regimen was supplemented with Bioplex (1 sachet daily), Sacoplex (1–2 sachets daily), and Oatglucan (1–2 sachets daily).

## Results

The patient was diagnosed with pancreatic cancer and underwent pancreatectomy. Subsequently, the HbA1c level increased to approximately 6.8, leading to a diagnosis of diabetes mellitus. In addition, the patient experienced a weight loss of about 10 kg, indicating deterioration of health status. The patient was prescribed antidiabetic medication at the hospital and initiated Ortho-Cellular Nutrition Therapy (OCNT) at a pharmacy. Furthermore, continuous interventions targeting lifestyle modification, including exercise and dietary regulation, were implemented. Using a continuous glucose monitoring device, the patient's 24-hour blood glucose levels were measured in real time. Following the initiation of OCNT, the patient has maintained an HbA1c level of 5.6–5.7 and regained approximately 5 kg of body weight.

In addition, the patient underwent partial pancreatectomy and cholecystectomy, which raised concerns regarding potential impairment of hepatic and pancreatic function. However, as a result of continuous OCNT from 2023 to the present, it was confirmed that the major hematological and biochemical parameters remained within the normal range. The health checkup results during the period of OCNT are presented in Fig.



**Fig. 1. Hematological and biochemical parameters of the patient during the OCNT period**

It can be confirmed that they were stably maintained within the normal range.

1.

## Discussion

The patient in this case was a man in his 60s who was diagnosed with pancreatic cancer in August 2022. In September of the same year, he underwent resection of 70% of the pancreas along with splenectomy and cholecystectomy, followed by a total of 18 sessions of chemotherapy over six months. After pancreatectomy, the patient developed diabetes mellitus with elevated HbA1c levels; however, with prescribed antidiabetic medication and OCNT, the HbA1c level subsequently decreased to within the normal range. The patient has continued OCNT since November 2022, and hospital examinations conducted in September 2025 confirmed that the values remained within the normal range.

Diabetes mellitus represents both an established risk factor for pancreatic cancer and a frequent complication observed as a sequela of the disease, thereby necessitating comprehensive management through dietary modification, physical activity, and pharmacological therapy. The patient was prescribed Cyaplex F granules, which are rich in anthocyanins. Several studies have demonstrated that dietary anthocyanins exert significant effects on glycemic control and glucose metabolism. In previous studies, administration of anthocyanins to subjects significantly reduced fasting blood glucose, postprandial 2-hour blood glucose, HbA1c, and indices of insulin resistance, while no changes were observed in insulin and C-peptide levels. These findings suggest that dietary anthocyanins may serve as an adjunctive approach to improving glycemic control markers and glucose metabolism in patients with diabetes mellitus.<sup>5</sup> Accordingly, in this case, anthocyanins were prescribed with the aim of improving diabetes secondary to pancreatic cancer.

In addition, Momoplex prescribed to the patient contains bitter melon (*Momordica charantia*) extract. Bitter melon is a fruit cultivated in South America and Asia, and it exerts hypoglycemic effects by reducing blood glucose levels. According to one study, administration of bitter melon extract to patients with type 2 diabetes mellitus and experimental mice significantly decreased blood glucose concentrations during an oral glucose tolerance test. Furthermore, daily dietary supplementation with bitter melon fruit was observed to improve glucose tolerance.<sup>6</sup> These effects are considered to be attributable to the saponin components contained in bitter melon extract, as saponin fractions have been reported to inhibit disaccharidase activity and suppress postprandial hyperglycemia.<sup>7</sup> These findings suggest that bitter melon may contribute to improving glucose tolerance in diabetes mellitus.

Curcuplex granules contain curcumin, the principal component of turmeric, a traditional Indian spice, which possesses anti-inflammatory and antioxidant properties. In traditional medicine, curcumin has been used to improve diabetes mellitus and its complications. Previous studies have reported that curcumin supplementation activates insulin receptors and related pathways, thereby improving insulin resistance.<sup>8</sup> Accordingly, in this case, curcumin was prescribed with the aim of activating insulin metabolism-related pathways and exerting a beneficial effect on insulin resistance.

Meanwhile, the patient experienced a weight loss of approximately 10 kg due to cancer treatment and chemotherapy, which resulted in a compromised immune status. To promote recovery of immune function, Bioplex containing postbiotics was prescribed. Postbiotics refer to metabolic byproducts generated through the metabolic activities of beneficial gut bacteria. They possess unique structures and functions, act as key mediators in the metabolic processes between the gut microbiota and host, and play a central role in maintaining homeostasis. Through these mechanisms, improvements in the host's intestinal environment and enhancements in immune function have been reported.<sup>9</sup> Accordingly, in this case, postbiotics were administered with the aim of inducing fundamental immune enhancement and restoration of intestinal homeostasis.

In this case, the patient demonstrated improvement of diabetes mellitus symptoms induced by pancreatectomy and regained approximately 5 kg of body weight through OCNT administered from 2022 to the present. The patient continues OCNT and will undergo ongoing monitoring to assess blood glucose levels and overall health status. This report is limited to a single patient and therefore cannot be generalized to all

individuals with diabetes secondary to pancreatic cancer. Nevertheless, the normalization of blood glucose levels and the postoperative confirmation of improved health status represent meaningful findings. With the patient's consent, this case is hereby reported.

## References

1. Ilic M, Ilic I. Epidemiology of pancreatic cancer. *World J Gastroenterol.* 2016;22(44):9694-705.
2. Coleman M, Forman D, Bryant H, Butler J, Rachet B, Maringe C, et al. Cancer survival in Australia, Canada, Denmark, Norway, Sweden, and the UK, 1995–2007 (the International Cancer Benchmarking Partnership): an analysis of population-based cancer registry data. *The Lancet.* 2011;377(9760):127-38.
3. Lynch SM, Vrieling A, Lubin JH, Kraft P, Mendelsohn JB, Hartge P, et al. Cigarette smoking and pancreatic cancer: a pooled analysis from the pancreatic cancer cohort consortium. *American journal of epidemiology.* 2009;170(4):403-13.
4. Anand P, Kunnumakara AB, Sundaram C, Harikumar KB, Tharakan ST, Lai OS, et al. Cancer is a preventable disease that requires major lifestyle changes. *Pharmaceutical research.* 2008;25(9):2097-116.
5. Fallah AA, Sarmast E, Jafari T. Effect of dietary anthocyanins on biomarkers of glycemic control and glucose metabolism: A systematic review and meta-analysis of randomized clinical trials. *Food Research International.* 2020;137:109379.
6. Oishi Y, Sakamoto T, Udagawa H, Taniguchi H, Kobayashi-Hattori K, Ozawa Y, et al. Inhibition of increases in blood glucose and serum neutral fat by *Momordica charantia* saponin fraction. *Bioscience, biotechnology, and biochemistry.* 2007;71(3):735-40.
7. Leatherdale BA, Panesar RK, Singh G, Atkins TW, Bailey CJ, Bignell AH. Improvement in glucose tolerance due to *Momordica charantia* (karela). *Br Med J (Clin Res Ed).* 1981;282(6279):1823-4.
8. Jiménez-Osorio AS, Monroy A, Alavez S. Curcumin and insulin resistance—molecular targets and clinical evidences. *Biofactors.* 2016;42(6):561-80.
9. Ozma MA, Abbasi A, Akrami S, Lahouty M, Shahbazi N, Ganbarov K, et al. Postbiotics as the key mediators of the gut microbiota-host interactions. *Infez Med.* 2022;30(2):180-93.