

SPONTANEOUS ERUPTION OF IMPACTED MAXILLARY PRIMARY CANINE AFTER REMOVAL OF ODONTOMA

So-Yeon Park¹, Soo Kyoung Kim², Sung Chul Choi¹, Kwang Chul Kim¹, Jae-Hong Park¹

¹*Department of Pediatric Dentistry and Institute of Oral Biology, School of Dentistry, Kyung Hee University*

²*Dasom Junior Dental Clinic*

Abstract

Complex odontomas consist of a conglomerate mass of enamel, dentin and cementum which bears no anatomic resemblance to a tooth. The majority of these lesions are completely asymptomatic, being discovered on routine radiographic examination or when films are taken to determine the reason for tooth eruption failure. Compound odontomas seldom cause bony expansion, but complex odontomas often cause slight or even marked bony expansion. Complex odontomas are mostly associated with permanent teeth and very rarely associated with deciduous teeth. They are usually located in the first- or second-molar areas of the mandible.

This report presents a case of a patient with impaction of a maxillary primary canine by a complex odontoma in which surgical excision of the lesion was performed. And the primary canine was repositioned right under gingival level for spontaneous eruption. Follow-up after six months showed spontaneous eruption of the repositioned maxillary primary canine.

Key words : Remove of odontoma, Impacted tooth, Spontaneous eruption

1. Introduction

Odontomas are the most common types of odontogenic tumors, constituting approximately 70% of all odontogenic tumors of the jaws. They are composed of various formations of dental tissue including enamel, dentin, cementum and sometimes pulp¹. Odontomas are considered to be developmental anomalies resulting from the growth of completely differentiated epithelial and mesenchymal cells that give rise to functional ameloblast and odontoblast².

Odontomas are subdivided into compound and complex types by degrees of morphodifferentiation or similarities with normal tooth structures. Compound odontomas consist of a small malformed tooth having normal enamel, dentin and cementum. They are usually located in the upper incisor areas and are mostly found in 6~10-year-olds³. Complex odontomas consist of a conglomerate

mass of less organized dental tissues that seldom show teeth or tooth-like structures compared with compound odontomas. Complex odontomas are usually located in the first or second molar areas of the mandible and more often occur in males. The lesions constitute about 25% of all odontomas and about 22% of all odontogenic tumors of the jaw^{4,5}. The etiology of odontomas is uncertain, but is hypothesized to involve infection, local trauma, inheritance or mutation disturbing the genetic control of tooth development^{6,7}.

The majority of these lesions are discovered on a routine radiographic examination or when films are taken to determine the reason for failure of a tooth to erupt. There is no associated pain or paresthesia and no tenderness to palpation⁸.

Both types of odontomas are encased in a fibrous capsule, and the lesion usually separates easily from its bony bed. There is little probability of recurrence².

교신저자 : 박재홍

서울특별시 동대문구 회기동 1 / 경희대학교 치과대학 소아치과학교실, 구강생물학교실 / 02-958-9379 / pedopjh@khu.ac.kr

원고접수일: 2011년 10월 10일 / 원고최종수정일: 2011년 12월 23일 / 원고채택일: 2012년 01월 10일

This report presents a case of a complex odontoma diagnosed in a child with impaction of a maxillary deciduous canine due to the lesion obstructing normal tooth eruption. Considering the degree of root formation, surgical excision of the lesion was performed with favorable results, leading to spontaneous eruption.

II . Case study

A 2.5-year-old girl was referred to the Department of Pediatric Dentistry, Kyung Hee University with a chief complaint of lack of right maxillary primary canine eruption. There were no specific findings in the patient's medical or dental history. Clinical examination of the intraoral conditions and manual palpation indicated a solid mass with bone-like appearance and hardness as well as some swelling in the deciduous canine region of the right maxilla. Pain or gingival abnormalities were not observed. Intraoral radiographs, panorama, and lateral cephalometric radiographs obtained at the first examina-

tion showed an oval-shaped radiopaque/radiolucent irregularly-mixed mass that closely associated with the crown of the unerupted primary canine. The root of the primary canine was formed, with 1/2 ~ 2/3 of complete formation (Fig. 1).

Provisionally, the lesion was diagnosed as an adenomatoid odontogenic tumor or calcifying odontogenic cyst, and 3D cone-beam CT imaging was performed. An amorphous calcified mass in the follicular space was observed in proximity to the impacted right maxillary deciduous canine, with a radiolucent spot seen in the mass. There was a thin radiolucent line separating the mass and the tooth (Fig. 2).

The lesion was diagnosed as a complex odontoma, but we did not exclude the possibility of ameloblastic fibro-odontoma. Via regular observation, we confirmed that the lesion exhibited no progressive growth or a propensity for local destruction and to the mass was surgically excised. After the eruption time of the maxillary primary canine had passed and ankylosis was not observed, the root was approximately 2/3 formed and there was sufficient space for eruption. We expected spontaneous eruption of the tooth and ensured the path of eruption as we surgically extracted the mass. Local infiltration anesthesia (2% lidocaine, one ampule) was administered in the muco-gingival area of the right maxillary primary canine, and a full-thickness mucoperiosteal flap was formed by performing an intrasulcular incision at the primary incisor and at the first deciduous molar areas in addition to an intercrestal incision in the primary canine area. Bone was removed to uncover the mass, a visual field was ensured, and a conservative excision was performed. During the enucleation of the odontoma, the

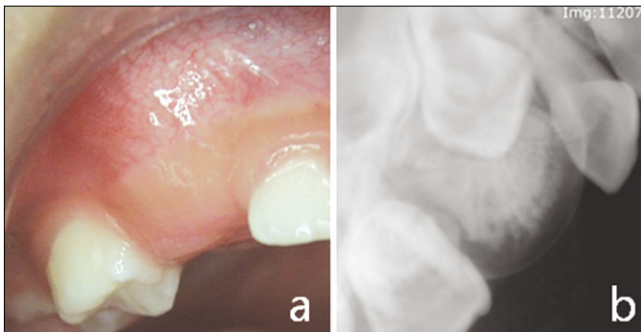


Fig. 1. Intraoral view(a), periapical view(b) at the first visit.

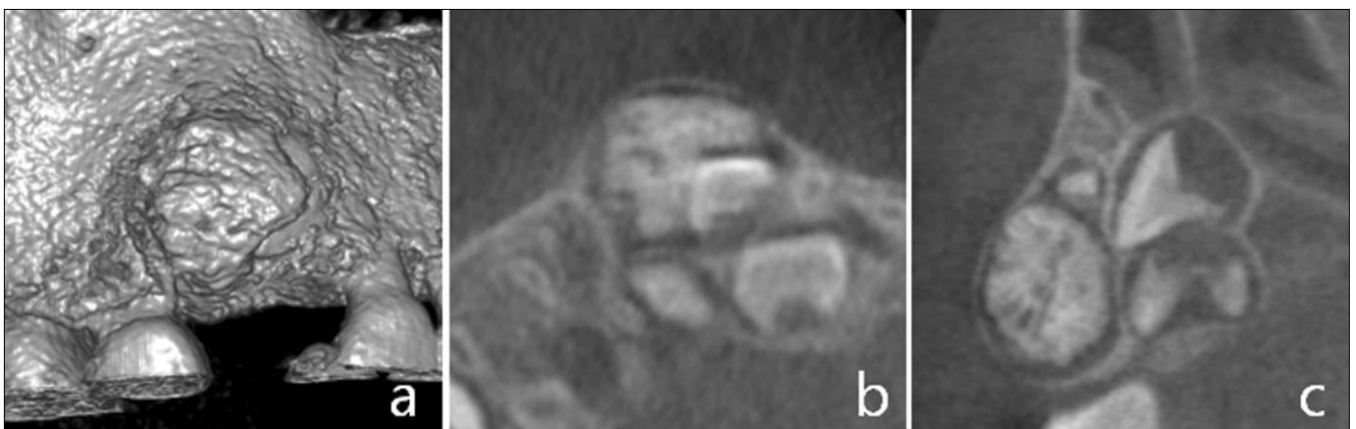


Fig. 2. 3D CT image(a), axial view(b), frontal view(c).

mobility of the deciduous canine revealed no ankylosis of this tooth. The primary canine was repositioned right under gingival level for spontaneous eruption. The removed specimen consisted of a 1.5cmdiameter oval-shaped irregular light gray hard tissue mass. After removal of the lesion, histopathological examination of the tissue confirmed the final diagnosis of complex odontoma(Fig. 3). The tissue section consisted largely of mature tubular dentin. This dentin enclosed clefts or hollow

circular structures that contained mature enamel that was removed during decalcification. Small remnants of odontogenic epithelial islands that had undergone keratinization and cell death from local anoxiawere present in the dentin (Fig. 4). After six months, routine follow-up was conducted, showing spontaneous eruption of the right maxillary primarycanine close to the occlusal plane, and no recurrence was seen(Fig. 5).

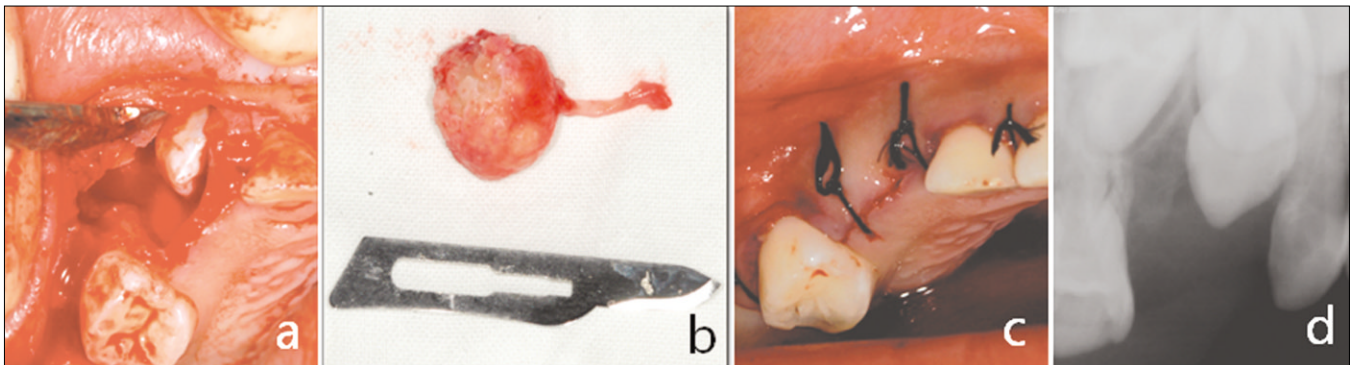


Fig. 3. Surgical operation(a), surgically removed complex odontoma (b, size 1.5×1.5×1) postoperative intraoral view(c), postoperative periapical view(d).

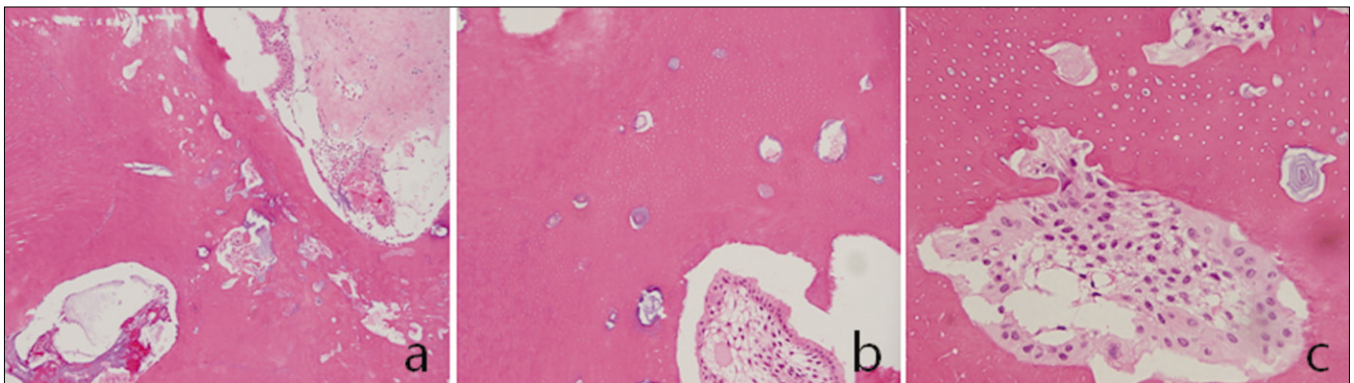


Fig. 4. Complex odontoma(a, H&E stain, ×100) this specimen consist largely of mature tubular dentin(b, H&E stain, ×200) small islands of eosinophilic-staining epithelial ghost cells(c, H&E stain, ×400).

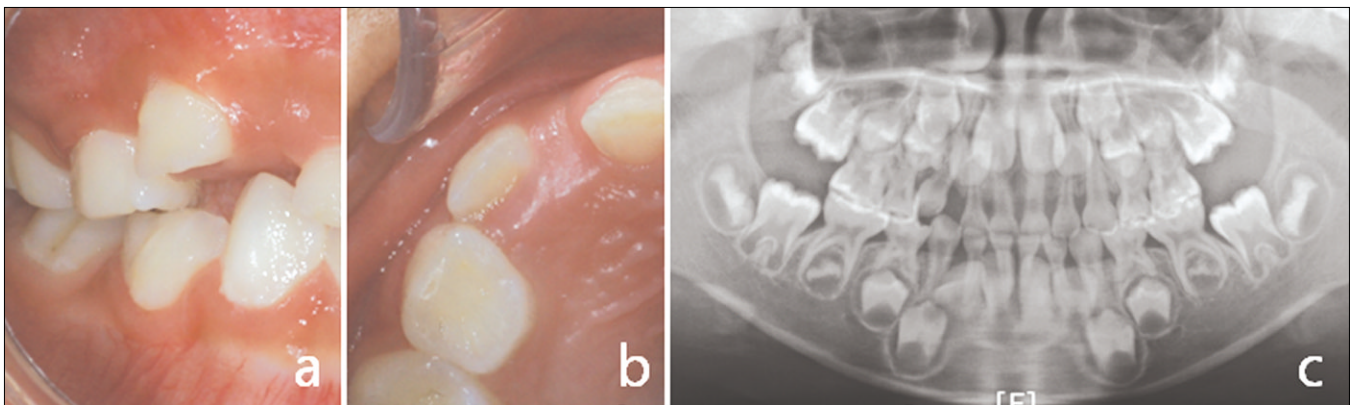


Fig. 5. 6 months later intraoral view(a, b), panoramic view(c).

Ⅲ. Discussion

Odontomas are the most common type of odontogenic tumors and are considered to be a kind of hamartoma rather than a true neoplasm⁹⁾. Odontomas are defined as mixed tumors composed of odontogenic epithelium and mesenchymal tissue. The lesions are associated with varying degrees of morphodifferentiation or histodifferentiation and are mostly associated with the permanent teeth of teenagers and very rarely associated with deciduous teeth. Impaction of teeth or delayed eruption due to odontoma in primary dentition is unusual^{10,11)}.

Radiographically, complex odontomas appear as clearly outlined, unilocular, dense radiopaque/radiolucent mixed lesions surrounded by a thin radiolucent zone. The lesion can be differentiated from other fibro-osseous lesions because they usually present as a non-homogeneous radiopacity and are almost always solitary lesions. The differential diagnosis includes calcifying odontogenic cyst, adenomatoid odontogenic tumor and ameloblastic fibro-odontoma¹²⁾. Calcifying odontogenic cysts are found frequently in the incisor and canine areas and are very similar to odontomas and ameloblastic fibro-odontomas. This radiolucent lesion is associated with an unerupted tooth, especially a canine, and either irregular calcifications or tooth-like densities, with radiopaque structures within the lesion being present in about one-third to one-half of cases. The lesion is often asymptomatic, although it may cause a painless expansion of the buccolingual corticoid bone. Adenomatoid odontogenic tumors of odontogenic origin have a striking tendency to occur in and around the crowns of unerupted incisors and to appear as well-defined radiolucencies. They are most often seen in female teenagers and are frequently asymptomatic, often containing fine-snowflake calcifications, although this is an inconstant finding. Ameloblastic fibro-odontomas have been defined recently as a tumor with the general features of an ameloblastic fibroma's soft tissue component also containing the hard tissue components of complex odontomas. The lesion is usually encountered in children. Ameloblastic fibro-odontomas share many common clinical features with complex odontomas but are differentiated by progressive tumor growth, causing considerable deformity and bone destruction. The lesion is commonly asymptomatic and is associated with unerupted teeth. It is easily enucleated from the bone because of its fibrous capsule, but careful enucleation is still recommended because several in-

stances of recurrence have occurred when tissue from the lesion is not completely extracted^{2,9)}. The differential diagnosis should include mature fibro-osseous lesions like cementoblastoma. Complex odontomas can be differentiated from fibro-osseous lesions, because they usually present as a non-homogeneous radiopacity and as a solitary lesion¹³⁾.

Odontomas are usually asymptomatic but can cause abnormal development and eruption failure of adjacent teeth. Many cases including defects of enamel, malposition of the tooth bud, impaction of teeth and prolonged retention of primary teeth have been observed when odontomas are in close proximity with a developing tooth bud¹⁴⁾.

Occasionally, painless swelling, displacement of erupting teeth, secondary fever by infection, pain and suppuration are observed.

Odontomas are well encapsulated and can be enucleated easily from the surrounding bone¹⁵⁾. Generally, treatment of odontoma is conservative local excision and the prognosis is excellent. Treatment and prognosis are decided according to the developmental stage at which the lesion is found. Through the use of visual, radiologic and histologic findings after removal of the lesion by conservative local excision, the patient was finally diagnosed with a complex odontoma.

Spontaneous eruption of the impacted tooth can be expected after surgical removal of the odontoma, although eruption failure can be expected if the dental root formation of an impacted tooth is not complete. A lot of factors can affect spontaneous eruption of impacted tooth. Such factors as axial inclination of impacted teeth, lack of space in the dental arch, degree of root formation, relation to the adjacent teeth roots, initial vertical position of impaction affects process of spontaneous eruption^{16,17)}. When lack of spontaneous eruption is apparent after surgical removal of odontomas or at complete formation of the root of the impacted tooth, additional surgical uncovering to expose the impacted tooth and orthodontic forced-eruption appliances are needed¹⁸⁾.

Of course, these treatment methods always assume that sufficient space for eruption of the impacted tooth is available before the surgery. If insufficient space for eruption of the impacted tooth is observed, the lost arch space should be regained through preoperative orthodontic treatment prior to surgery¹⁹⁾. In this case, the inclination of maxillary primary canine was normal and the stage of root formation was Nolla stage 7~8. The space

in the dental arch was enough. After six months, we were able to show spontaneous eruption of the repositioned maxillary primary canine.

IV. Summary

This report presents a case of a patient with impaction of a maxillary primary canine by a complex odontoma in which surgical excision of the lesion was performed. The importance of present case report is that the treatment of impacted primary canine by odontoma has become simple without extraction or orthodontic treatment because of only six-month wait-and-see period. We postponed the orthodontic treatment and had once again six-month wait-and-see period after surgical excision of odontoma to allow the normal eruption by physiologic tooth movement. Follow-up after six months showed spontaneous eruption of the repositioned maxillary primary canine.

References

1. Kaneko M, Fukuda M, Sano T, et al.: Microradiographic and microscopic investigation of a rare case of complex odontoma. *Oral Surg Oral Med Oral Pathol Oral Radiol Endod*, 85:131-134, 2008.
2. Shafer WG, Hine MK, Levy BM: A textbook of oral pathology, 4th ed. WB Saunders Company, Philadelphia, 308, 1983.
3. Morning P : Impacted teeth in relation to odontomas. *Int J Oral Surg*, 9:81-91, 1980.
4. Oliveira BH, Campos V : Compound odontoma-diagnosis and treatment: three case reports. *Pediatr Dent*, 23:151-7, 2001.
5. Owens BM, Schuman NJ, Mincer HH, et al.: Dental odontomas: a retrospective study of 104 cases. *J Clin Pediatr Dent*, 21:261-264, 1997.
6. Marchetti C : Some informations on dental tissues obtained from observations on a complex odontoma. *Acta Anat*, 147:40-44, 1993.
7. Rad AS, Reid J : Delayed eruption of a permanent molar associated with a complex odontoma: report of case. *ASDC J Dent Child*, 63:299-301, 1996.
8. Kaban LB, Troulis MJ : Pediatric oral and maxillofacial surgery. WB Saunders Company, Philadelphia, 140, 2004.
9. Neville BW, Damm DD, Allen CM, et al. : *Oral & Maxillofacial Pathology*, 2nd ed. WB Saunders Company, Philadelphia, 631, 2002.
10. Ozeç I, Kiliç E, Yeler H, et al. : Large complex odontoma associated with a primary tooth. *Quintessence Int*, 38:521-524, 2007.
11. Sheehy EC, Odell EW, Al-Jaddir G : Odontomas in the primary dentition: literature review and case report. *J Dent Child*, 71:73-76, 2004.
12. Hisatomi M, Asaumi JI, Konouchi H, et al. : A case of complex odontoma associated with an impacted lower deciduous second molar and analysis of the 107 odontomas. *Oral Dis*, 8:100-105, 2002.
13. Piattelli A, Perfetti G, Carraro A : Complex odontoma as a periapical and interradicular radiopacity in a primary molar. *J Endod*, 22:561-563, 1996.
14. Thwaites MS, Camacho JL : Complex odontoma: report of case. *ASDC J Dent Child*, 54:286-288, 1987.
15. Chuong R, Kaban LB : Diagnosis and treatment of jaw tumors in children. *J Oral Maxillofac Surg*, 43:323-332, 1985.
16. Witsenburg B, Boering G, Witsenburg B : Eruption of permanent impacted incisor after removal of supernumerary teeth. *Int J Oral Surg* 10:423-431, 1981.
17. Mason C, Azam N, Holt R, et al. : A retrospective study of unerupted maxillary incisors associated with supernumerary teeth. *Br J Oral Maxillofac Surg*, 38:62-65, 2000.
18. Shulman ER, Corio RL : Delayed eruption associated with an odontoma. *ASDC J Dent Child*, 54:205-207, 1987.
19. Kokich VG, Mathews DP : Surgical and orthodontic management of impacted teeth. *Dent Clin North Am*, 37:181-204, 1993.

국문초록

복잡 치아종 제거 후 변위된 매복 상악 유견치의 자가 맹출

박소연¹ · 김수경² · 최성철¹ · 김광철¹ · 박재홍¹

¹경희대학교 치과대학 소아치과학교실 및 구강생물학교실,

²다솜유니버시티

복잡 치아종은 치아와 해부학적인 유사성이 없는 범랑질, 상아질, 백악질의 덩어리로 구성되어 있다. 이 병소의 대부분은 증상이 없어 일상적인 방사선 검사나 치아의 맹출 실패의 원인을 감별하기 위한 검사를 통해 발견된다. 복합 치아종은 골 팽창을 보이는 경우가 드물지만, 복잡 치아종은 경미하거나 뚜렷한 골 팽창을 보인다. 복잡 치아종은 거의 영구치와 연관되어 있고 유치와 연관된 경우는 매우 드물다. 이는 보통 하악의 유구치 부위에 발생한다.

본 증례는 상악 유견치의 매복과 연관된 복잡 치아종을 외과적 방법으로 제거하고 자가맹출을 용이하게 하기 위해 치은 하방에 재위치 시켰다. 수술 6개월 후에 상악 유견치가 자가 맹출되었으므로 이를 보고한다.

주요어: 치아종 제거, 매복치, 자가 맹출

www.kci.go.kr