

Orthodontic Treatment of a Child with Short Root Anomaly : a Case Report

Jeongeun Lee, Jewoo Lee, Gayoung Shin, Soyoun An, Jihyun Song, Jiyoung Ra

Department of Pediatric Dentistry, College of Dentistry, Wonkwang University

Abstract

Short root anomaly (SRA) is very rare, but can be problematic for physicians because patients with SRA are more vulnerable to root resorption with orthodontic forces. During the mixed dentition period, it may be difficult to diagnose generalized SRA. This article reports the treatment of an orthodontic patient with SRA at the early mixed dentition stage. Despite local tooth loss, a relatively favorable outcome was obtained without excessive root resorption. Ultimately, orthodontic therapy is possible for patients with generalized SRA, but precautions should be taken to avoid complications, such as tooth loss or root resorption.

Key words : Short root anomaly, Mixed dentition, Orthodontic treatment, Root resorption, Tooth loss

I . Introduction

In 1972, Lind¹⁾ discovered short root anomaly (SRA) in a Swedish population, and defined the condition as being characterized by an abnormally short and blunt root shape, affecting mainly the maxillary central incisors. SRA is typically diagnosed based on the crown-to-root ratio when the root length is equal to or smaller than the crown length^{1,2)}. The estimated prevalence of SRA is 1.3~2.7%²⁾. It shows familial occurrence, and hereditary characteristics have been reported in studies of parents and siblings^{2,3)}. Apajalahti *et al.*²⁾ suggested that SRA affected only the permanent teeth, based on the absence of reports on SRA in the primary teeth. SRA typically affects the maxillary central incisors, but some-

times the premolars¹⁾. Rarely, generalized SRA may affect the entire dentition⁴⁻⁶⁾.

Orthodontic forces can occasionally result in root resorption, and the risk increases with a short root^{1,7-9)}. Orthodontic therapy often begins in the mixed dentition period in growing children. Unfortunately, root formation is incomplete at this stage, which makes diagnosis difficult with radiographs alone.

Here, we present a case involving orthodontic treatment performed in a patient at the early mixed dentition stage, when the identification of SRA is most challenging. This report highlights the importance of the early detection of SRA and precautions needed during orthodontic procedures. Informed consent was obtained from the patient's parents for publication of this report.

Corresponding author : Jiyoung Ra

Department of Pediatric Dentistry, College of Dentistry, Wonkwang University, 895 Moowang-ro, Iksan, Jeollabuk-do, 54538, Korea

Tel: +82-63-850-6633 / Fax: +82-63-851-5324 / E-mail: pedojoy@wku.ac.kr

Received August 12, 2015 / Revised September 22, 2015 / Accepted September 11, 2015

※ This research was supported by Wonkwang University, in 2013.

II. Case report

A boy, age 9 years, 5 months, visited the pediatric dental clinic at Wonkwang University Dental Hospital. His parents reported that the permanent lateral incisors had not erupted since he had lost the primary teeth 2 years previously. There was sufficient space for the successors. The four erupted mandibular incisors seemed to complete apical closure with relatively short roots. The mandibular primary second molars formed an infraocclusion due to ankylosis. The ectopic eruption of the first molars bilaterally had resulted in space deficiency for the second premolars (Fig. 1). His primary second molars had been extracted bilaterally 1 - 2 years previously. After oral screening, it was decided that orthodontic intervention would be initiated on eruption of the maxillary lateral incisors because there had been no space to arrange permanent maxillary premolars.

At the patient's next visit, 8 months later, we found that the maxillary left lateral incisor had erupted, but the right one had not, showing no significant change from the initial radiograph (Fig. 2). A treatment plan was established using a removable appliance to move the first molars distally, followed by a fixed appliance. The patient had early mixed dentition, and root development of the permanent teeth appeared incomplete overall. Consequently, the treatment was performed with great care to avoid an openbite, injury, or anchorage loss in the anterior teeth.

At first, the removable orthodontic appliance with bilateral screws was used to induce distalization of maxillary first molars. Especially, the screws were activated one by one unilaterally because of concern about weak

anchorage. Nine months later, excessive overjet was observed. The use of the anterior teeth as an anchorage was stopped at this point, and fixed appliance with cervical headgear was adopted to allow distal traction using of extra-oral force. Initially, brackets were applied to maxillary four incisors and bilateral first molars. With the eruption of other teeth, brackets were attached sequentially. While a series of orthodontic wires universally applicable for Straight-Wire Appliance (SWA) system was used, every wire was kept for longer time than in usual cases. At this time, we could identify dens invaginatus clearly with periapical radiographs of maxillary lateral incisors (Fig. 3). The treatment with the headgear and fixed appliance continued for about 1 year, and then the second premolars were found to be locked in the mesial area of the first molars. Resorption of the first molars was suspected, which prompted surgical exposure and orthodontic traction of the second premolars (Fig. 4).

Toward the end of the teeth alignment, pinkish discoloration was observed on the maxillary left first molar, and radiographs indicated signs of internal resorption on its mesial side (Fig. 5). Based on consultation with the Department of Operative Dentistry at our institute, conservation therapy was infeasible due to signs of invasive resorption. Therefore, the tooth was extracted, and mesial eruption of the second molar was induced (Fig. 6).

The treatment lasted for approximately 3 years. Although the alignment of the maxillary dentition was completed, the left first molar was unfortunately lost. For nearly 2 years, the teeth has shown no significant mobility or root resorption since the treatment had been finished (Fig. 7).

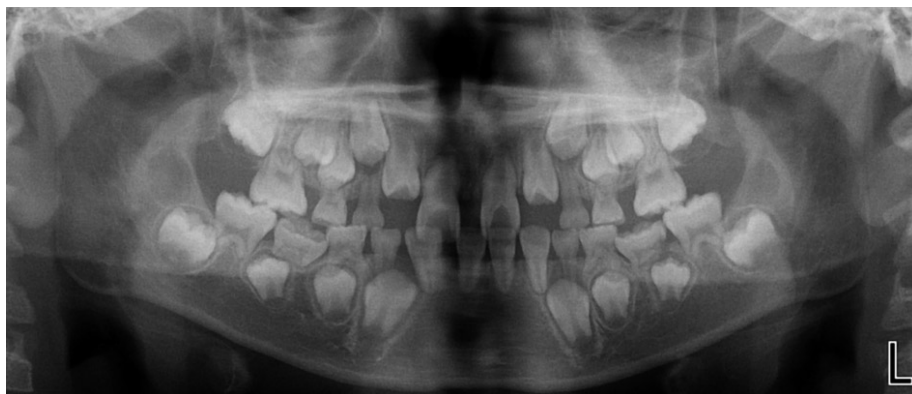

Fig. 1. Panoramic radiograph at first examination.

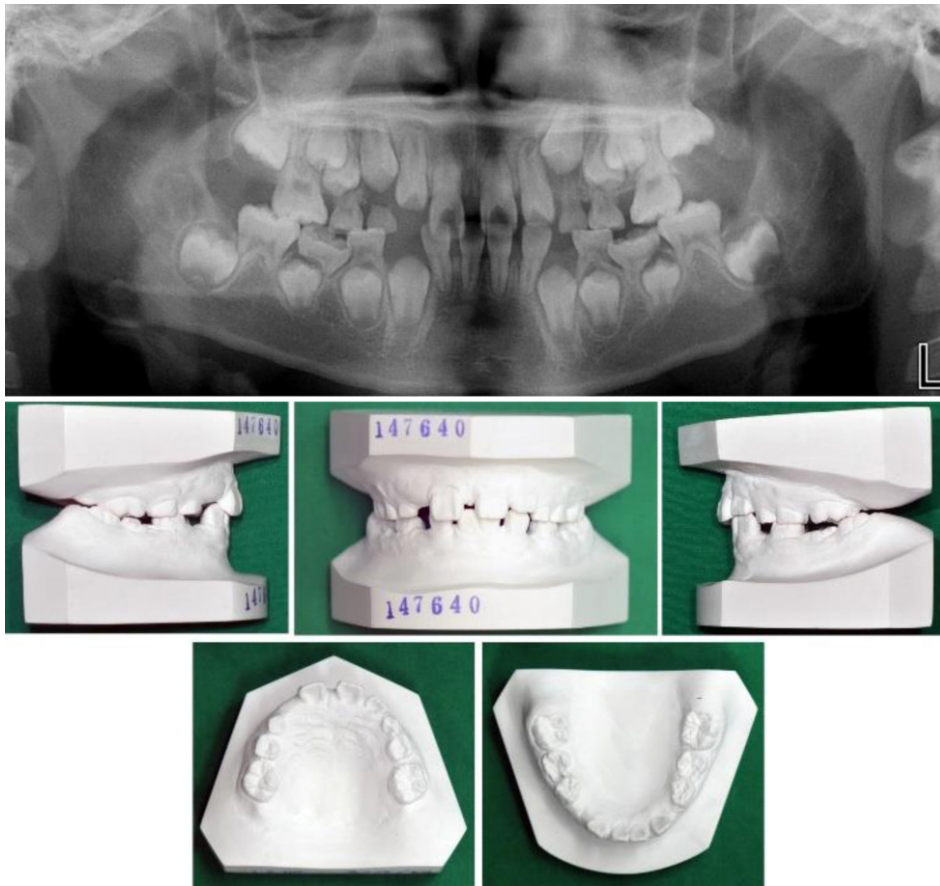


Fig. 2. Pretreatment panoramic radiograph and cast models.

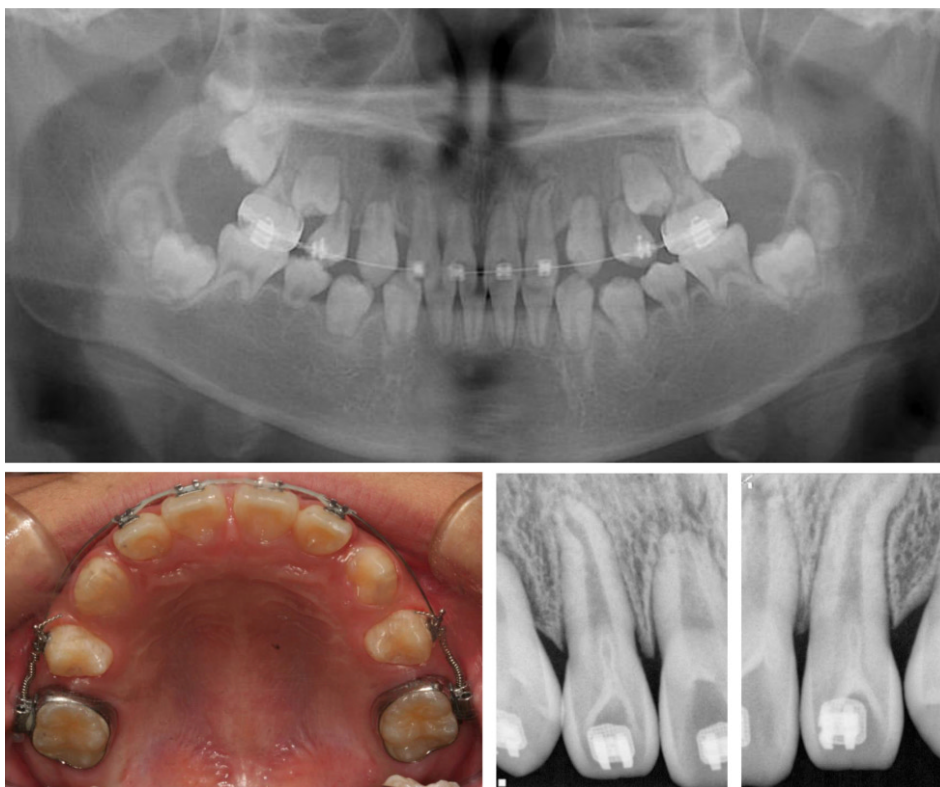


Fig. 3. During treatment; intraoral appliance for headgear and dens invaginatus of maxillary lateral incisors.

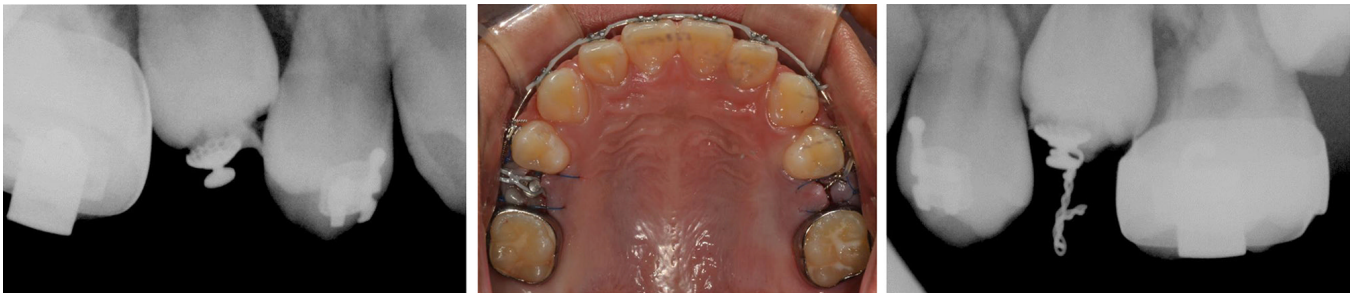

Fig. 4. Surgical exposure and orthodontic traction of second premolars.

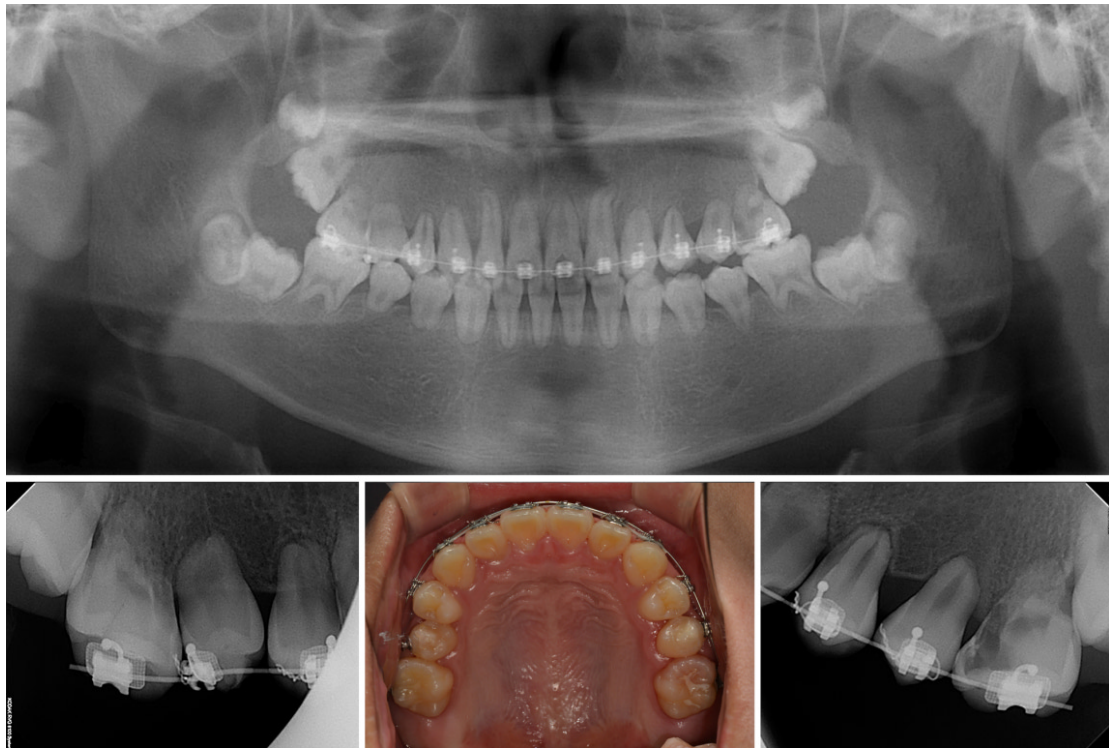


Fig. 5. Internal root resorption of maxillary left first molar.

III. Discussion

This patient was unique in having idiopathic generalized SRA, which was not associated with any related systemic disease or family history. Idiopathic SRA is rare and difficult to predict. There have been several case reports on idiopathic generalized SRA accompanied by microdontia, taurodontia, dens invaginatus, agenesis, an ectopic canine, and obliteration of the pulp^{10,11}. In this patient, the initial radiographs showed ectopic eruption and ankylosis, and indicated that the apical shape of the incisors and first molars differed from that of the normal

immature permanent teeth. In addition, dens invaginatus of the maxillary lateral incisors were observed.

In a recent case report, tooth anomalies such as short root formation, abnormal shape of crown or root, and hypoplasia of enamel were assumed to be caused by epigenetic factors, such as damage, infection, medication exposure during the first 2 years of life, or damage at birth, especially damage affecting the central nervous system¹². These events tended to match the time of development and damage to the teeth. However, our case involved a systemic anomaly, which appeared unconnected to such factors.

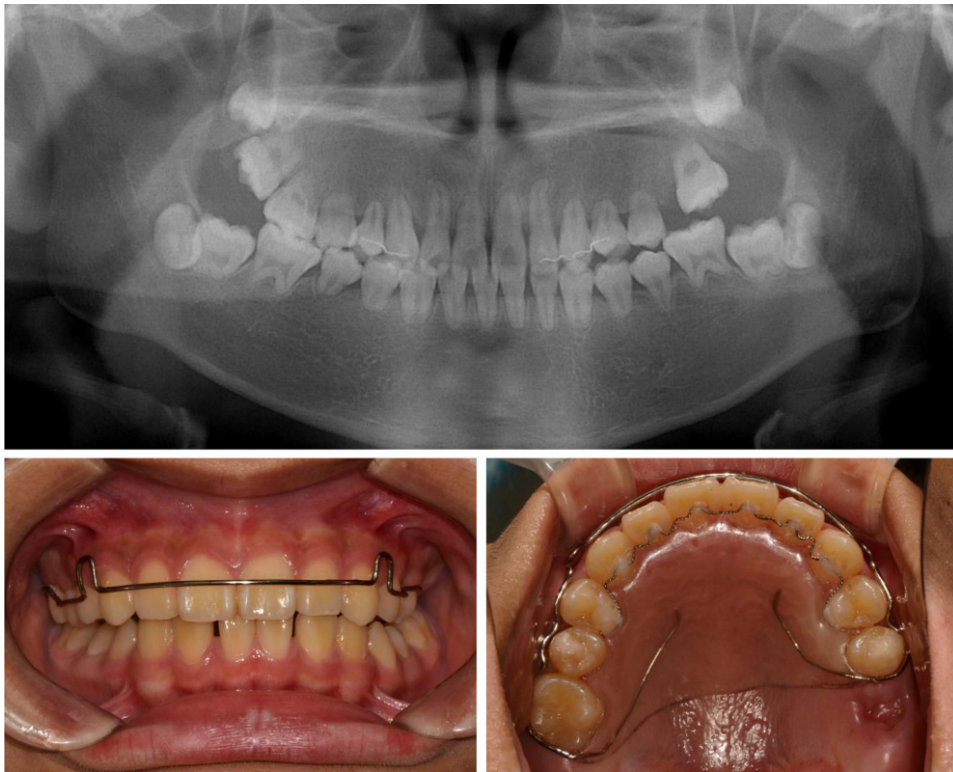


Fig. 6. After treatment; panoramic radiograph and intraoral photograph with a removable retainer.

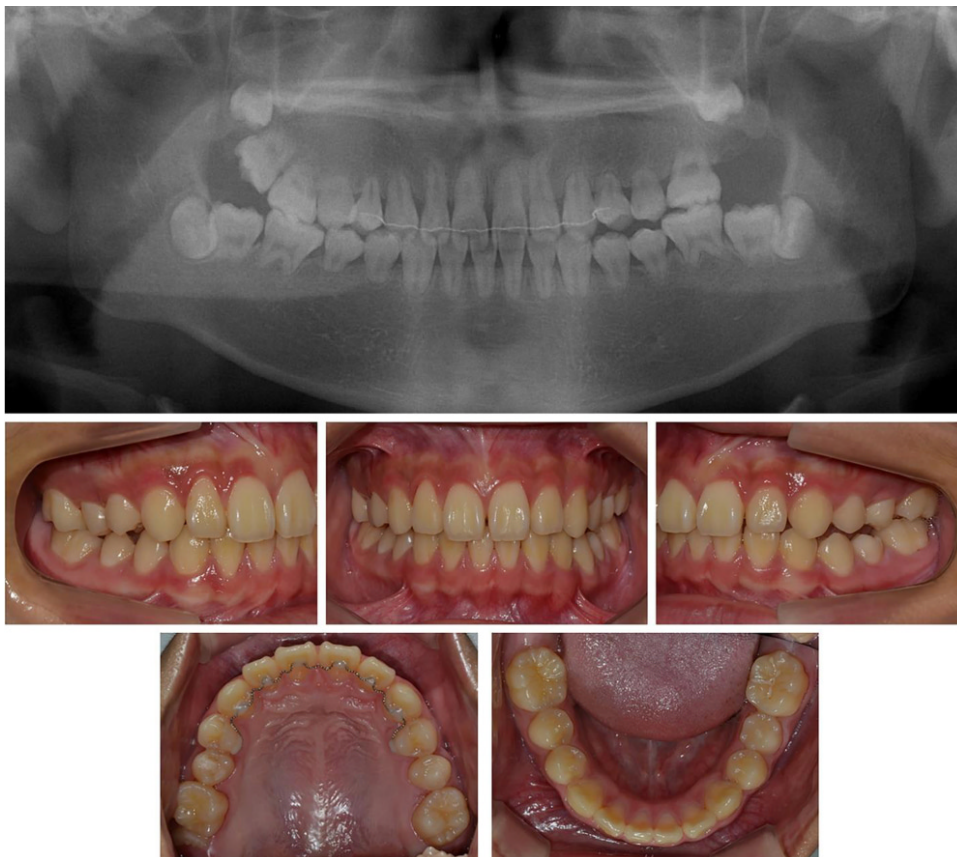


Fig. 7. Follow-up examination of 19 months.

Several animal studies have identified various genes associated with root development, including *Msx2* (*msh homeobox 2*), *Sp6* (*transcription factor*), *Shh* (*sonic hedgehog*), and *Nog* (*noggin*)^{13,14}. In particular, the *Nfic* (nuclear factor 1c) gene encodes a regulator that controls root dentin formation and is involved in odontoblast differentiation. The absence of this gene resulted in abnormal short roots in *Nfic*-mutant mice^{6,14,15}.

SRA has also been shown to be associated with other syndromes and systemic diseases^{11,16}. If the related factors mentioned above cannot be identified, the prediction of SRA in mixed dentition showing immature permanent teeth is very challenging. The patient's parents knew of no relevant family history and did not want to undergo further medical evaluation. Since there was no further evaluation, a potential relationship with a systemic disease or specific gene cannot be ruled out.

Teeth with short roots are at greater risk of root resorption, caused by orthodontic forces⁷⁻⁹. One study of the distribution of the orthodontic force using finite element methods showed that significant stress concentration occurs in the middle area of short roots, generating sufficient strength to trigger root resorption¹⁷.

Some clinicians believe that orthodontic therapy is still possible for SRA patients, except in severe cases^{4,5}. They insist that the risk of resorption can be controlled with clinical and radiological monitoring in most cases^{4,18}. Precautions should be taken at all stages of orthodontic procedures. Lighter force needs to be applied because the center of resistance is closer to the crown than that of a normal tooth and the momentum/force ratio is easily affected⁴. Light, intermittent force may control resorption¹⁹. To allow sufficient time to repair the resorption, longer intervals between the activation of force are required²⁰. Splints can be applied to ensure the stability of local SRA teeth, if needed^{14,21}. Furthermore, in localized SRA, treatment methods that do not exert excessive force on the affected teeth should be considered. Orthopedic appliances, such as headgear or activators, can be used if the timing is appropriate. There is a referential report of a patient with class II malocclusion who underwent orthodontic treatment before the growth spurt and a desirable outcome was achieved using headgear without further damage to the maxillary central incisors in SRA²¹.

Unfortunately, our patient had generalized, not localized, SRA so this strategy could not be used. A removable appliance was used with the anterior teeth as an-

chors during the early stages of treatment, and it was subsequently replaced by headgear to apply an extraoral force. In addition, light forces and a prolonged activation interval were applied as much as possible throughout the treatment. Without the use of the headgear, other anchor teeth may have been lost, leading to an unsuccessful result. Ultimately, this patient lost his left first molar, but coped with the associated complications by compensatory mesial eruption of the second molar. Furthermore, root development did not progress normally during the treatment period, and similar short roots were observed in the untreated mandibular dentition. This indicated a general state of arrested root formation, rather than iatrogenic root resorption caused by the orthodontic treatment.

Lind¹ stated that SRA has not received sufficient attention for several reasons. He mentioned that it could easily be misdiagnosed as root resorption because of a lower prevalence in Caucasians. SRA is more prevalent in Asians than Caucasians and ~10% of Japanese children with an average age of 9 years had central incisors with short roots²². However, the prevalence of SRA has been increasing in the USA recently, and Puranik *et al.*²³ suggested that this trend could be associated with the growing Latino population in the US. Moreover, teeth with SRA are generally asymptomatic, except in severe cases, with a normal crown shape and size, and related symptoms are usually absent. Unless excessive mobility or loss of teeth develops, SRA cannot be confirmed without radiographs. Valladares *et al.*⁴ wrote that differential diagnosis should be carried out to distinguish SRA from other conditions such as incomplete root formation, external apical root resorption, dentin dysplasia type I, and post-trauma root hypoplasia.

Although the diagnosis of SRA can be missed easily for the reasons mentioned above, it should not be overlooked. The resistance against root resorption is lower, and the risk of tooth loss due to oral diseases is higher. The early detection of SRA is important and proper precautions must be taken during treatment. Further studies of SRA itself are required, as well as case reports on orthodontic, conservative, and periodontal treatment in SRA patients.

IV. Summary

This case confirms that orthodontic therapy is possible for SRA patients, but should be conducted with care. If

SRA is confirmed during orthodontic treatment, a temporary cessation of treatment and appropriate modification of the treatment plan are required. Most importantly, the possibility of SRA in children should be evaluated with thorough assessments of the family history, systemic disease, and other dental anomalies before beginning orthodontic treatment.

References

- Lind V : Short root anomaly. *Scand J Dent Res*, 80: 85-93, 1972.
- Apajalahti S, Hölttä P, Turtola L, Pirinen S : Prevalence of short-root anomaly in healthy young adults. *Acta Odontol Scand*, 60:56-59, 2002.
- Šikanjić PR, Meštrović S : A case of short-root anomaly in a female from medieval Istria. *Int J Osteoarchaeol*, 16:177-180, 2006.
- Valladares Neto J, Rino Neto J, de Paiva JB : Orthodontic movement of teeth with short root anomaly: Should it be avoided, faced or ignored? *Dental Press J Orthod*, 18:72-85, 2013.
- Edwards DM, Roberts GJ : Short root anomaly. *Br Dent J*, 169:292-293, 1990.
- Park JC, Herr Y, Kim HJ, Gronostajski RM, Cho MI : Nfic gene disruption inhibits differentiation of odontoblasts responsible for root formation and results in formation of short and abnormal roots in mice. *J Periodontol*, 78:1795-1802, 2007.
- Sameshima GT, Sinclair PM : Characteristics of patients with severe root resorption. *Orthod Craniofac Res*, 7:108-114, 2004.
- Mirabella AD, Artun J : Risk factors for apical root resorption of maxillary anterior teeth in adult orthodontic patients. *Am J Orthod Dentofacial Orthop*, 108:48-55, 1995.
- Sameshima GT, Sinclair PM : Predicting and preventing root resorption: part I. Diagnostic factors. *Am J Orthod Dentofacial Orthop*, 119:505-510, 2001.
- Apajalahti S, Arte S, Pirinen S : Short root anomaly in families and its association with other dental anomalies. *Eur J Oral Sci*, 107:97-101, 1999.
- Desai RS, Vanaki SS, Nidawani P, et al. : An unusual combination of idiopathic generalized short-root anomaly associated with microdontia, taurodontia, multiple dens invaginatus, obliterated pulp chambers and infected cyst: a case report. *J Oral Oathol Med*, 35:407-409, 2006.
- Lee HS, Kim SH, Song JS, et al. : A new type of dental anomaly: molar-incisor malformation (MIM). *Oral Surg Oral Med Oral Pathol Oral Radiol*, 118:101-109, 2014.
- Bei M : Molecular genetics of tooth development. *Curr Opin Genet Dev*, 19:504-510, 2009.
- Huang XF, Chai Y : Molecular regulatory mechanism of tooth root development. *Int J Oral Sci*, 4: 177-181, 2012.
- Gronostajski RM : Roles of the NFI/CTF gene family in transcription and development. *Gene*, 249:31-45, 2000.
- Roinioti TD, Stefanopoulos PK : Short root anomaly associated with Rothmund-Thomson syndrome. *Oral Surg Oral Med Oral Pathol Oral Radiol Endod*, 103: e19-22, 2007.
- Oyama K, Motoyoshi M, Shimizu N, et al. : Effects of root morphology on stress distribution at the root apex. *Eur J Orthod*, 29:113-117, 2007.
- Tanaka OM, Knop LH, Shintcovsk RL, Hirata TM : Treatment of a patient with severely shortened maxillary central incisor roots. *J Clin Orthod*, 42:729-731, 2008.
- Levander E, Malmgren O, Eliasson S : Evaluation of root resorption in relation to two orthodontic treatment regimes. A Clinical experimental study. *Eur J Orthod*, 16:223-228, 1994.
- Cheng LL, Türk T, Darendeliler MA, et al. : Repair of root resorption 4 and 8 weeks after application of continuous light and heavy forces on premolars for 4 weeks: a histology study. *Am J Orthod Dentofacial Orthop*, 138:727-734, 2010.
- Marques LS, Generoso R, Armond MC, Pazzini CA : Short-root anomaly in an orthodontic patient. *Am J Orthod Dentofacial Orthop*, 138:346-348, 2010.
- Ando S, Kiyokawa K, Sanka Y, et al. : Studies on the consecutive survey of succedaneous and permanent dentition in the Japanese children. Part 4. Behavior of short rooted teeth in the upper bilateral central incisors. *J Nihon Univ Sch Dent*, 9:67-80, 1967.
- Puranik CP, Hill A, Frazier-Bowers SA, et al. : Characterization of short root anomaly in a Mexican cohort-hereditary idiopathic root malformation. *Orthod Craniofac Res*, 18:62-70, 2015.

국문초록

Short root anomaly (SRA) 환자의 교정적 처치 증례

이정은 · 이제우 · 신가영 · 안소연 · 송지현 · 라지영

원광대학교 치과대학 소아치과학교실

Short root anomaly (SRA)는 매우 드문 질환으로, 교정력에 의한 치근흡수에 있어서 정상적인 치아보다 더 취약하므로 처치시에 어려움이 있다. 또한, 혼합치열기 시기에 나타나는 전반적인 SRA의 경우는 진단 또한 쉽지 않다. 초기 혼합치열기 환아에서 방사선 사진만으로 전반적인 SRA를 예측하기 어렵지만, 가족력이나 관련 전신질환, 또는 구강 내 다른 치아이상 (tooth anomaly) 등의 요소가 있는 경우, SRA를 염두에 두어야 한다.

본 증례는 전악에 걸쳐 SRA를 보이는 초기 혼합치열기 환자의 교정적 처치를 다루었다. 비록 국소적인 치아 상실이었으나 적절한 교정적 배열을 통해 더 이상의 과도한 치근흡수 없이 치료를 마무리 하였으며, 비교적 양호한 치료 결과를 얻었기에 이를 보고하고자 한다. 결론적으로, SRA 환자에서도 교정 치료가 가능하며, SRA가 예측되는 혼합치열기 환아에서 치근흡수나 치아상실과 같은 합병증이 나타나지 않도록 특히 주의를 기울여야 한다.

주요어: Short root anomaly, 혼합치열기, 교정적 처치, 치근흡수, 치아상실

www.kci.go.kr