

## Fracture of a Dental Needle during Inferior Alveolar Nerve Block in a Young Child: A Case Report

Hanbyeol Lee<sup>1</sup>, Minkeun Kim<sup>2</sup>, Howon Park<sup>1</sup>, Hyunwoo Seo<sup>1</sup>, Juhyun Lee<sup>1</sup>

<sup>1</sup>*Department of Pediatric Dentistry and Oral Science Research Center, College of Dentistry, Gangneung-Wonju National University*

<sup>2</sup>*Department of Oral and Maxillofacial Surgery and Oral Science Research Center, College of Dentistry,  
Gangneung-Wonju National University*

### Abstract

The fracture of a needle during local anesthesia in dental treatment is rare; however, when it occurs, the needle should be removed without damage to surrounding structures as soon as possible. A fractured needle fragment that is buried in soft tissue would be difficult to remove, and a careful surgical procedure under general anesthesia is recommended in such cases.

Children who require dental treatment are often not capable of cooperative behavior, thus unexpected movements can increase the risk of needle fracture. Clinicians can reduce the incidence of needle fracture accidents with a few precautions.

In the present case report, we report a case of needle fracture due to abrupt movement during inferior alveolar nerve block anesthesia in a young child, with the purpose of drawing attention to needle fracture incidents. This report describes the possible causes and prevention methods of local anesthetic needle fracture, and the localization methods and surgical procedure for needle fragment removal.

**Key words :** Local anesthetic needle fracture, Inferior alveolar nerve block, Child, Dingman mouth gag

### I . Introduction

Despite the reduced incidence of dental needle fracture since the development of disposable needles and the use of flexible materials for needle fabrication, needle fracture accidents still occur. The majority of needle fractures occur during administration of inferior alveolar nerve block, with the most common site for a fractured needle fragment being the pterygomandibular space<sup>1)</sup>.

A fractured needle fragment should be removed due to the potential danger for migration and detrimental effects to adjacent structures<sup>2)</sup>. However, removal of a

fractured needle fragment that is not observed with the naked eye is one of the most difficult procedures, and there is a need for a correct understanding of the anatomical structure surrounding the fractured needle fragment.

Children who require dental treatment are often not capable of cooperative behavior, thus unexpected movements can increase the risk of needle fracture. Therefore, a careful approach is needed when administering local anesthetics to a child, and clinicians should know the technique variations related to the smaller skull and different anatomy of a child.

Corresponding author : Juhyun Lee

Department of Pediatric Dentistry, College of Dentistry, Gangneung-Wonju National University, 7, Jukheon-gil, Gangneung, 25457, Republic of Korea

Tel: +82-33-640-2452 / Fax: +82-33-640-3113 / E-mail: ljh55@gwnu.ac.kr

Received June 29, 2015 / Revised July 17, 2015 / Accepted July 17, 2015

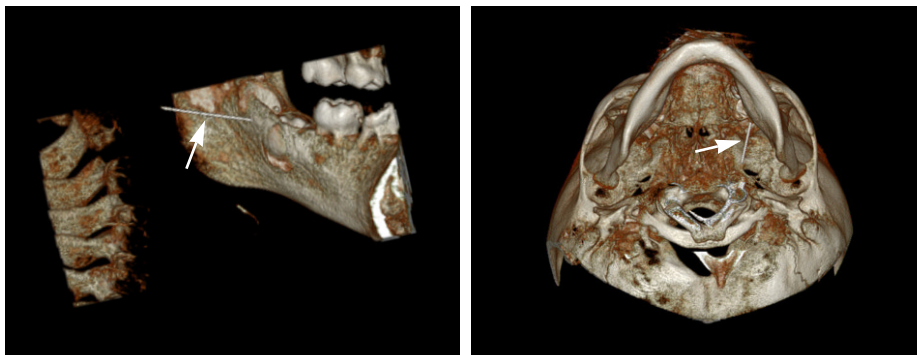
Previous reports regarding needle fracture focus mainly on localization techniques of needle fragments in adults<sup>1,3-5</sup>. Accordingly, here, we report a case of surgical retrieval of a fractured needle fragment occurring in a young child during inferior alveolar nerve block anesthesia, with a view to drawing attention to needle fracture incidents. In addition, we discuss the possible causes, management, and prevention methods of needle fracture, as well as the precautions to be taken when performing local anesthesia in children.

## II. Case report

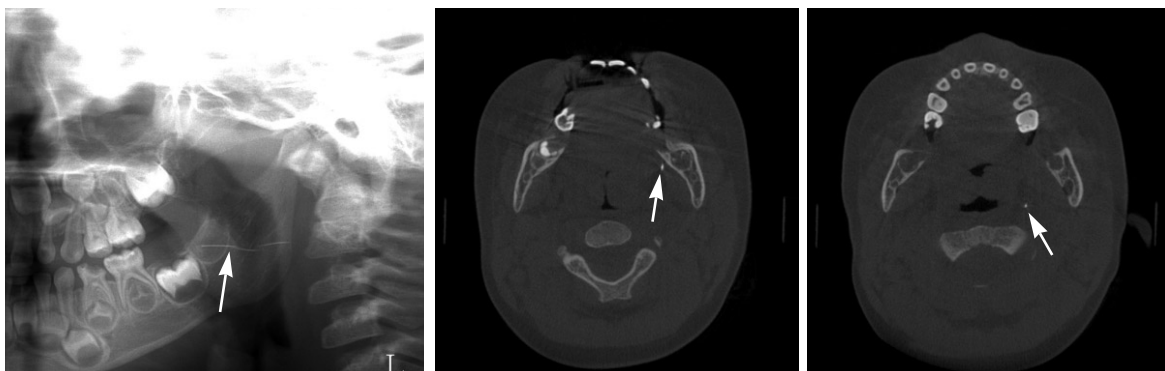
A healthy three-year, five-month-old boy with severe early childhood caries came to Department of Pediatric Dentistry of Gangneung-Wonju National University Dental Hospital in order to receive dental treatment in January 2015. His body weight was 17 kg and he was administered 1100 mg chloral hydrate and 25 mg hydroxyzine by a dental assistant. Approximately 90 min-

utes after the drugs were administered, he fell asleep. When a mouth gag was inserted into the mouth of the patient, he moved suddenly. Approximately 10 minutes after inhalation of nitrous oxide/oxygen, the mouth gag was inserted again and he did not seem to move. When a 21-mm 30-gauge needle was inserted in order to deliver the inferior alveolar nerve anesthesia, the patient suddenly tilted his head in a direction opposite to that of the needle, woke up, and struggled. The needle had fractured at the hub and the needle fragment was not visible.

Dental panoramic and computed tomographic (CT) scans with three-dimensional reconstruction were performed, which confirmed the presence of the fragment in the left pterygomandibular space adjacent to the parapharyngeal space (Fig. 1 & 2). Following discussion with the patient's caregiver, who was in office at the time of the incident, about possible risks, complications, and available options, the patient's caregiver agreed to the removal of the fractured needle fragment under general anesthesia.



**Fig. 2.** Computed tomographic scans with three-dimensional reconstruction illustrating the fractured needle fragment located at a position medial to the mandible (arrowhead).



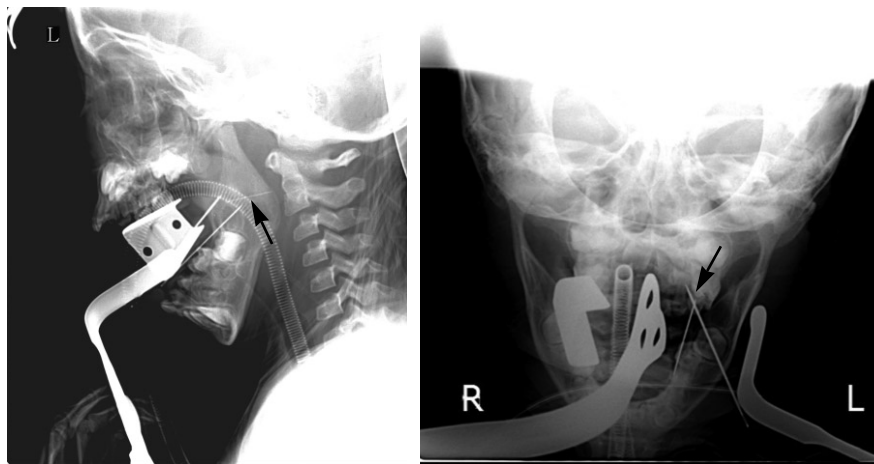
**Fig. 1.** Panoramic radiograph and axial computed tomographic scans of a patient with a fractured needle fragment in the oral cavity (arrowhead).

The following day, the patient was admitted to hospital and underwent general anesthesia for removal of the fractured needle fragment. There is always the possibility of migration of the needle fragment since the CT scan was obtained, thus, in the operating room we took a combination of lateral and anteroposterior radiographs with two reference needles inserted based on the previous CT scans, in order to determine the actual location of the fractured needle fragment (Fig. 3). To prevent migration of the needle, we decided to find the middle portion of the needle, and a dingman mouth gag was put in place for better visibility and easy surgical access (Fig. 4). Infiltration of local anesthetics (2% lidocaine hydrochloride with 1:100,000 epinephrine) was carried out in the left ramus area in order to reduce the bleeding.

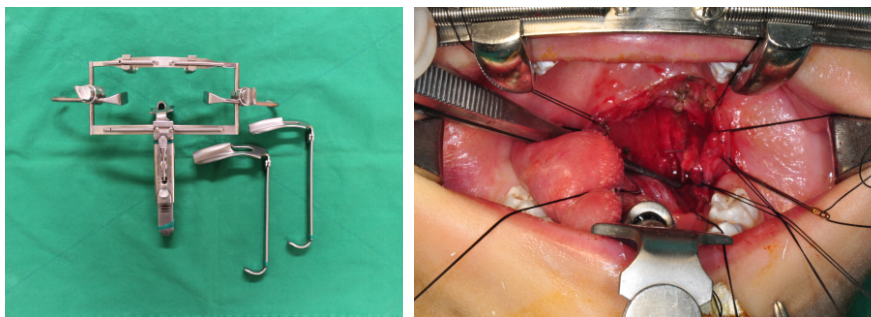
Intra-oral radiographs taken using two needles of different thickness were used for localization of the needle fragment and for determining the incision site. One needle was located in the lingual mucosa of the left mandibular second primary molar, which was used as a

fixed indicator. A second needle was inserted into the soft tissue overlying the medial border of the mandibular ramus, and the intra-oral radiograph was taken (Fig. 5). Subsequently, we made an approximate 4 cm mucosal incision from the medial side of the left retromolar pad area vertically downwards between the 2 needles in a direction almost perpendicular to the needle fragment. Careful dissection was carried out using a blunt dissection scissor and electrocautery. After moving the position of the second needle, an intra-oral radiograph was taken and the dissection was continued (Fig. 5). Finally, the needle was found and removed in one piece without any complications (Fig. 6). A Penrose drain was inserted and the mucosal incisions were sutured with 4.0 vicryl. The drain was removed after 3 days.

2 weeks later, the patient had progression of caries treatment and endodontic treatment under general anesthesia, the results confirm the surgical site was well healed without infection or complications.



**Fig. 3.** Lateral and anteroposterior radiographs with two reference needles to determine the position of the fractured needle fragment at the time of operation (arrowhead).



**Fig. 4.** Dingman mouth gag allowing for better visibility and easy surgical access in surgical procedures of the oral cavity.



Fig. 5. Intra-oral radiographs for the localization of the fractured needle fragment (arrowhead).

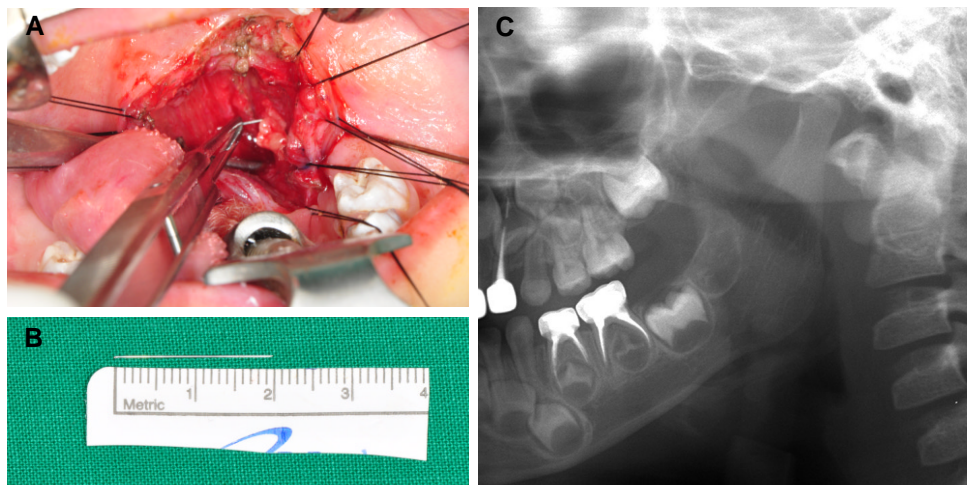


Fig. 6. Clinical photographs and post-operative panoramic radiograph. (A) Intra-oral photograph showing the needle fragment lodged in the soft tissue. (B) The removed needle fragment. (C) Postoperative panoramic radiograph showing no residual needle fragment.

### III . Discussion

In adults and children, there is a difference in the position of the mandibular foramen and in the injection depth of the needle. In adults, the mandibular foramen exists above the occlusal plan, however, in children, the foramen can be found from below the occlusal plane to the occlusal plane level<sup>2)</sup>. Previous studies have reported that the needle might be inserted approximately 21-mm deep into the soft tissue for inferior alveolar nerve block in adults, while it might be 15-mm deep in a child<sup>6,7)</sup>. Clinicians should be sure to remember these differences when delivering the inferior alveolar nerve anesthesia.

A previous case study of 31 patients, in which needle fracture during inferior alveolar nerve anesthesia was re-

ported, a 30G needle was used in 23 patients and a 27G needle was used in 8 patients<sup>1)</sup>. The dimension and length of the needle should be carefully selected depending on the situation, and insertion of the full length of the needle should be avoided. Malamed<sup>8)</sup> reported that the abrupt movement of a patient after the needle is already inserted was the major cause of needle fracture. In addition, a change in angulation of a needle that was already inserted into the tissue, would raise the risk of needle fracture. Pre-bending of the needle, particularly the hub area, may be a possible cause of needle fracture. If the needle is bent, the preset breaking point will be activated. In addition, the quality of the needle may affect the needle fracture, however, there have been no studies regarding needle quality, and further research is needed.

There are some details that need attention in order to prevent needle fracture during local anesthesia. The use of a too-thin or too-short needle should be avoided<sup>1,9)</sup>. The most common gauges of dental needles are 25, 27, and 30 gauge. The higher the gauge number, the smaller the internal diameter. As the deflection of the needle is increased, the possibility of needle fracture rises. A previous study has reported that thicker needles are less deflected compared with thinner needles, as they penetrate the soft tissue<sup>10)</sup>. There are three lengths of dental needle, long (31-mm), short (25-mm), and ultra-short (12-mm). The length of the needle should be decided by the type of injection, size of patient, and thickness of the target tissue. The hub portion of the needle should not be inserted near the mucosa, and there should be at least a 5-mm length of needle outside the tissue<sup>11)</sup>.

In the majority of pediatric patients, the 27-gauge short needle is recommended, and in most adult patients, 25-27 gauge long needle is recommended for inferior alveolar nerve block<sup>12)</sup>. In addition, the needle should not be bent prior to injection, and insertion into tissue should not change the angulation. The angle should be changed after taking the needle out of the tissue. Finally, prevention of sudden movements should be taken by explaining the possible pain to the patient, especially a child, and by controlling the patient's head.<sup>1,11)</sup>

A fractured needle fragment should be removed as soon as possible due to the potential danger for migration to adjacent structures<sup>2)</sup>. If the fractured needle is observed with the naked eye, it can be removed using a hemostat. However, if the entire length of the fractured needle fragment is embedded in the tissue, the attempt to determine the location of the needle can result in the deeper migration of the needle fragment. Moreover, the possibility of needle fragment migration can be increased by mouth movements such as swallowing and chewing. Thus, in such cases, it is recommended that at least mouth opening be minimized before removal of the needle fragment, and that removal of the needle fragment is performed under general anesthesia<sup>13)</sup>.

During removal of a foreign body from the oral cavity, the visibility of the surgical site and the identification of the exact position of the foreign body are essential. In the present case, since the fractured needle fragment was in the pterygomandibular space adjacent to the parapharyngeal space, we used a dingman mouth gag during the operation for ease of access. A dingman mouth gag is designed to retract the cheek while de-

pressing the tongue, and offers good mouth opening and anchorage for sutures. It is a useful instrument for allowing easy surgical access during surgical procedures of the mouth and tonsils<sup>14)</sup>.

Various methods are used to find a needle fragment inserted in soft tissue. CT scans with three-dimensional reconstruction are recommended to localize the needle fragment and the surrounding structures before operation. Here, we conducted the operation after confirming that the exact location of the needle fragment was in the pterygomandibular space adjacent to the parapharyngeal space, through CT scans with three-dimensional reconstruction. However, there is a possibility of migration of the needle fragment since the CT scans were obtained, thus imaging techniques with the purpose of locating the needle fragment during the operation is necessary. During the surgical procedure, plan film radiography, intra-oral radiography, magnetic resonance imaging, intraoperative fluoroscopic imaging (C-arms), and ultrasonography can be used in order to detect foreign bodies<sup>4)</sup>. In our case, we used plan film radiography (a combination of lateral and anteroposterior radiographs) and intra-oral radiography using two different thickness of needles as indicators. We could confirm the position of the fractured needle fragment correctly with these intraoperative imaging techniques.

In the present case, a 21-mm 30-gauge needle was used for injection without bending in a three-year, five-month-old boy under conscious sedation. When the needle was inserted into the tissue while the clinician stabilized the patient's head by supporting the head against the clinician's body, there was a sudden movement of the patient. As a result, the needle was inserted up into the hub, which is the most susceptible point for breakage, and needle fracture occurred. Through this, in children, there is an increased risk of sudden movement, we keep in mind that firm stabilization is very important element during local anesthesia.

If the fracture of a needle during local anesthesia occurs, the management of patient or caregiver is essential in order to prevent medical disputes. It is important to explain sufficiently to patient or caregiver and to offer an expression of sincere regret. In the present case, the caregiver was in office at the time of the incident and we were directly involved in all process including dental treatment, radiography, and surgical removal of the needle fragment. So we could easily explain the situation and get agreement on the process.

#### IV. Summary

The fracture of a needle during local anesthesia in dental treatment is rare, however when it occurs, the needle should be removed without damage to surrounding structures as soon as possible. Nevertheless, the removal of a needle fragment often requires the patient to endure traumatic surgery under general anesthesia and to be exposed to further ionizing radiation. Therefore, efforts are required to prevent needle fracture. In children, there is an increased risk of sudden movement, thus we should pay more attention even during conscious sedation, and use a sufficient dimension of needle that is not pre-bent.

#### References

1. Augello M, von Jackowski J, Gratz KW, Jacobsen C : Needle breakage during local anesthesia in the oral cavity—a retrospective of the last 50 years with guidelines for treatment and prevention. *Clin Oral Investig*, 15:3-8, 2011.
2. Khalil H : A basic review on the inferior alveolar nerve block techniques. *Anesth Essays Res*, 8:3-8, 2014.
3. Ethunandan M, Tran AL, Brennan PA. *et al.* : Needle breakage following inferior alveolar nerve block: implications and management. *Br Dent J*, 202:395-397, 2007.
4. Holmes PJ, Miller JR, Gutta R, Louis PJ : Intraoperative imaging techniques : a guide to retrieval of foreign bodies. *Oral Surg Oral Med Oral Pathol Oral Radiol Endod*, 100:614-618, 2005.
5. Thompson M, Wright S, Cheng LH, Starr D : Locating broken dental needles. *Int J Oral Maxillofac Surg*, 32:642-644, 2003.
6. Kronman JH, el-Bermani AW, Wongwatana S, Kumar A : Preferred needle lengths for inferior alveolar anesthesia. *Gen Dent*, 42:74-76, 1994.
7. Korean academy of Pediatric Dentistry : Textbook of Pediatric Dentistry. 5th ed. Yenang INC, 326-328, 2014.
8. Malamed SF : Handbook of Local Anesthesia. 5th ed. Mosby, 275-277, 2004.
9. Pogrel MA : Broken local anesthetic needles: a case series of 16 patients, with recommendations. *J Am Dent Assoc*, 140:1517-1522, 2009.
10. BR Chrcanovic, DC Menezes Jr, AL Custodio : Complication of local dental anesthesia - a broken needle in the pterygomandibular space. *Braz J Oral Sci*, 8:159-162, 2009.
11. Ram D, Peretz B : Administering local anaesthesia to paediatric dental patients — current status and prospects for the future. *Int J Paediatr Dent*, 12:80-89, 2002.
12. Zeltser R, Cohen C, Casap N : The implications of a broken needle in the the bandit needle prior to injection should be avoided. pterygomandibular space: clinical guidelines for prevention and retrieval. *Pediatr Dent*, 24:153-156, 2002.
13. Shah A, Mehta N, Von Arx DP : Fracture of a dental needle during administration of an inferior alveolar nerve block. *Dent Update*, 36:20-22, 25, 2009.
14. Rao LP, Peter S : Modification of the dingman mouth gag for better visibility and access in the management of cleft palate. *Cleft Palate Craniofac J*, 52:250-253, 2015.

국문초록

어린 아동의 하치조신경 전달마취 시 발생한 주사바늘 파절 : 증례보고

이한별<sup>1</sup> · 김민근<sup>2</sup> · 박호원<sup>1</sup> · 서현우<sup>1</sup> · 이주현<sup>1</sup>

<sup>1</sup>강릉원주대학교 치과대학 소아치과학교실 및 구강과학연구소

<sup>2</sup>강릉원주대학교 치과대학 구강악안면외과학교실 및 구강과학연구소

국소마취 중 갑작스러운 움직임은 주사바늘 파절을 야기할 수 있으며, 특히 예기치 못한 움직임을 보이기 쉬운 아동에게서는 더욱 신중한 접근이 필요하다.

주사바늘 파절이 발생한 경우 합병증을 최소화 하기 위하여 의료진의 신속한 대처가 중요하며, 환자 및 보호자에게 충분한 상황 설명과 진심 어린 유감표명을 하는 등의 의사소통을 위한 노력이 필요하다. 하지만 무엇보다 중요한 것은 이러한 사고가 일어나지 않도록 하는 것이며, 이를 위하여 의료진은 사고 예방에 필요한 주의사항을 충분히 인지하고 있어야 한다.

본 증례는 의식하 진정하에 하치조신경 전달마취 시 갑작스러운 움직임으로 인해 주사바늘이 파절된 어린 아동에 대한 내용이다. 구강 내 존재하는 주사바늘 파절편의 위치를 방사선 사진을 통하여 확인하였고, 전신마취 하에 파절편을 성공적으로 제거하였기에 이를 보고하며, 주사바늘 파절 원인에 대한 고찰과 이를 예방하기 위한 방법을 논의하여 주사바늘 파절 예방에 대한 관심을 증대시키고자 한다.

**주요어:** 국소마취용 주사 바늘 파절, 하치조신경 전달 마취, 어린이, Dingman mouth gag

www.kci.go.kr