

# Association between Ectopic Eruption of the Maxillary First Permanent Molar and Skeletal Malocclusion

Yujin Rah, Jewoo Lee, Jiyoung Ra

*Department of Pediatric Dentistry, College of Dentistry, Wonkwang University*

## Abstract

This study assessed the association between ectopic eruption of the maxillary first permanent molar and skeletal malocclusion in 5- to 10-year-old children.

As subjects, 786 children who attended the Wonkwang University Dental Hospital for orthodontic diagnosis were included. Children with unerupted first permanent molars or fully erupted second permanent molars were excluded. The study group demonstrated ectopic eruption of the maxillary first permanent molar, while the control group did not. Cephalometric radiographs taken between January 2003 and August 2015 were analyzed.

Skeletal class III malocclusion was detected in 57.0% of the study group, which differed significantly from that in the control group ( $p < 0.05$ ). The SNA, ANB angles, and A to N-perpendicular distance were significantly smaller, whereas the A-B plane angle and APDI were significantly greater in the study group than in the control group ( $p < 0.05$ ). The SNB and mandibular plane angles were not significantly different between the groups.

Thus, maxillary undergrowth is a risk factor for ectopic eruption of the maxillary first permanent molar.

**Key words :** Ectopic eruption, Maxillary first permanent molar, Skeletal malocclusion

## I. Introduction

Ectopic eruption of the maxillary first permanent molar is a local disturbance in which the tooth erupts mesially to its normal path. The molar then causes an abnormal resorption of the distal root of the maxillary second primary molar[1]. Young[2] classified ectopic eruption into the jump type and the hold type. The jump type of ectopic eruption is a reversible eruption of the maxillary first permanent molar, and is characterized by a spontaneous self-correction, after which the tooth erupts in its normal position within the arch. The hold

type of ectopic eruption is an irreversible eruption in which the maxillary first permanent molar is locked under the distal surface of the maxillary second primary molar in the cervical area.

Ectopic eruption of the maxillary first permanent molar is diagnosed on routine radiographic examination performed between the ages of 5 - 7 years. This condition is diagnosed when the radiograph reveals an impacted maxillary first permanent molar overlapping the distobuccal root of the proximal maxillary second primary molar[3] or shows pathological root resorption[4]. The diagnosis can also be made clinically. The

Corresponding author : Jiyoung Ra

Department of Pediatric Dentistry, College of Dentistry, Wonkwang University, 895 Muwang-ro, Iksan, Jeollabuk-do, 54538, Korea

Tel: +82-63-850-6633 / Fax: +82-63-851-5324 / E-mail: pedojy@wku.ac.kr

Received June 27, 2016 / Revised August 31, 2016 / Accepted August 17, 2016

※This research was supported by Wonkwang University, in 2017.

distal cusp of the maxillary first permanent molar can erupt before the mesial cusp[5], or the eruption can be delayed unilaterally or bilaterally[2].

Bjerklin and Kuroi[1] demonstrated that the maxilla tends to be shorter in children with an irreversible ectopic eruption of the maxillary first permanent molar than in children with a normal eruption of this tooth. Pulver *et al.*[6] suggested that ectopic eruption can be caused by a combination of factors, such as an abnormally short maxillary length and a posterior maxillary position in relation to the cranial base. Canut and Raga[7] suggested that a short and posteriorly positioned maxilla may affect the ectopic eruption of the maxillary first permanent molar.

The cause of ectopic eruption of the maxillary first permanent molar is considered to have a multifactorial etiology, and is not well known[1,6,7]. However, only a few studies have surveyed the association between a skeletal imbalance of the jaw and ectopic eruption of the maxillary first permanent molar based on cephalometric analysis. There have been even fewer such studies in Korean populations. Therefore, the present study investigated the types of skeletal malocclusion associated with ectopic eruption of the maxillary first permanent molar, in a Korean population, and assessed the presence of ectopic eruption on panoramic radiographs.

## II. Materials and Methods

### 1. Subjects

The subjects included 5- to 10-year-old children who visited the Wonkwang University Dental Hospital from January 2003 to August 2015 for orthodontic diagnosis. Children whose first permanent molar had not erupted or whose second permanent molar had completely erupted were excluded from the study. The study group included 93 patients whose panoramic radiographs indicated ectopic eruption of the maxillary first permanent molar. The control group included 693 patients without such ectopic eruption.

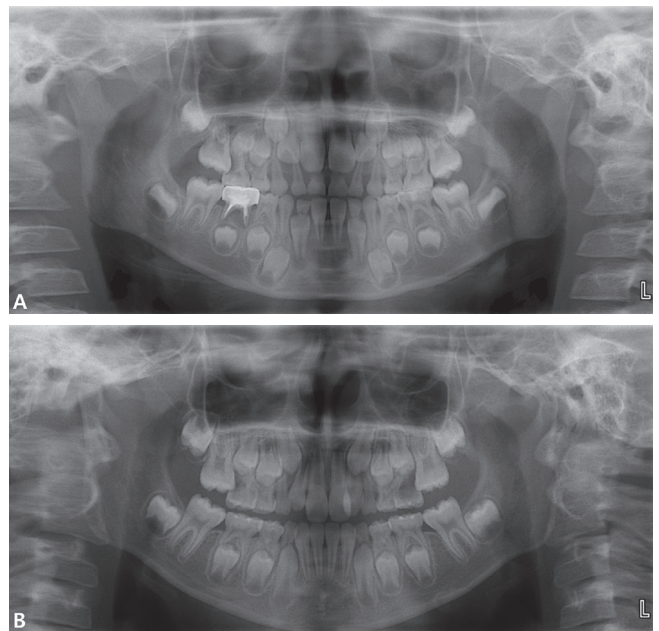
### 2. Evaluation of ectopic eruption of the maxillary first permanent molar

Bjerklin and Kuroi[1] noted that the ectopically erupted molar makes contact with the second primary molar apically to the prominence of its distal surface and causes abnormal root

resorption. Harrison and Michal[3] stated that it is possible to diagnose an ectopic eruption of the maxillary first permanent molar on a routine radiographic examination. Hence, this study included patients whose panoramic radiographs revealed that the proximal maxillary second primary molar hampered the complete eruption of the ipsilateral maxillary first permanent molar, or showed pathologic resorption of the distal root of the maxillary second primary molar (Fig. 1).

### 3. Cephalometric analysis

To assess skeletal malocclusion, we determined the following cephalometric measurements: the SNA, SNB, ANB, A-B plane angles, mandibular plane angle, the A to N-perpendicular distance, and the APDI. Cephalometric analyses were conducted using Vceph™ 6.0 (OSSTEM IMPLANT, Korea). The classification of malocclusion in this study was based on the outcome of the cephalometric analysis of Lee[8], Yang and Kim[9], and Suh *et al.*[10] in children with normal occlusion (Table 1). The subjects were classified as having skeletal malocclusion when three of four cephalometric measurements met these diagnostic criteria (Table 2).



**Fig. 1.** Ectopic eruption of the maxillary first permanent molar. (A) Unilateral, (B) Bilateral.

**Table 1.** The mean and standard deviation of cephalometric measurements

	Boys (degree, mean ± SD)	Girls (degree, mean ± SD)
ANB	3.06 ± 1.22	4.08 ± 1.57
A-B plane angle	-5.7 ± 2.9	-5.5 ± 1.5
Mandibular plane angle	30.3 ± 3.8	30.2 ± 4.3
APDI	77.2 ± 4.8	78.2 ± 2.5

SD = standard deviation

**Table 3.** Distribution of ectopic eruption according to gender

	Patients	Ectopic eruption		<i>p</i> -value
	N	N	%	
Boys	381	52	13.6	.126
Girls	405	41	10.1	
Total	786	93	11.8	

*p* values from the Pearson chi-square test

**Table 2.** Diagnostic criteria for skeletal malocclusion

	Boys (degree)		Girls (degree)	
	Skeletal Class II	Skeletal Class III	Skeletal Class II	Skeletal Class III
ANB	> 4.3	< 1.8	> 5.7	< 2.5
A-B plane angle	< - 8.6	> - 2.8	< - 7	> - 4
Mandibular plane angle	< 26.5	> 34.1	< 25.9	> 34.5
APDI	< 72.4	> 82	< 75.7	> 80.7

#### 4. Statistical analysis

One investigator assessed the panoramic radiographs and performed cephalometric analyses; this investigator also performed two additional analyses at 1-week intervals in 50 randomly selected subjects to assess intra-examiner reliability, which was excellent (intra-class correlation coefficient value = 0.971).

Statistical analyses were conducted using Windows SPSS 18 (IBM, USA) with a significance level set at 5%. The chi-squared test was used to evaluate the distribution of skeletal malocclusion, based on the presence of ectopic eruption. The independent samples t-test was performed to compare the means of cephalometric measurements between groups with and without ectopic eruption of the first permanent molar.

#### 5. Approval of Institutional Review Board

This study was approved by the Institutional Review Board of Wonkwang University Dental Hospital (WKDIRB201510-01).

### III. Results

#### 1. Prevalence of ectopic eruption of the maxillary first permanent molar

Ectopic eruption of the maxillary first permanent molar was observed in 93 of 786 children (11.8%). The study group included 52 boys and 41 girls, and the control group included 329 boys and 364 girls. Ectopic eruption of the maxillary first permanent molar was more prevalent among boys than among girls, but this difference was not statistically significant (Table 3).

#### 2. Distribution of skeletal malocclusion according to ectopic eruption of the maxillary first permanent molar

Of 93 children with ectopic eruption of the maxillary first permanent molar, 34 children had a skeletal class I malocclusion, 6 children had a class II malocclusion, and 53 children had a class III malocclusion. In the control group (comprising

693 children), 342 children had a skeletal class I malocclusion, 159 children had a class II malocclusion, and 192 children had a class III malocclusion. In the study group, most children had a skeletal class III malocclusion, while only few had a skeletal class II malocclusion. In the control group, there were more children with a skeletal class I malocclusion than with either of the other two types of malocclusion. The difference in the classification of skeletal malocclusion between the groups with and without ectopic eruption was significant (Table 4).

3. Cephalometric measurements according to ectopic eruption of the maxillary first permanent molar

Cephalometric analysis indicated that the SNA and ANB angles, and A to N-perpendicular distance were greater in the control group, and the A-B plane angle and APDI were greater in the study group. The intergroup differences in the SNA, ANB, and A-B plane angles and APDI were statistically significant, whereas the intergroup differences in the SNB and mandibular plane angles were not (Table 5).

**Table 4.** Classification of skeletal malocclusion in the study group and the control group

	Study group (N = 93)		Control group (N = 693)		p-value
	N	%	N	%	
Class I	34	36.6	342	49.4	.000
Class II	6	6.5	159	22.9	
Class III	53	57.0	192	27.7	

p values from the Pearson chi-square test

**Table 5.** Lateral cephalometric measurements in the study group and the control group

	Study group (N = 93)	Control group (N = 693)	p-value
SNA (degree)	79.02	80.07	.005
SNB (degree)	77.29	76.91	.272
ANB (degree)	1.72	3.16	.000
A-B plane angle (degree)	-2.71	-5.41	.000
Mandibular plane angle (degree)	30.11	30.06	.923
APDI (degree)	87.41	81.40	.000
A to N perpendicular (mm)	-1.24	-0.07	.000

p values from the independent samples t-test

IV. Discussion

Previous studies have reported that the prevalence of ectopic eruption of the maxillary first permanent molar varies between 0.75% and 6%[11-13]; the large variation in the prevalence is affected by the sample sizes[14]. In addition, Carr and Mink[15] and Bjerkin *et al.*[16] showed that ectopic eruption of the maxillary first permanent molar in cleft children occurs more frequently when compared with non-cleft children. This study found that the prevalence of ectopic eruption of the maxillary first permanent molar was 11.8%, which was higher than that reported in previous studies.

This study investigated the association between the presence of ectopic eruption of the maxillary first permanent molar and skeletal malocclusion in children with mixed dentition. The SNA, SNB, and ANB angles are the most commonly used measurements for assessing the anteroposterior relationships of the jaw and to assess skeletal malocclusion[17,18]. However, Freeman[19] asserted that the sizes of the SNA, SNB, and ANB angles were variable, depending on the position of the nasion, even in the absence of changes in the jaw relationships. The present study additionally used the the A-B plane angle, the mandibular plane angle and the APDI for skeletal assessment, and the A to N-perpendicular distance was selected to analyze maxillary undergrowth.

Studies that have incorporated cephalometric analyses have demonstrated that ethnicity, sex, and region affected these measurements. Therefore, various analytical methods have been used in such studies in Korea to identify reference values for these measurements in Koreans. Park[20] studied the changes in the maxillofacial development of Korean children

aged 6 - 9 years, using Ricketts analysis. Yang and Kim[9] performed Ricketts analysis on 9-year-old children. Suh *et al.*[10] performed cephalometric analyses on children with normal occlusion of primary dentition, and Kim *et al.*[21] reported normal cephalometric values for children with mixed dentition. In the present study, we classified skeletal malocclusion based on the cephalometric studies of Lee[8], Yang and Kim[9], and Suh *et al.*[10] in children with normal occlusion; however, this study is limited in that the average age of the children studied is differed from the average age of the children included in the present study.

Pulver[6] have reported that patients with ectopic eruption of the maxillary first permanent molar have short arches and small maxilla and that the maxilla is posteriorly positioned relative to the cranial base. Canut and Raga[7] have assessed this in Europeans, and their results supported the findings of Pulver[6]. Chintakanon and Boonpinon[13] measured the SNA, SNB, and ANB angles, soft tissue facial convexity, maxillary length (ANS-PNS), and mandibular length (Co-Pg), and found no significant differences in these measurements between the ectopic eruption group and the normal eruption group. Mucedero *et al.*[22] measured the maxillary arch lengths, the intercanine widths, and the intermolar widths, to assess the skeletal features of the maxillary arches of patients with ectopic eruption of the maxillary first permanent molar. Their findings indicated that the maxillary arches were shorter and narrower in the ectopic eruption group than those of the normal eruption group. These studies analyzed maxillary structures using different measurements than those used in the present study. However, they found that maxillary undergrowth can affect ectopic eruption of the maxillary first permanent molar, which is consistent with the findings of the present study.

This study has several limitations. This study was a cross-sectional study, and it is limited in that we did not distinguish between the cases with hold and jump types ectopic eruption of the maxillary first permanent molar in the study group. Furthermore, this study only examined children who visited the hospital for orthodontic diagnoses, which does not reflect the prevalence as a whole. Patients were classified based on only panoramic radiographs, without considering clinical test results. Furthermore, the measurements used in this study as a reference for classifying skeletal malocclusion were not an absolute representation of maxillary development. Thus, future studies should use other measurements to analyze the association between skeletal malocclusion caused by maxillary

undergrowth and the eruption pattern of the maxillary first permanent molar.

## V. Conclusion

In this study, the association between ectopic eruption of the maxillary first permanent molar and skeletal malocclusion was investigated. Based on our findings, we were able to determine that maxillary undergrowth has an impact on the ectopic eruption of the maxillary first permanent molar.

## References

1. Bjerklin K, Kuro J : Ectopic eruption of the maxillary first permanent molar: etiologic factors. *Am J Orthod*, 84:147-155, 1983.
2. Young DH : Ectopic eruption of the first permanent molar. *J Dent Child*, 24:153-162, 1957.
3. Harrison LM, Michal BC : Treatment of ectopically erupting permanent molars. *Dent Clin North Am*, 28:57-67, 1984.
4. O'Meara WF : Ectopic eruption pattern in selected permanent teeth. *J Dent Res* 41:607-616, 1962.
5. Campbell OA : Ectopic eruption of the first permanent molar. *J N J Dent Assoc*, 62:62-65, 1991.
6. Pulver F : The etiology and prevalence of ectopic of the maxillary first permanent molar. *ASDC J Dent Child*, 35:138-146, 1968.
7. Canut JA, Raga C : Morphological analysis of cases with ectopic eruption of the maxillary first permanent molar. *Eur J Orthod*, 5:249-253, 1983.
8. Lee HJ : A roentgenocephalometric study on the children of normal occlusion in the mixed dentition. *Korean J Orthod*, 5:11-19, 1975.
9. Yang KH, Kim SM : A cephalometric study of Korean children by Ricketts' analysis. *J Korean Acad Pediatr Dent*, 25:430-440, 1998.
10. Suh MS, Son HK, Baik HS, Choi HJ : Cephalometric analysis for children with normal occlusion in the primary dentition. *J Korean Acad Pediatr Dent*, 32:109-118, 2005.
11. Barberia-Leache E, Soares-Clúa MC, Saavedra-Ontiveros D : Ectopic eruption of the maxillary first permanent molar: characteristics and occurrence in growing children. *Angle Orthod*, 75:610-615, 2005.
12. Salbach A, Schremmer B, Grabowski R, Stahl de Castrillon F : Correlation between the frequency of eruption disorders

- for first permanent molars and the occurrence of malocclusions in early mixed dentition. *J Orofac Orthop*, 73:298-306, 2012.
13. Chintakanon K, Boonpinon P : Ectopic eruption of the first permanent molars: prevalence and etiologic factors. *Angle Orthod*, 68:153-160, 1990.
  14. Kuroi J, Bjerklind K : Ectopic eruption of maxillary first permanent molar: a review. *ASDC J Dent Child*, 53:209-214, 1986.
  15. Carr GE, Mink JR : Ectopic eruption of maxillary first permanent molar in cleft palate children. *J Dent Child*, 32:179-188, 1965.
  16. Bjerklind K, Kuroi J, Paulin G : Ectopic eruption of the maxillary first permanent molars in children with cleft lip and/or palate. *Eur J Orthod*, 15:535-540, 1993.
  17. Jacobson A, Evans WG, Preston CB, Sadowsky PL : Mandibular prognathism. *Am J Orthod*, 66:140-171, 1974.
  18. Ryu HJ, Lee CH, Jeong TS, Kim S : A study on the maturation in children with class III skeletal malocclusion of mandibular overgrowth type. *J Korean Acad Pediatr Dent*, 40:21-27, 2013.
  19. Freeman RS : Adjusting A-N-B angle to reflect the effect of maxillary position. *Angle Orthod*, 51:162-171, 1981.
  20. Park TS : A longitudinal cephalometric study of craniofacial growth of Korean children. *Korean J Orthod*, 14:217-231, 1984.
  21. Kim CC, Shun YK, Shon DS, *et al.* : Cephalometric analysis of Korean children of mixed dentition. *J Korean Acad Pediatr Dent*, 20:601-614, 1993.
  22. Mucedero M, Rozzi M, Cozza P, *et al.* : Dentoskeletal features in individuals with ectopic eruption of the permanent maxillary first molar. *Korean J Orthod*, 45:190-197, 2015.

국문초록

## 상악 제1대구치의 이소맹출과 골격성 부정교합의 연관성

나유진 · 이제우 · 라지영

*원광대학교 치과대학 소아치과학교실*

본 연구는 5 - 10세 아동에서 상악 제1대구치의 이소맹출과 골격적 부정교합 유형 사이의 연관성을 평가하고자 하였다.

상악 제1대구치의 이소맹출이 있는 93명의 아동을 실험군으로, 이소맹출이 없는 693명의 아동을 대조군으로 분류하였다. 제1대구치가 맹출 전이거나 제2대구치가 맹출을 완료한 경우는 연구대상에서 제외하였다. 측모 두부 방사선 사진 계측을 통해 골격적 부정교합의 유형을 조사, 분석하였다.

실험군의 경우, 골격성 3급 부정교합이 57.0% 이었고, 대조군에 비해 골격성 3급 부정교합의 비율이 유의하게 높았다. SNA, ANB, A to N-perpendicular는 실험군에서 작은 경향을 보였고, A-B plane angle과 APDI는 더 크게 나타났다. 반면, SNB와 mandibular plane angle은 두 군 사이에서 유의한 차이가 없었다.

본 연구를 통해 상악의 열성장이 상악 제1대구치의 이소맹출에 영향을 미칠 수 있음을 확인하였다.

**주요어:** 이소맹출, 상악 제1대구치, 골격성 부정교합