

Prevalence and Clinical Features of Molar-Incisor Hypomineralization in Adolescents in Yangsan

Jonghyun Shin, Geumlang Lee, Jongsoo Kim, Jiyeon Kim, Shin Kim

Department of Pediatric Dentistry, School of Dentistry, Pusan National University

Abstract

This study aimed to investigate the prevalence and distribution of enamel hypomineralization, including molar-incisor hypomineralization (MIH), among adolescents and assess their correlation with esthetic satisfaction.

A total of 1371 adolescents between the ages of 14 and 16 years in Yangsan city were evaluated for enamel hypomineralization, including MIH, according to the European Academy of Paediatric Dentistry (EAPD) criteria. In a parallel survey, esthetic satisfaction about anterior teeth and its correlation with incisor enamel hypomineralization were analyzed.

The prevalence of MIH was 13.8% (n = 189), while that of hypomineralization in any permanent tooth was 23.2% (n = 318), which was substantially greater compared to the national prevalence of MIH. Mandibular first molars exhibited the highest prevalence of hypomineralization, followed by maxillary central incisors and mandibular second molars. Among anterior teeth, the most frequently affected site was the incisal edge of maxillary central incisors. A high degree of hypomineralization in anterior teeth was associated with a high demand for esthetic treatment.

Key words : Molar incisor hypomineralization, Adolescents, Prevalence, Esthetics, Anterior tooth

I. Introduction

With recent improvements in the level of oral care, the prevalence of dental caries, a prominent oral disease, has been decreasing[1,2]. In contrast, the prevalence of enamel hypomineralization due to systemic factors has increased, which has heightened interest regarding this condition[3,4].

Crown formation in first permanent molars and incisors occurs at approximately the same time[5], during which enamel hypomineralization is frequently observed. Enamel hypomineralization in first permanent molars and anterior teeth was

first reported in 1970 in Sweden[6]. In 2001, Weekheim *et al.*[7] defined MIH as demarcated, qualitative enamel defects of systemic origin, affecting one or more permanent molars with or without involvement of incisor teeth. Since then, several studies worldwide have actively investigated the etiology, conditions, and prevalence of MIH, with most focusing on first permanent molars and incisors.

However, the clinical categorization of hypomineralization is broad, and clinically, all primary teeth, permanent canines, premolars, and second permanent molars can be affected by enamel hypomineralization[8-10]. Therefore, in a recent policy,

Corresponding author : Shin Kim

Department of Pediatric Dentistry, School of Dentistry, Pusan National University, 20, Geumo-ro, Mulgeum-eup, Yangsan, 50612, Korea

Tel: +82-55-360-5180 / Fax: +82-55-360-5174 / E-mail: shinkim@pusan.ac.kr

Received December 1, 2016 / Revised February 10, 2017 / Accepted January 25, 2017

✽This study was supported by 2015 Clinical Research Grant, Pusan National University Dental Hospital.

the European Academy of Paediatric Dentistry (EAPD) recommended that whole dentition be included in future studies on enamel hypomineralization[11].

Several studies have investigated the causes of MIH[12]. A recent study reported that, while a significant correlation existed between MIH and polyvinyl chloride/dioxin discharge, MIH was only weakly correlated with nutritional status, birth conditions, childhood diseases, and fluoride intake[13]. In another study, water fluoridation and pregnancy at an older age were identified as risk factors for MIH[14,15]. High vitamin D concentration in blood has also been reported to be negatively correlated with MIH. While it appears that MIH is caused by various risk factors, no definite risk factors have been identified yet[16].

Teeth affected by MIH exhibit enamel defects and rapid progression of caries; therefore, in many cases, affected teeth require restorative treatment right after eruption. However, owing to the high organic content of enamel, the success rate of adhesion of restorations is low[17,18]. If the defect is deep and widespread, it can lead to severe loss of tooth material and early loss of permanent teeth because of caries progression. In addition, in adolescents with active social lives and a developing interest in appearance[19], slight defects can have a serious impact on self-esteem, depending on the location of the defect.

Despite the significant impact of MIH on adolescents, previous studies have only investigated MIH among elementary school students[20], and no study till date has evaluated MIH among a teenage population. The subjects of the present study were middle-school students with complete eruption of permanent dentition. The prevalence, defect patterns, and distribution of permanent tooth enamel hypomineralization, including MIH, and their effects on tooth condition and esthetic satisfaction were evaluated.

II. Materials and Methods

1. Subjects

An inspector performed oral examination of 1371 adolescent students between the ages of 14 and 16 years at a middle school in Yangsan province, South Korea, between May and August 2013. Water fluoridation had not been enforced in this area, and the fluoride concentration in water was lower than the detection limit of 0.15 ppm. To eliminate potential

Table 1. Distribution of sex and age of the subjects

	Total (%)	Boys (%)	Girls (%)
Total	1,371 (100.0)	765 (55.8)	606 (44.2)
Age (years)			
14	316 (23.0)	175 (22.9)	141 (23.3)
15	498 (36.3)	275 (35.9)	223 (36.8)
16	557 (40.6)	315 (41.2)	242 (39.9)

confounders, subjects with primary teeth remaining or pre-emergent second permanent molars were excluded from the study. Subject age and sex distribution are presented in Table 1.

2. Research Methods

1) Preliminary investigation and ethical considerations

Prior to the survey, the inspector underwent training with clinical images and patients who visited the Pediatric Dentistry department at Pusan Dental Hospital, in order to establish consistency in diagnosis. With the help of an expert, the inspector was administered a blind test using 50 images of teeth with MIH, enamel hypoplasia, or fluorosis, with the accuracy set initially at 96.0%. The same images were retested a month later, and the findings of the first and second tests exhibited a very good agreement, with a Kappa value of 0.87.

This study was approved through review by the Bioethics Committee of Pusan University Dental Hospital (PNUDH-2013-017).

2) Oral examination

Oral examination was performed using a head light, dental mirror, and community periodontal index probe, with the examinee seated in a chair in the health service room of the school. Subjects were instructed to brush their teeth prior to examination, and, when necessary, a gauze was used to remove food debris and dental plaques.

(1) Enamel hypomineralization

Hypomineralization in the dentition-from the central incisor to the second permanent molar-was evaluated. Enamel hypomineralization was considered present when an impervious enamel defect with a clearly visible white or brown-colored boundary was observed while the tooth was wet. However, cases in which the lesion was less than 1 mm diameter, cases

Table 2. EAPD criteria for molar incisor hypomineralization

Code	Definition	Description
O	Demarcated opacity	The affected teeth show clearly demarcated opacities at the occlusal and buccal part of the crown
P	Enamel disintegration	Severely affected enamel which breaks down soon after being subjected to masticatory forces, leading to unprotected dentin and rapid caries development
R	Atypical restoration	First permanent molars and incisors with restorations revealing similar extensions as MIH are recommended to be judged as affected
E	Extracted teeth	Extracted teeth can be defined as having MIH only in cases in which there are notes in the records or demarcated opacities on the other permanent first molar

of trauma and cases of periapical inflammation in primary teeth were excluded[21]. Teeth diagnosed with enamel hypomineralization were classified according to the criteria proposed by the EAPD in 2003 (Table 2)[22]. Further, the labial surfaces of incisors, lateral incisors, and canines were divided into nine compartments, and the presence and distribution of enamel defects in each compartment were also recorded for evaluation of esthetics. Subjects were assigned to one of three groups: the normal (no defects), EH (permanent dentition with defects in at least one tooth), or MIH (defects in first permanent molars) groups.

3) Questionnaire survey

A questionnaire survey was conducted to determine the correlation between state of enamel hypomineralization and esthetic satisfaction about anterior teeth. The questionnaires were distributed at the examination site, and subjects completed them under the guidance of teachers.

4) Data analysis

The collected data were analyzed using SPSS 13.0 (SPSS Inc.,

USA) for Windows. The level of significance was set at 0.05 for all statistical data. The significance of sex and age with regard to prevalence was verified by the chi-square test. Incidence of tooth-specific defects was determined by frequency analysis. The correlation between first permanent molars and the rest of the permanent teeth in affected individuals was determined by correlation analysis.

III. Results

1. Prevalence of enamel hypomineralization

The distribution of prevalence of enamel hypomineralization among the subject pool is presented in Table 3. Of the total 1371 subjects, 318 (23.2%) were assigned to the EH group and 189 (13.8%) to the MIH group. In both groups, the prevalence of enamel hypomineralization among female subjects was greater compared to that among men, although the difference was insignificant ($p > 0.05$); however, there were significant differences in prevalence of enamel hypomineralization according to age ($p < 0.05$).

Table 3. Prevalence of enamel hypomineralization

		Normal		EH		MIH		<i>p</i> -value
		N	%	N	%	N	%	
Sex	Male	602	78.7	163	21.3	98	12.8	0.06
	Female	451	74.4	155	25.6	91	15.0	
Age	14	238	75.3	78	24.7	50	15.8	< 0.05
	15	359	72.1	139	27.9	81	16.3	
	16	456	81.9	101	18.1	58	10.4	
Total		1053	76.8	318	23.2	189	13.8	

Chi-square test

The average numbers of affected teeth in the EH and MIH groups were 3.82 (boys, 3.88; girls, 3.76) and 5.18 (boys, 5.22; girls, 5.13), respectively, with no significant differences according to sex ($p > 0.05$; Table 4).

Table 4. Number of teeth affected by enamel hypomineralization and molar incisor hypomineralization

		Male	Female	Total
EH	Affected teeth	634	583	1,217
	Affected children	163	155	318
	Mean(teeth)	3.88	3.76	3.82
	SD	3.76	3.04	3.42
	p -value	0.75		
MIH	Affected teeth	512	467	979
	Affected children	98	91	189
	Mean(teeth)	5.22	5.13	5.18
	SD	4.26	3.23	3.79
	p -value	0.87		

Frequency analysis

2. Distribution of defects according to tooth type

Among all teeth that exhibited enamel hypomineralization, mandibular first permanent molars were the most commonly affected, followed by maxillary central incisors, maxillary first permanent molars, and mandibular second permanent molars, in that order (Table 5).

Analysis of correlation between first permanent molars and the rest of the permanent teeth with regard to enamel hypomineralization defects revealed that presence of defects in first permanent molars indicated the possibility of defects in the rest of the permanent teeth. This correlation was the highest among central incisors, followed by second permanent molars ($p < 0.05$; Table 6).

3. Condition of affected teeth

Incisors and first and second permanent molars exhibited high morbidity rates; Table 7 presents the results of analysis of lesion patterns in these teeth according to the EAPD criteria. In incisors, demarcated opacity was the most prevalent type of defect at 99.7%, while the prevalence of enamel breakdown

Table 5. Distribution of affected teeth by tooth type

	Right (%)							Left (%)						
	M2	M1	P2	P1	C	LI	CI	CI	LI	C	P1	P2	M1	M2
Upper	2.2	7.4	1.3	1.6	1.8	3.8	9.3	9.0	3.0	2.6	1.6	1.7	6.3	1.4
Lower	4.6	9.3	1.6	1.7	1.0	1.6	2.9	3.2	1.7	0.7	1.6	1.5	10.3	5.0

CI: central incisor, LI: lateral incisor, C: canine, P1: first premolar, P2: second premolar, M1: first molar, M2: second molar

Table 6. The correlation between first permanent molars and the rest of permanent teeth in regards to enamel hypomineralization defects

		CI	LI	C	P1	P2	M2
M1	Correlation coefficient	0.50	0.33	0.25	0.35	0.37	0.44
	p -value	<0.05	<0.05	<0.05	<0.05	<0.05	<0.05

Correlation analysis

CI: central incisor, LI: lateral incisor, C: canine, P1: first premolar, P2: second premolar, M1: first molar, M2: second molar

Table 7. Status of affected incisors and molars

	Incisor		First molar		Second molar		p -value
	N	%	N	%	N	%	
O	289	99.7	197	49.6	145	85.8	$p < 0.05$
P	1	0.3	10	2.5	2	1.2	
R	0	0.0	183	46.1	22	13.0	
E	0	0.0	7	1.8	0	0.0	

Chi-square test

O: demarcated opacity, P: enamel disintegration, R: atypical restoration, E: extracted teeth

was only 0.3%. In first permanent molars, demarcated opacity was the most prevalent defect pattern at 49.6%, followed by atypical restoration at 46.1%, and even extraction at 1.8%. Similarly, in second permanent molars, demarcated opacity was the most prevalent defect pattern at 85.8%, followed by atypical restoration at 13.0%. The differences in defect patterns according to tooth type were significant ($p < 0.05$).

4. Range of defects and need for treatment of labial surfaces of incisors and canines

Fig. 1 presents the range and distribution of defects among the nine compartments on the labial surfaces of central and lateral incisors and canines. Defects were deemed present when they met at least one of the four criteria shown in Table 2. Based on the number of teeth with lesions in each compartment, six grades of defects were defined, ranging from < 10 to > 50 , represented by a change in color. When teeth were divided into three equal parts from top to bottom, the most frequently affected regions were the edge and middle portion of maxillary central incisors, in that order.

Subsequently, depending on the number of affected teeth, a total of 12 teeth and 108 blocks were classified into 6 subject groups for evaluation of esthetic satisfaction and need for treatment, as indicated by subject response to the questionnaire survey. Subjective esthetic satisfaction was evaluated on a scale of 1 to 5. Esthetic satisfaction scores for presence of enamel hypomineralization in incisors or canines were lower ($p < 0.05$; Table 8). The need for esthetic treatment, although not

in proportion with the increase in number of affected blocks, varied significantly depending on the presence or absence of defects ($p < 0.05$; Table 9).

IV. Discussion

Enamel breakdown can occur on occlusal force impact, and enamel hypomineralization appears in a variety of colors, including yellow, tan, brown, and milky white[23]. The aprismatic enamel layer, thick prism sheath, and coarse crystals observed in hypomineralized enamel are responsible for the decreased hardness of hypomineralized teeth[24]. In particular, when bacteria penetrate porous enamel, the pulp enters into a state of

Table 8. The correlation between range of defects and esthetic satisfaction

No. of affected sections	No. of persons	Satisfaction Mean (SD)	p -value
0	1,123	2.91 (0.99)	
1 - 10	222	2.76 (1.02)	
11 - 20	16	2.63 (1.31)	< 0.05
21 - 30	6	2.33 (1.21)	
31 - 40	2	1.00 (0.00)	
41 <	2	3.00 (0.00)	

Chi-square test

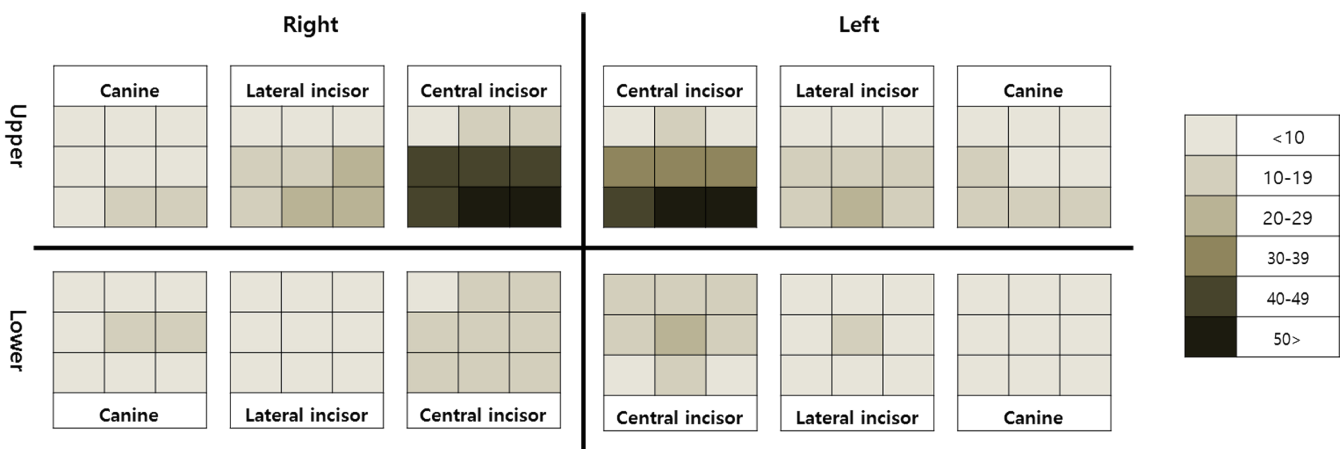


Fig. 1. Surface-related distribution in anterior teeth.

Table 9. The correlation between range of defect and need for treatment

No. of affected sections	Esthetic treatment need				Total	<i>p</i> -value
	Yes		No			
	No. of persons	%	No. of persons	%		
0	336	29.9	787	70.1	1,123	
1 - 10	96	43.2	126	56.8	222	
11 - 20	7	43.8	9	56.3	16	
21 - 30	3	50.0	3	50.0	6	<0.05
31 - 40	2	100.0	0	0.0	2	
41 <	0	0.0	2	100.0	2	
Total	444	32.4	927	67.6	1,371	

Chi-square test

chronic inflammation, which causes hypersensitivity and failure of local anesthesia[24,25]. Because of the resultant constant pain, young and adolescent patients affected by MIH often exhibit behavior management issues during dental treatment.

In addition, enamel hypomineralization typically occurs at locations other than those of dental caries, and when lesions affect the cusp, appropriate restoration becomes very difficult[26]. Consequently, maintaining restorations is challenging, and several claims are being raised that it is best to extract teeth with poor prognosis in a timely manner[27]. Traditionally, the ideal age for extraction of first permanent molars is 9 - 11 years[28]. However, recent studies are conflicted over the appropriate age for extraction; some studies have proposed that extraction should be performed at a younger age, whereas others have stated that early extraction could increase the risk of hypomineralization in second permanent molars[29].

Anterior teeth defects are treated with emphasis on esthetic improvement. However, because microabrasion, resin restoration, and whitening agents such as hydrogen peroxide usually cause mineral loss[30], casein phosphopeptide-amorphous calcium phosphate is now being used for active remineralization treatment[31].

In general, the ideal age for MIH epidemiological studies is 7 - 8 years, during which the first four permanent molars will have erupted and enamel loss due to dental caries or other diseases would not have started yet. In addition, at this age, children still possess a residual part of the second molar, which makes it possible to evaluate the correlation between MIH

and second-molar hypomineralization. Elfrink *et al.* recently suggested that primary molar hypomineralization and MIH are correlated and that the former could be a predictor of MIH[32]. In the present study, although the entire permanent dentition was evaluated, hypomineralization of second permanent molars was the focus of evaluation. Therefore, subjects with complete dentition, between the ages of 14 and 16 years, were enrolled as study subjects.

The most active research on prevalence of MIH is conducted in Europe, where prevalence levels ranging from 3.6% to 37% have been reported[10]. In Asian countries, prevalence of MIH has been reported to be 2.8% in Hong Kong[33], 25.5% in China[34], 20% in Thailand[35], and 6.0% in South Korea[20]. This variation in prevalence might be attributable to environmental or genetic factors or even differences in research methodology and criteria among various studies[10]. In the present study, the prevalence of MIH was 13.8%, which increased to 23.2% upon expanding the study sample to include subjects in the stage prior to permanent dentition. This value is slightly higher compared to that reported in a nationwide survey in 2010, probably because the previous study included children in Pusan and larger cities as test subjects, while the present study only included subjects from a provincial area in Yangsan. Because the residents of this province have lower socio-economic status and limited access to health services in comparison with residents of bigger cities, the risks of development and progression of oral diseases among the former are known to be high. Epidemiological studies on MIH have also reported

that children living in provincial areas exhibit higher prevalence of MIH than those living in cities[36].

In the present study, the average number of teeth with lesions in the EH and MH groups were 3.88 and 5.18, respectively, with no significant differences according to sex. These values were higher compared to those reported in 6 to 12-year-old children in Brazil at 3.3[37], 12-year-old children in Hong Kong at 2.6[33], and 8-year-old children in Spain at 3.5[38].

In the EH group, mandibular first permanent molars were the most commonly affected teeth, followed by maxillary central incisors, maxillary first permanent molars, and mandibular second permanent molars, in that order. These results indicating high prevalence of MIH in first permanent molars and maxillary central incisors are consistent with those of previous studies[36]. It is noteworthy that the proportion of affected second permanent molars, which are generally excluded from MIH diagnosis, was relatively high. It is, therefore, necessary to study hypomineralization in second permanent molars, which experience a relatively high proportion of occlusal forces. In the MIH group, where subjects exhibited defects in first permanent molars, the results of correlation analysis demonstrated that presence of defects in first permanent molars indicated a high possibility of presence of defects in the remaining permanent teeth, with the correlation being especially strong among central incisors and second permanent molars. Given the strong correlation between MIH in first and second permanent molars, extraction of MIH-affected first permanent molars-which is one of the treatment choices-should be planned carefully.

In the present study, the pattern of MIH defects varied according to tooth type. Demarcated opacity was the most commonly observed defect at 99.7% in anterior teeth, probably because the positional characteristics of anterior teeth renders them unaffected by bite forces and also decreases their chances of developing crown fractures from external factors. First permanent molars exhibited similar proportions of demarcated opacity at 49.6% and atypical restoration at 46.1%, which indicated a history of hemorrhoid damage. The highest prevalence of demarcated opacity was observed in second permanent molars at 85.8%. Since the present subjects had just experienced eruption of second permanent molars, we believe that they might not have yet suffered enamel loss due to occlusal forces or dental caries. In the absence of appropriate regulated treatment for demarcated opacity, there is a very high chance

that the condition could progress into first permanent molars and atypical restorations.

Subjects with enamel hypomineralization in anterior teeth frequently experienced esthetic dissatisfaction. In this study, among the six anterior teeth, high prevalence of enamel hypomineralization was observed in the middle and 1/3 of the incisal edge of maxillary central incisors. Hypomineralization in these teeth becomes evident during smiling, talking, and mastication, which might adversely affect esthetic perception. The present results of the questionnaire survey for subjective esthetic satisfaction revealed lower esthetic satisfaction and greater need for esthetic treatment in presence of defects in anterior teeth, which also reflected the effect of MIH on esthetic satisfaction among patients. Adolescence is a period of transition from childhood to adulthood, which involves physical and psychological changes. Therefore, it is necessary to consider the possibility of loss of self-esteem due to physical defects among adolescents.

V. Conclusion

The present study aimed to investigate the prevalence and distribution of enamel hypomineralization among adolescents. The results indicated a 13.8% prevalence of MIH, which increased to 23.2% upon inclusion of permanent teeth. Enamel hypomineralization in first permanent molars was significantly correlated with that in central incisors and second permanent molars. In anterior teeth, the middle and 1/3 of the incisal edge of maxillary central incisors were the most affected by hypomineralization. Patients with defects in anterior teeth exhibited low esthetic satisfaction and high demand for esthetic treatment.

References

1. Marthaler TM : Changes in dental caries 1953-2003. *Caries Res*, 38: 173-181, 2004.
2. Armfield JM, Spencer AJ : Quarter of century of change: caries experience in Australian children, 1977-2002. *Aust Dent J*, 53:151-159, 2008.
3. Dietrich G, Sperling S, Hetzer G : Molar Incisor Hypomineralisation in a group of children and adolescents living in Germany. *Eur J Paediatr Dent*, 3:133-137, 2003.
4. Crombie FA, Mandton DJ, Kilpatrick NM, *et al.* : Molar incisor hypomineralization: a survey of members of the Aus-

- trilian and New Zealand Society of Paediatric Dentistry. *Aust Dent J*, 53:160-166, 2008.
5. Korean Academy of Pediatric Dentistry : Textbook of Pediatric Dentistry, 5th ed., Dental Wisdom, 93-104, 2014.
 6. Koch G, Hallonsten AL, Ullbro C, *et al.* : Epidemiologic study of idiopathic enamel hypomineralization in permanent teeth of Swedish children. *Community Dent Oral Epidemiol*, 15:279-285, 1987.
 7. Weerheijm KL, Jalevik B, Alaluusua S : Molar-incisor hypomineralisation. *Caries Res*, 35:390-391, 2001.
 8. Elfrink ME, Schuller AA, Veerkamp JS, *et al.* : Hypomineralized second primary molars: prevalence data in Dutch 5-year olds. *Caries Res*, 42:282-285, 2008.
 9. Elfrink ME, Veerkamp JS, Ten Cate JM, *et al.* : Validity of scoring caries and primary molar hypomineralization (DMH) on intraoral photographs. *Eur Arch Paediatr Dent*, 10:5-10, 2009.
 10. Jälevik B : Prevalence and diagnosis of molar-incisor hypomineralization(MIH) : a systematic review. *Eur Arch Paediatr Dent*, 11:59-64, 2010.
 11. Lygidakis NA : Best Clinical Practice Guidance for clinicians dealing with children presenting with Molar-Incisor-Hypomineralisation (MIH): An EAPD Policy Document. *Eur Arch Paediatr Dent*, 11:75-81, 2010.
 12. Beentjes VE, Weerheijm KL, Groen HJ : Factors involved in the etiology of hypomineralized first permanent molars. *Ned Tijdschr Tandheelkd*, 109:387-390, 2002.
 13. Crombie F, Manton D, Kilpatrick N : Aetiology of molar-incisor hypomineralization: a critical review. *Int J Paediatr Dent*, 19:73-83, 2009.
 14. Koch G : Prevalence of enamel mineralization disturbances in an area with 1-1.2 ppm F in drinking water. *Eur J Paediatr Dent*, 4:127-128, 2003.
 15. Balmer R, Tumba J, Duggal M, *et al.* : The prevalence of molar incisor hypomineralisation in Northern England and its relationship to socioeconomic status and water fluoridation. *Int J Paediatr Dent*, 22:250-257, 2012.
 16. Kühnisch J, Thiering E, Heinrich J, *et al.* : Elevated serum 25(OH)-vitamin D levels are negatively correlated with molar-incisor hypomineralization. *J Dent Res*, 94:381-387, 2015.
 17. Jalevik B, Klingberg G : Dental treatment, dental fear and behaviour management problems in children with severe enamel hypomineralization of their permanent first molars. *Int J Paediatr Dent*, 12:24-32, 2002.
 18. Kotsanos N, Kaklamanos EG, Arapostathis K : Treatment management of first molars in children with Molar-incisor hypomineralisation. *Eur J Paediatr Dent*, 12:179-184, 2005.
 19. Cortes MIS, Marcenes W, Sheiham A : Impact of traumatic injuries to the permanent teeth on the oral health-related quality of life in 12-14-year old children. *Community Dent Oral Epidemiol*, 30:193-198, 2002.
 20. Shin JH, Ahn UJ, Jeong TS, *et al.* : The prevalence of molar incisor hypomineralization and status of first molars in primary school children. *J Korean Acad Pediatr Dent*, 37:179-185, 2010.
 21. Federation Dentaire International(FDI) Commission on Oral Health : Research and Epidemiology. A review of the development defects of enamel index(DDE Index). *Int Dent J*, 42:411-426, 1992.
 22. Weerheijm KL, Duggal M, Hallonsten AL, *et al.* : Judgement criteria for Molar Incisor Hypomineralisation (MIH) in epidemiologic studies: a summary of the European meeting on MIH held in Athens, 2003. *Eur J Paediatr Dent*, 4:110-113, 2003.
 23. Leppaniemi A, Lukinmaa PL, Alaluusua S : Nonfluoride hypomineralizations in the permanent first molars and their impact on the treatment need. *Caries Res*, 35:36-40, 2001.
 24. Fagrell TG, Lingstrom P, Noren JG : Bacterial invasion of dentinal tubules beneath apparently intact but hypomineralized enamel in molar teeth with molar incisor hypomineralization. *Int J Paediatr Dent*, 18:333-340, 2008.
 25. Mangum J, Crombie FA, Hubbard MJ : Surface integrity governs the proteome of hypomineralized enamel. *J Dent Res*, 89:1160-1165, 2012.
 26. Weerheijm KL, Groen HJ, Poorterman JH : Prevalence of cheese molars in eleven-year-old Dutch children. *ASDC Journal of Dentistry Child*, 68:259-62, 2001.
 27. Jalevik B, Moller M : Evaluation of spontaneous space closure and development of permanent dentition after extraction of hypomineralized permanent first molars. *Int J Paediatr Dent*, 17:328-335, 2007.
 28. Thilander B, Jacobsen S, Skagius S : Orthodontic sequelae of extraction of permanent first molars. A longitudinal study. *Odont Tidskr*, 71:380-412, 1970.
 29. Williams J, Gowans A : Hypomineralised first permanent molars and the orthodontist. *Eur J Paediatr Dent*, 4:129-132, 2003.
 30. Mastroberardino S, Campus G, Cagetti MG, *et al.* : An Innovative Approach to Treat Incisors Hypomineralization (MIH):

- A Combined Use of Casein Phosphopeptide-Amorphous Calcium Phosphate and Hydrogen Peroxide-A Case Report. *Case Rep Dent*, 1-5, 2012.
31. Baroni C, Marchionni S : MIH supplementation strategies: prospective clinical and laboratory trial. *J Dent Res*, 90:371-376, 2011.
 32. Elfrink ME, ten Cate JM, Veerkamp JS, *et al.* : Deciduous molar hypomineralization and molar incisor hypomineralization. *J Dent Res*, 91:551-555, 2012.
 33. Cho SY, Ki Y, Chu V : Molar incisor hypomineralization in Hong Kong Chinese children. *Int J Paediatr Dent*, 18: 348-352, 2008.
 34. Li L, Li J : Investigation of molar-incisor hypomineralization among children from 6 to 11 years in Lucheng district, Wenzhou city. *Shanghai Kou Qiang Yi Xue*, 21:576-579, 2012.
 35. Pitiphat W, Savisit R, Subarnbhesaj A : Molar incisor hypomineralization and dental caries in six- to seven-year-old Thai children. *Pediatr Dent*, 36:478-82, 2014.
 36. da Costa-Silva CM, Jeremias F, Zuanon AC, *et al.* : Molar incisor hypomineralization: prevalence, severity and clinical consequences in Brazilian children. *Int J Paediatr Dent*, 20:426-34, 2010.
 37. Jeremias F, de Souza JF, Santos-Pinto L : Dental caries experience and Molar-Incisor Hypomineralization. *Acta Odontol Scand*, 71:870-876, 2013.
 38. Garcia-Margarit M, Catalá-Pizarro M, Almerich-Silla JM : Epidemiologic study of molar-incisor hypomineralization in 8-year-old Spanish children. *Int J Paediatr Dent*, 24:14-22, 2013.

국문초록

양산시 거주 청소년의 MIH 유병률과 임상적 특성

신중현 · 이금량 · 김종수 · 김지연 · 김 신

부산대학교 치의학전문대학원 소아치과학교실

본 연구는 영구치열이 완성된 청소년을 대상으로, MIH를 포함한 영구치 법랑질 저광화의 유병률과 분포를 조사하고, 심미적 만족도와 연관성을 파악할 목적으로 시도되었다.

양산시 거주 14 - 16세 청소년 1371명을 대상으로 횡단연구가 수행되었다. MIH를 포함한 법랑질 저광화는 유럽소아치과학회 기준에 의거하여 평가하였다. 전치부 심미성에 대한 설문 조사를 병행하여 전치부 법랑질 저광화의 연관성을 분석하였다.

MIH에 이환된 경우는 189명으로 13.8%의 유병률을 보였다. 모든 영구치 중 1개 이상에서 저광화 병소가 나타난 경우는 318명(23.2%)으로 일반적인 MIH 기준 적용시에 비해 매우 높게 나타났다. 영구치에 나타난 법랑질 저광화 이환 빈도는 하악 제1대구치, 상악 중절치, 하악 제2대구치 순이었다. 전치부에 대한 평가에서는 상악 중절치의 절단면이 가장 높은 이환 빈도를 보였다. 전치부에서 저광화 병소가 존재하는 경우 높은 심미치료 요구도가 관찰되었다.

주요어: Molar incisor hypomineralization, 청소년, 유병률, 전치부, 심미성

www.kci.go.kr