

Minimally Invasive Marsupialization for Treating Odontogenic Cysts: Case Reports

Jiyeon Ryu, Teo Jeon Shin, Hong-Keun Hyun, Youngjae Kim,
Jungwook Kim, Chong-Chul Kim, Ki-Taeg Jang, Sang-Hoon Lee

Department of Pediatric Dentistry, School of Dentistry, Seoul National University

Abstract

Marsupialization and decompression constitute a well-established procedure for treating cavitory bone lesions of the jaw. The technique can be a primary treatment option, especially for pediatric patients with large cysts or lesions involving vital anatomical structures, such as a developing tooth germ. In this procedure, a decompression stent, such as a customized acrylic obturator or space-maintaining appliance, silicone tube, or nasal cannula, is inserted to maintain the patency of the cyst. However, this may cause clinical problems, such as irritation or trauma to the adjacent tissues, as well as discomfort to the patient, or failure of the stent due to cyst shrinkage. It can also be a reason for patient non-compliance. In the cases described here, a minimally invasive marsupialization technique using a metal tube made from a 16-gauge needle was used for odontogenic cysts in pediatric patients associated with unerupted teeth. Through this method, the lesions were removed, with patient cooperation, and the cyst-associated teeth erupted spontaneously.

Key words : Surgical decompression, Drainage, Odontogenic cyst

I. Introduction

Marsupialization and decompression is a principal method for the treatment of odontogenic cysts that has been used widely as a conservative alternative to enucleation, which is considered a radical approach. Enucleation refers to complete removal of the cyst and is generally indicated for small lesions (cysts < 3 cm in diameter)[1]. For larger cysts, this treatment may have complications, such as fracture of the mandible, tooth devitalization, or removal of impacted teeth associated with the lesions that would be better saved[2]. Thus, marsupialization is indicated when treating younger patients, particularly with large cysts close to vital structures, such as adjacent

developing dentition[3,4].

Despite the success of this conservative method in treating odontogenic cysts in young patients, clinicians often encounter problems, such as dislocation of the decompression tube, a complex procedure for fabricating an obturator, and noncompliance of young patients due to discomfort and inconvenience during the course of treatment. Here, we report cases of odontogenic cysts associated with unerupted teeth in pediatric patients. Clinical and radiographic findings suggested that the lesions were inflammatory dentigerous cysts with infected primary teeth. The cysts were treated successfully by a minimally invasive marsupialization technique that used a metal tube made from a 16-gauge needle.

Corresponding author : Ki-Taeg Jang¹, Sang-Hoon Lee²

Department of Pediatric Dentistry, School of Dentistry, Seoul National University, 101 Daehak-ro, Jongno-gu, Seoul, 03080, Korea

¹Tel: +82-2-2072-2682 / Fax: +82-2-744-3599 / E-mail: jangkt@snu.ac.kr

²Tel: +82-2-2072-2680 / Fax: +82-2-744-3599 / E-mail: musso@snu.ac.kr

Received September 20, 2016 / Revised November 22, 2016 / Accepted November 16, 2016

II. Case Reports

1. Case I

A 9-year-old boy was referred from a local clinic for consultation regarding a swelling in the left posterior vestibule of the mandible. Clinical examination showed extra- and intraoral bony expansion of the left primary mandibular molar region, with a normal aspect of oral mucosa. Panoramic and periapical radiographs revealed a well-defined unilocular cystic lesion under the treated left deciduous molar (Fig. 1). The lesion included the tooth germ of the left second premolar; the periapical region of the first molar was also involved, but with no sign of resorption.

Under local anesthesia, the involved primary molar was extracted, followed by marsupialization with metal tube insertion through the extraction socket. For stabilization, the other end of the metal tube was attached to the buccal surface of the adjacent premolar with flowable resin (Fig. 2). Despite the buccal bony expansion, the tooth germ of the premolar was hardly displaced in the mesio-distal direction and it was quite

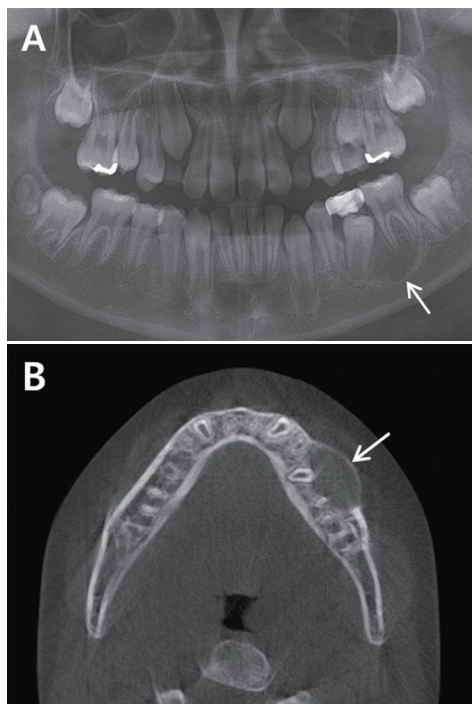


Fig. 1. Panoramic view (A) shows a well-defined osteolytic lesion (white arrow) under the treated left deciduous molar including the tooth germ of the left second premolar and the periapical region of the first molar. the axial computed tomography (CT) view (B) shows expansion of the buccal cortical plate of the mandible (white arrow).

close to the occlusal plane. Therefore, a space maintainer was not necessary. Antibiotics were administered for 7 days to prevent postoperative infection. Regular recall visits were scheduled (every week) for irrigation of the wound during the first month. The positional relationship of the decompression tube in the lesion and the involved erupting tooth was checked radiographically (Fig. 2). After 4 months, the affected tooth

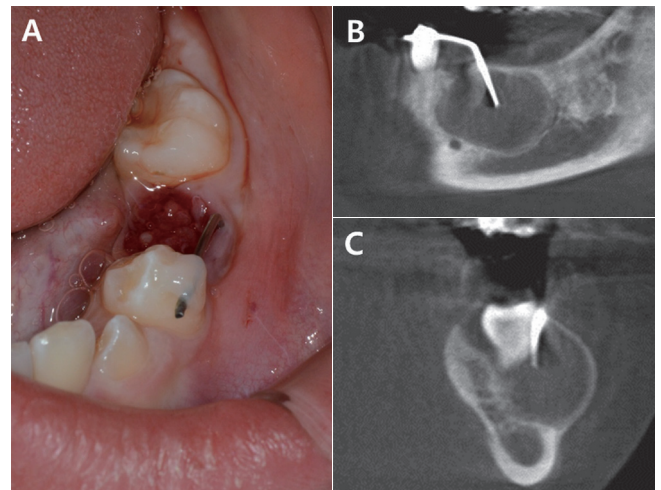


Fig. 2. Intraoral photo (A) shows that the metal tube for decompression was inserted through the extraction socket after the involved primary tooth was removed. The opposite end of the tube was fixed to the adjacent tooth with flowable resin for stability. The appropriate position of the decompression tube can be seen on the sagittal CT view (B) and the coronal view (C).

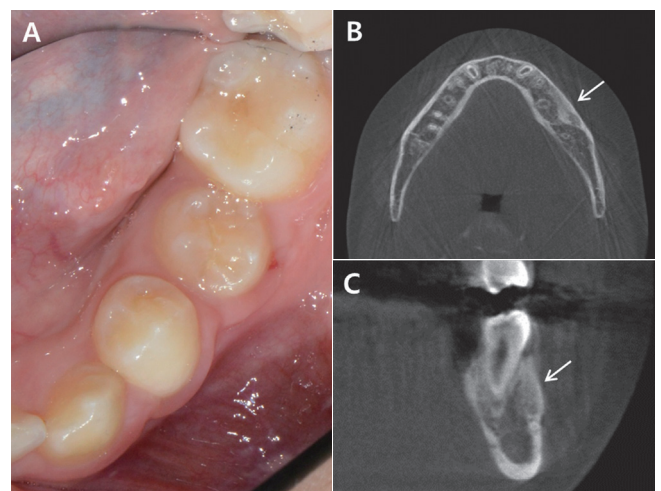


Fig. 3. At 4 months after the procedure, the affected tooth erupted spontaneously (A). CT axial view (B) and coronal view (C) at 7 months after the procedure show a diminished lesion and new bone filling (white arrow).

emerged and the metal tube was removed. The 7-month follow-up visit showed that the cystic lesion had diminished and the premolar had erupted (Fig. 3).

2. Case II

A 9-year-old girl was referred for evaluation of a buccal bony expansion of the right mandibular vestibule. She showed no facial asymmetry but a firm, asymptomatic bony expansion was palpated in the right mandibular region. A cystic lesion involving the roots of the right lower first primary molar and displacement of the succedaneous tooth germ were observed on panoramic and cone beam computed tomography (CBCT) images (Fig. 4). After removal of the primary tooth involved, a transalveolar metal drain was installed for decompression and the patient was treated with antibiotics for 7 days. We did not use a space maintainer because the bucco-lingually displaced permanent tooth germ was located beneath the primary tooth of exfoliation stage.

On the third recall visit, marked regression of the lesion and correction of the eruption path were seen on the periapical X-ray image (Fig. 5). After 2 months, the first right mandibu-

lar premolar had erupted and the drain was removed. At the 6month follow-up visit, there was a fully erupted premolar and the lesion was replaced by the new bone formation (Fig. 6).

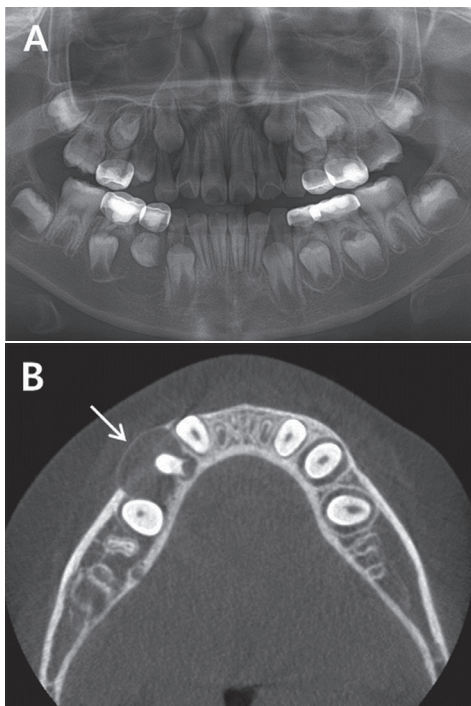


Fig. 4. Panoramic view (A) shows a cystic lesion resolving at the root of the right lower first primary molar. Buccal bony expansion (white arrow) and lingually displaced succedaneous tooth germ were seen on the axial CT view (B).

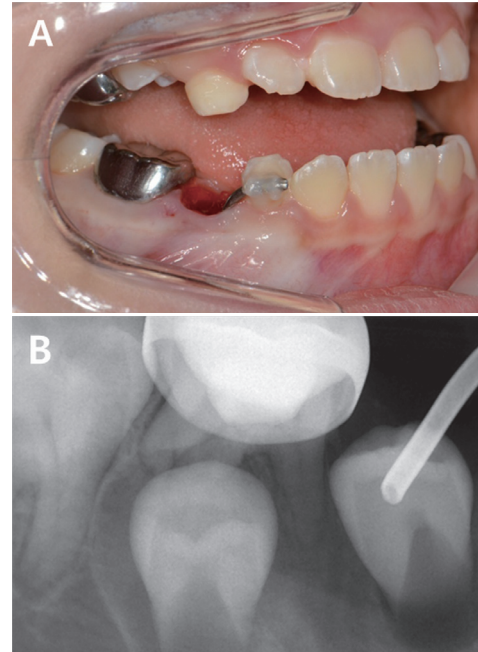


Fig. 5. Intraoral photo (A) shows the decompression stent inserted through the extraction socket of the primary tooth involved. This new type of stent was stable with only resin bonding, so no other invasive procedure for fixation, such as a suture, was needed. The position of the metal tube relative to the lesion was checked radiographically (B).

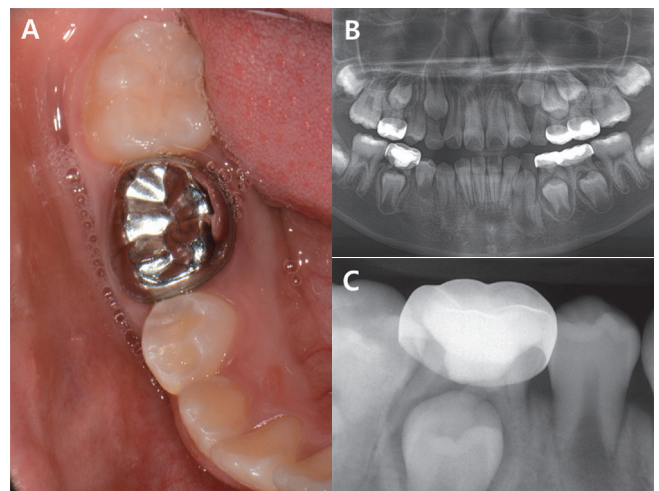


Fig. 6. After 6 months, the affected first premolar erupted spontaneously (A). In the panoramic view (B) and periapical X-ray image (C), the radiolucent lesion was replaced by new bone formation.

3. Case III

A 10-year-old girl was referred from a local clinic for enucleation of a cyst under the right primary molar area. On intraoral inspection, a large restoration of the involved primary molar was observed. Panoramic and periapical radiographs showed a well-defined radiolucent lesion, associated with the treated deciduous molar and the second premolar, with an ectopic eruption path (Fig. 7). Under local anesthesia, the infected primary molar was extracted and a space-maintainer was set in place to prevent space loss during the corrected eruption path. A metal tube was installed through the extraction socket for marsupialization because the cyst cavity was not opened to the oral cavity when the infected primary tooth was extracted (Fig. 8). After 2 months, apparent reduction of the lesion was recognized radiographically and the drain was removed. One month later, the second premolar erupted spontaneously, so the band and loop appliance were removed.

III. Discussion

A dentigerous cyst is an odontogenic cyst associated with the crown of an unerupted tooth that results when pressure from an erupting tooth obstructs venous flow, resulting in accumulation of exudate between the tooth crown and the follicle[5]. Daley and Wysocki[6] stated that dentigerous cysts can be diagnosed based on a pericoronal radiolucency of > 4 mm in width. Dentigerous cysts are classified into two types according to their origin: developmental or inflammatory[7]. In three cases, the widths of the pericoronal radiolucency were greater than 4 mm and the lesions were closely associated with periapical inflammation of nonvital deciduous teeth. Therefore, we diagnosed the lesions as inflammatory dentigerous cysts. Benn and Altini[8] suggested three etiological mechanisms of inflammatory cysts: 1) secondary infection of a developmental dentigerous cyst due to periapical inflammation that spreads from a nonvital deciduous predecessor; 2) fusion

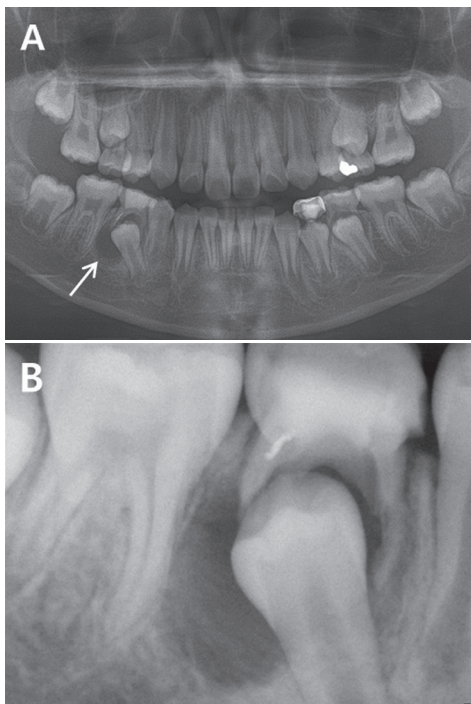


Fig. 7. Panoramic and periapical radiographs (A, B) show a well-defined radiolucent lesion (white arrow) associated with the treated deciduous molar and second premolar with an ectopic eruption path. Osteosclerotic change around the cyst wall due to the chronic inflammation state is shown.

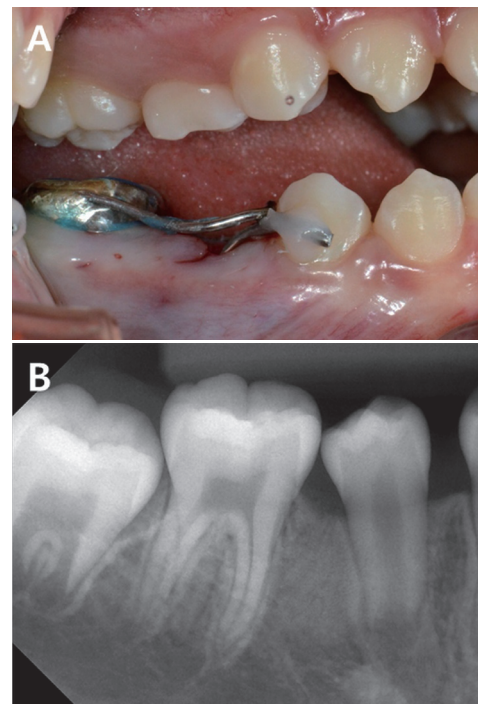


Fig. 8. Intraoral view (A) after the marsupialization procedure shows a space-maintainer and a metal drain applied at the marsupialization cavity. It also can be seen that the primary molar involved was removed. Then, 6 months later, the periapical view (B) shows that the affected premolar erupted spontaneously.

of a radicular cyst of a nonvital deciduous tooth with the follicle of an unerupted successor; 3) infection of a follicle of an unerupted permanent tooth due to periapical inflammation of a nonvital deciduous tooth.

All of the cases were treated by extraction of the nonvital infected primary tooth and marsupialization of the cyst to allow eruption of the permanent tooth. Space maintainers were used in cases of possible space loss. In Cases I and II, a space maintainer was not necessary since the cysts were on the buccal side, leading to only minimal dislocation mesiodistally of succedaneous teeth. However, in Case III, the eruption path was considerably altered, so a band and loop was set concurrently with marsupialization.

After marsupialization, the size of the lesion is reduced and new bone formation is usually also achieved. The technique is an effective and advantageous method to treat odontogenic cysts in young patients, especially for large lesions involving unerupted teeth and important neighboring anatomical structures, such as the inferior alveolar nerve and maxillary sinus. Enislidis *et al.*[1] recommended decompression for large mandibular cysts in compliant patients, emphasizing advantages including minimal invasion, low morbidity, and the absence of severe complications, such as infection, mandibular fracture, and recurrence of the lesion.

Since the technique was first introduced by Partsch in 1899[9,10], many devices have been used to maintain the patency of the cyst during decompression. Pogrel[9] used iodoform packing gauze impregnated with bacitracin ointment, which helped to maintain patency by protruding through the cyst window in the maxilla. In the mandible, Pogrel used a nasopharyngeal anesthesia tube, suitably cut down, as a stent to keep the cyst open. August[11] also used a modified pediatric airway device, providing a portal for irrigation. Several authors have mentioned removable devices, such as a customized acrylic obturator, a space-maintaining appliance with a resin projection, and a modified removable partial denture[3,12-16]. Others have reported using various modified tubes as decompression catheters. Kolokythas *et al.*[17] used sections from a polyethylene tube cut to various lengths, modified by the creation of a flange at the end. Enislidis *et al.*[1] also described a custom-made plastic tube with a flange. Tolstunov[18] recommended several modified catheters made from an intravenous (IV) administration set (injection site or spin-lock connector), nasal cannula (O₂ connector), and the funnel end of an all-purpose urethral catheter. Park[7] used a penrose drain inserted

into the extraction socket, and also applied a modified chemoport catheter through a marsupialized cavity.

Enislidis *et al.*[1] reported that the most common complications during decompression were 1) repeated occlusion of the stent by detritus, 2) necrosis and scarring of tissue adjacent to the stent, and 3) displacement of the drain tube, sinking down to the lumen of the cyst, or its loss. Tolstunov[18] described the characteristics of an 'ideal' marsupialization stent or drainage tube for treating cysts of the jaw: 1) a design that prevents it from dislocating into or out of the bone cavity until the end of the procedure; 2) sufficiently small so as not to interfere with daily mastication; 3) easy to fix to soft tissue with sutures; 4) the possibility of daily irrigation of the cystic cavity; and 5) hygiene over the expected life of the device.

Many previous studies have demonstrated good results in preserving the cyst-involved tooth when marsupialization is performed in pediatric patients, and the cases above also support the effectiveness of a decompression technique. Here, spontaneous eruption of cyst-associated teeth and new bone formation were achieved with a minimally invasive marsupialization technique, using a metal tube as a decompression stent. The metal drain can be inserted readily into the lumen of the cyst through the extraction socket of the primary tooth involved, with no additional window opening. After mild bending of the metal tube, it can be fixed by resin bonding to the adjacent tooth, which is more stable, simple and comfortable than suturing to the mucosa. Furthermore its radiopaque characteristics help in accurately determining the drain location. The size of the lesion and the distance from the center of lesion to the occlusal plane were measured via CT or panoramic imaging and the metal tube was cut and bent based on these measurements. In Cases I and II, the lesion had extended to the buccal side and the involved permanent tooth germ had been displaced lingually, so the tube was inserted and fixed at the buccal side of the extraction socket with the tip of the tube in the middle of the lesion. After placing a drain, the location of the tube was checked radiographically, allowing it to be properly adjusted as the lesion resolved. If radiographic examination reveals either interference of the stent with a cyst-associated erupting permanent tooth or an overlong stent, as compared to the diminished lesion, the existing stent can be cut and fixed again, or a new, shorter stent can replace the existing one.

According to a number of records, odontogenic cysts that are associated with 1-2 permanent teeth and range in size

from 2.0 cm to 4.0 cm require 6-20 months after surgery to completely resolve, allowing eruption of the permanent tooth[2,3,19]. The cysts in our cases measured 1.5-2.0 cm and, considering that 3-7 months were needed for completion of these events, and the stents were removed 2-4 months after the procedure, the decompression capacity seems sufficient despite the small diameter (approximately 1.2 mm inner diameter) of the metal drain.

In these cases, a small-diameter needle was preferred, to reduce the possibility of contamination of the lesion and to achieve ease of manipulation. To maintain patency after the bending of the tube, a 16-gauge needle was finally selected because the inside of smaller needles became blocked when bending them. Daily irrigation was not essential as the possibility of contamination and infection was very low, due to the narrow inner diameter and bent configuration of the tube. Drain obstruction caused by debris was never observed during the post-surgery follow-up period.

Since this marsupialization technique needs the decompression stent to be fixed with resin to the adjacent tooth, the application of this method is limited if adjacent tooth is missing or stainless steel crowned. Application of modified removable appliance could be considered in above mentioned cases and further study is needed to overcome these limitations.

IV. Summary

Currently, no uniform decompression stent is available; various custom-made devices have been used in marsupialization cases. In the marsupialization cases we describe in young patients, we used a metal tube modified from a 16-gauge IV needle as a decompression drain and achieved favorable results. We recommend this simplified technique to minimize trauma to soft tissues and discomfort to the patient – which can greatly affect compliance – and to maximize retention and stability, and facilitate location of the device.

References

1. Enislidis G, Fock N, Sulzbacher I, Ewers R : Conservative treatment of large cystic lesions of the mandible: a prospective study of the effect of decompression. *Br J Oral Maxillofac Surg*, 42:546-550, 2004.
2. Berti Sde A, Pompermayer AB, *et al.* : Spontaneous eruption of a canine after marsupialization of an infected den-

- tigerous cyst. *Am J Orthod Dentofacial Orthop*, 137:690-693, 2010.
3. Wiemer SJ, Pruitt CA, Rallis DJ, Viozzi CF : Use of a modified removable partial denture as a marsupialization stent in a pediatric patient. *J Oral Maxillofac Surg*, 71:1382-1386, 2013.
4. de Paulo LFB, da Cruz Perez DE, *et al.* : Giant facial dermoid cyst: A case treated by marsupialization. *Revista Portuguesa de Estomatologia, Medicina Dentária e Cirurgia Maxilofacial*, 55:167-170, 2014.
5. Browne RM : The pathogenesis of odontogenic cysts a review. *J Oral Pathol*, 4:31-46, 1975.
6. Daley TD, Wysocki GP : The small dentigerous cyst. *Oral Surg Oral Med Oral Pathol Oral Radiol Endod*, 79:77-81, 1995.
7. Park C, Park K : Surgical Management of Dentigerous Cyst for Preserving Permanent Tooth Buds. *J Korean Acad Pediatr Dent*, 41:85-92, 2014.
8. Benn A, Altini M : Dentigerous cysts of inflammatory origin A clinicopathologic study. *Oral Surg Oral Med Oral Pathol Oral Radiol Endod*, 81:203-209, 1996.
9. Pogrel MA : Treatment of keratocysts: the case for decompression and marsupialization. *J Oral Maxillofac Surg*, 63:1667-1673, 2005.
10. Gutmann JL, Gutmann MS : Historical Perspectives on the Evolution of Surgical Procedures in Endodontics. *J Hist Dent*, 58:1-42, 2010.
11. August M, Faquin WC, Troulis MJ, Kaban LB : Dedifferentiation of odontogenic keratocyst epithelium after cyst decompression. *J Oral Maxillofac Surg*, 61:678-683, 2003.
12. Carter LM, Carr P, Wales CJ, Whitfield PH : Customised stents for marsupialisation of jaw cysts. *Br J Oral Maxillofac Surg*, 45:429-431, 2007.
13. Uloopi KS, Shivaji RU, *et al.* : Conservative management of large radicular cysts associated with non-vital primary teeth: a case series and literature review. *J Indian Soc Pedod Prev Dent*, 33:53-56, 2015.
14. Akay MC, Kaya E, Zeytinoglu M : Treatment of nonsyndromic dentigerous cysts in primary dentition. *Clin Cosmet Investig Dent*, 3:17-23, 2011.
15. Nakamura N, Mitsuyasu T, *et al.* : Marsupialization for odontogenic keratocysts: Long-term follow-up analysis of the effects and changes in growth characteristics. *Oral Surg Oral Med Oral Pathol Oral Radiol Endod*, 94:543-553, 2002.
16. Jih M, Lee S, Lee N : Orthodontic Traction and Decompres-

- sion Method in Treating Impacted Permanent Mandibular First Molars : Case Reports. *J Korean Acad Pediatr Dent*, 42:257-263, 2015.
17. Kolokythas A, Schlieve T, Miloro M : Simple method for securing a decompression tube for odontogenic cysts and tumors: a technical note. *J Oral Maxillofac Surg*, 69:2392-2395, 2011.
 18. Tolstunov L : Marsupialization catheter. *J Oral Maxillofac Surg*, 66:1077-1079, 2008.
 19. Martinez-Perez D, Varela-Morales M : Conservative treatment of dentigerous cysts in children: a report of 4 cases. *J Oral Maxillofac Surg*, 59:331-333, 2001.

국문초록

최소 침습적 조대술을 이용한 치성낭종의 치료 증례 보고

류지연 · 신터전 · 현홍근 · 김영재 · 김정욱 · 김종철 · 장기택 · 이상훈

서울대학교 치과대학 소아치과학교실

조대술 및 감압술은 악골내 치성기원 낭종에 대한 치료법으로서 여러 문헌을 통해 그 효과가 확립되어 왔다. 특히, 소아치과 영역에서 병소 크기가 크거나 발육 중인 치배 등 중요 구조물을 포함한 경우 보존적인 치료로서 우선적 대안이 될 수 있다. 조대술 후에는 낭종의 개방성 유지를 위해 맞춤 제작 아크릴 폐쇄장치(obturator) 또는 공간유지장치, 실리콘 관, 비강 캐놀라 등의 감압 스텐트(decompression stent)를 사용하는데, 이는 주변 연조직 자극 및 환아의 불편감, 낭종 크기 감소에 따른 탈락 가능성 등 임상적 문제점을 지니며 환아 협조도 저하의 원인이 되기도 한다.

본 증례들에서는 하악골 부위 영구 치배를 포함한 치성 낭종에 대하여 감압술시행시 16개이지 정맥 주사바늘을 활용한 금속관을 발치와를 통해 낭종 내부로 삽입하고 인접치에 레진으로 고정하는 최소 침습적 시술을 통해 환아의 양호한 협조하에 병소 제거 및 자발적 맹출을 유도하는 결과를 얻었기에 보고하는 바이다.

주요어: 감압술, 감압 스텐트, 치성 낭종