

Hypersensitivity to Local Anesthetics: A Case Report

Yujin Rah, Jewoo Lee, Jiyoung Ra

Department of Pediatric Dentistry, College of Dentistry, Wonkwang University

Abstract

Local anesthetics are widely used in clinical dentistry. However, while rare, there have been some reports of true hypersensitivity to local anesthetics.

A case of hypersensitivity in a 26-month-old boy is reported. After administering local anesthesia with lidocaine, treatment was performed while the patient was under oral sedation. After treatment, the patient presented with lower lip edema. Treatment with anti-histamines and a steroid successfully reversed his symptoms.

Key words : Hypersensitivity, Local anesthetics, Lidocaine

I. Introduction

Local anesthetics are injectable drugs frequently used in clinical dentistry[1]. Since the anesthetic effect of cocaine was first discovered in 1884, these drugs have been extensively used, and true hypersensitivity to local anesthetics is very rare[2].

The molecular structure of local anesthetics comprises a lipophilic aromatic ring and a tertiary amine with an intermediate linkage[3]. Anesthetics are classified as either ester- or amide-type local anesthetics based on this intermediate linkage[4]. Differences in chemical structures affect drug duration, efficacy, and toxicity[2]. Para-aminobenzoic acid is a metabolite from ester-type local anesthetics that can induce hypersensitivity. Conversely, metabolites from amide-type local anesthetics are less likely to induce hypersensitivity[5].

The present case involved a patient who presented with delayed swelling of the lower lip after receiving cavity treatment

under local anesthesia with lidocaine. He was diagnosed with hypersensitivity to lidocaine. We report the case and discuss appropriate measures for preventing and treating patients with hypersensitivity.

II. Case Report

A 26-month-old boy visited at the Department of Pediatric Dentistry, Wonkwang University Dental Hospital with a cavity in primary molar teeth. His medical, familial and dental histories were unremarkable. Clinical and radiographic examinations revealed the presence of occlusal caries bilaterally in the lower first primary molars (Fig. 1). Considering the patient's age, we decided to proceed with treatment under oral sedation. Approximately 1 hour before initiating the treatment, the patient was orally administered 900 mg chloral hydrate (Pocral[®], Hantlim) and 20 mg hydroxyzine (Ucerax[®], UBC). The mucobuccal folds of both lower first primary molars were injected with 0.6

Corresponding author : Jiyoung Ra

Department of Pediatric Dentistry, College of Dentistry, Wonkwang University, 895 Muwang-ro, Iksan, Jeollabuk-do, 54538, Korea

Tel: +82-63-850-6633 / Fax: +82-63-851-5324 / E-mail: pedojoy@wku.ac.kr

Received September 5, 2016 / Revised October 25, 2016 / Accepted October 24, 2016

www.kci.go.kr

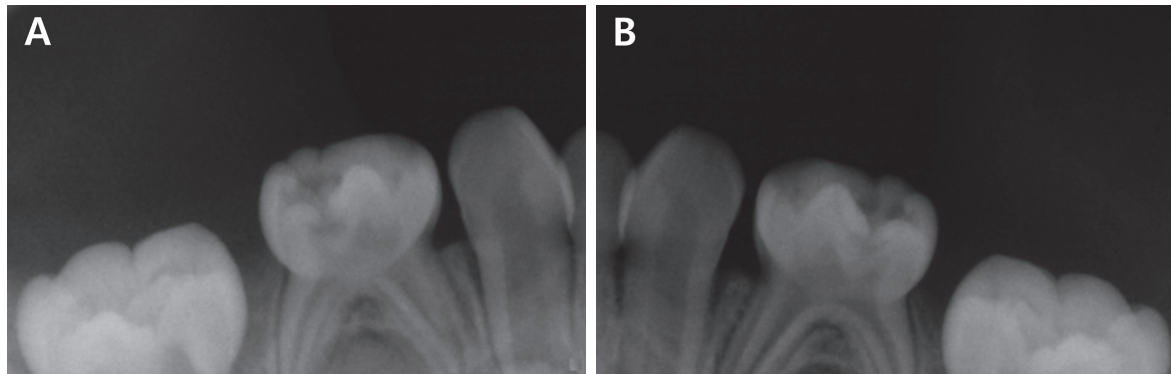


Fig. 1. Preoperative periapical radiography (A) Right (B) Left.

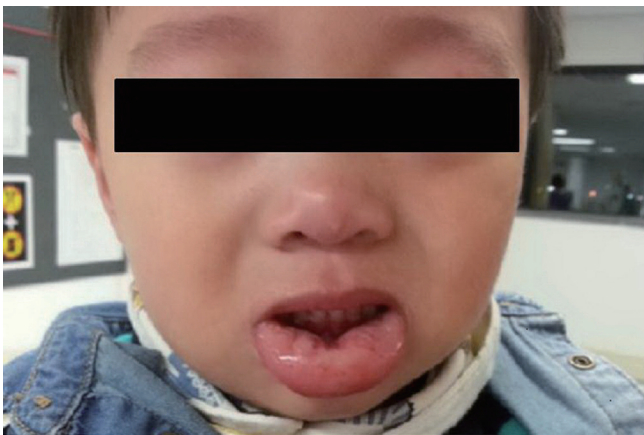

Fig. 2. Extraoral photograph showing lip swelling.



Fig. 3. Skin prick test with saline (C) and lidocaine.

mL of 2% lidocaine hydrochloride with 1 : 100,000 epinephrine (2% Lidocaine HCl · Epinephrine Inj., Yuhan). The right lower first primary molar was restored with resin after indirect pulp capping, while the left lower first primary molar was restored with a glass ionomer. The patient's condition was checked after treatment and before he returned home.

After returning home, the patient presented to the emergency room at Wonkwang University Dental Hospital due to lower lip edema (Fig. 2). After explaining the possibility of lidocaine hypersensitivity to his parents, the patient was moved to an emergency room at Wonkwang University Medical Hospital. Clinical examination revealed localized swelling and pain at the injection site in the absence of other symptoms such as fever, headache, or difficulty breathing.

With his parent's signed permission, a skin prick test (SPT)

was administered using lidocaine. SPT results were read after 15 minutes and were positive (Fig. 3). The dermatologist diagnosed the patient with angioedema due to a hypersensitivity to lidocaine. An intramuscular injection of an anti-histamine and a steroid were administered, and the patient was prescribed oral anti-histamines.

III. Discussion

True hypersensitivity to local anesthetics is very rare, accounting for less than 1% of adverse events caused by local anesthetics[6]. However, some patients complain of symptoms similar to hypersensitivity after local anesthesia. Adverse reactions that may be mistaken for hypersensitivity include syncope, panic attack, and toxic effects; therefore, it is important

to identify the cause of the symptoms in these cases[7].

In the case of local anesthetic hypersensitivity, it is possible that other constituents in the injection solution besides the active drug could have caused the reaction. Allergic responses also can be due to preservatives or antioxidants in the injection solution[8], as well as latex from gloves, rubber dams, or rubber bungs of the cartridge[9]. However, most adverse reactions associated with local anesthetics during dental treatment are psychogenic. The most common psychogenic reaction is syncope, which can be accompanied by a panic attack, hyperventilation, nausea, vomiting, or heart rate or blood pressure alterations[10]. In addition, a high concentration of local anesthetic in systemic circulation due to repeated injections, accidental intravascular injection, or overdose can cause toxic reactions[2,11].

In the present case, the hypersensitivity reaction was not attributed to latex because a rubber dam was not used during treatment, and there was no evidence of hypersensitivity when latex gloves were used during oral examinations. In addition, the sedative dose was based on the patient's weight, and the dosage of lidocaine was appropriate. A systemic toxic reaction to local anesthetics or other medications was not considered because there were no signs of other systemic symptoms.

Becker and Kenneth[3] summarized the management of patients allergic to local anesthetics using a flowchart. First, the patient's past medical and dental history should be investigated. Next, common reactions should be ruled out based on symptoms, to distinguish hypersensitivity from syncope or tachycardia caused by epinephrine. If the reaction involves a rash, pruritus, urticaria, or dyspnea, the patient can be diagnosed with hypersensitivity. If the patient knows which drug is causing the hypersensitivity, an alternative drug should be selected. However, if the drug is unknown, an allergist should be consulted for testing. In particular, it is recommended that patients are referred to an allergist for assessment of reactions to frequently used anesthetics, such as lidocaine and benzocaine, as well as sulfite preservatives.

These principles are basic approaches, but patient history is not often useful in pediatric dentistry. In many cases, patients have not previously visited a pediatric dentist, or have no experience with local anesthesia. Similar to the patient in the present case, it is possible to be unaware of a hypersensitivity to local anesthetics, and symptoms could appear during or immediately after the treatment. If symptoms suggestive of a true hypersensitivity occur, the patient should be given immediate

treatment. Hypersensitivity to local anesthetics can range from mild to severe. Mild skin response can be managed with oral or intramuscular anti-histamine. A rapid allergic reaction should alert clinicians to a possible anaphylactic response. If acute signs of an anaphylactic response occur, basic life support, intramuscular or subcutaneous epinephrine, and transportation to the emergency room may be required[12].

Patients diagnosed with hypersensitivity to lidocaine should be referred for further investigation to confirm the allergen[13]. Results of allergy testing will identify a specific local anesthetic that can be used for dental anesthesia[12]. During the treatment, the clinician should treat all patients carefully with reassurance to relieve fear and anxiety, use an aspirating syringe, inject slowly, and monitor any adverse reactions[13].

IV. Summary

Hypersensitivity to amide-type local anesthetics is extremely rare, but can occur. Therefore, clinicians need to know how to prevent and cope with hypersensitivity to local anesthetics.

References

1. Bennett CR : Monheim's local anaesthesia and pain control in dental practice, 7th ed., Mosby, 225-237, 1984.
2. Lukawaska J, Caballero MR, Tsabouri S, Dugué P : Hypersensitivity to local anaesthetics-6 facts and 7 myths. *Current Allergy&Clinical Immunology*, 22:117-120, 2009.
3. Becker DE, Reed KL : Local anesthetics: review of pharmacological considerations. *Anesth Prog*, 59:90-102, 2012.
4. Henderson S : Allergy to local anaesthetic agents used in dentistry- what are the signs, symptoms, alternative diagnoses and management options? *Dent Update*, 38: 410-412, 2011.
5. Baluga JC, Casamayou R, Carozzi E, *et al.* : Allergy to local anaesthetics in dentistry. Myth or reality? *Allergol Immunopathol*, 30:14-19, 2002.
6. Selcuk E, Erturk S, Afrashi A : An adverse reaction to local anaesthesia: Report of a case. *Dent Update*, 23:345-346, 1996.
7. Scully C, Cawson RA : Medical problems in dentistry, 6th ed., Elsevier Churchill Livingstone, 51, 2010.
8. Wildsmith JA, Mason A, McKinnon RP, Rae SM : Alleged allergy to local anaesthetic drugs. *Br Dent J*, 184:507-510, 1998.

9. Harper NJ, Dixon T, Dugue P, *et al.* : Suspected anaphylactic reactions associated with anaesthesia. *Anaesthesia*, 64:199-211, 2009.
10. Haas DA : An update on local anaesthetics in dentistry. *J Can Dent Assoc*, 68: 546-551, 2009.
11. Wilson AW, Deacock S, Downie IP, Zaki G : Allergy to local anaesthetic: the importance of thorough investigation. *Br Dent J*, 188:120-122, 2000.
12. Finder RL, Moore PA : Adverse drug reactions to local anesthesia. *Dent Clin N Am*, 46:747-757, 2002.
13. Rood JP : Adverse reaction to dental local anaesthetic injection--'allergy' is not the cause. *Br Dent J*, 189:380-384, 2000.

국문초록

국소마취제로 인한 과민반응 : 증례 보고

나유진 · 이제우 · 라지영

원광대학교 치과대학 소아치과학교실

국소마취제는 치과 영역에서 임상적으로 널리 사용되어 왔으나, 국소마취제로 인한 과민반응은 매우 드물게 나타난다. 그러나 낮은 발생률에도 불구하고, 국소마취제로 인한 과민반응 증례가 보고되어 왔다.

본 증례는 충치치료를 주소로 내원한 26개월 남환에서 관찰된 과민반응으로, 리도카인 국소마취 후 하순의 부종이 발생하였다. 항히스타민제와 스테로이드의 사용으로 증상이 경감되었다.

주요어: 과민반응, 국소마취제, 리도카인

www.kci.go.kr