

Prognosis of the Apical Fragment of Root Fractures after Root Canal Treatment of Both Fragments in Immature Permanent Teeth

Jaesik Lee, Soonhyeun Nam

Department of Pediatric Dentistry, School of Dentistry, Kyungpook National University

Abstract

In the root fracture, pulp necrosis tends to involve only the coronal fragment, while the pulp in the apical fragment remains vital. The prognosis of endodontic treatment of the apical fragment is poor due to the possibility of overfilling of the space between the fragments and difficulty in removing necrotic tissue.

In the present cases, endodontic treatment of the apical fragment of root fracture was performed. However, in re-endodontic treatment, resistance was felt at the fracture site and access to the root canal in the apical fragment was difficult. Therefore, the calcium hydroxide was periodically exchanged only in the coronal fragment without further treatment in the apical fragment and the canal of the coronal fragment was finally filled with Gutta-percha.

Regular observation revealed no radiologic complications in the apical fragment. In some cases, we can observe good healing pattern such as absorption of calcium hydroxide and pulp canal obliteration of apical fragment in the long term.

Key words : Root fracture, Calcium hydroxide, Apical fragment

I. Introduction

Root fracture is defined as a fracture involving the dentin, cementum, and pulp, and accounts for 0.5 - 7.0% of all cases of permanent tooth trauma[1,2]. Clinically, there is a slight extrusion and palatal displacement at the time of root fracture, but radiographic examination is essential for accurate diagnosis[1]. The fracture line of most root fractures is oblique, and so can be easily detected by radiography. However, root fracture is rarely observed immediately after trauma in the case of the fracture line is closed, instead appearing on subsequent radiograph, likely due to displacement of the coronal fragment or absorption of the fracture line site as time goes by[3].

To treat root fracture of a permanent tooth, a displaced coronal fragment is repositioned and fixed firmly or semi-rigidly[1]. Andreasen *et al.*[4] recommended 3 to 4 weeks for fixation of a root-fractured tooth. However, when the fracture site is close to the cervical, or if the tooth is very loose, 2 to 3 months is recommended.

There are 4 types of root-fracture healing: healing with calcified tissue, healing with connective tissue, healing with calcified and connective tissue, and healing with granulation tissue. The type of healing is dependent on the developmental state of the root, degree of trauma, site of tooth fracture, and treatment method[5,6].

Pulp necrosis with subsequent periradicular involvement oc-

Corresponding author : Soonhyeun Nam

Department of Pediatric Dentistry, School of Dentistry, Kyungpook National University, 2177, Dalgubeol-daero, Jung-gu, Daegu, 41940, Korea

Tel: +82-53-600-7201 / Fax: +82-53-426-6608 / E-mail: shnam@knu.ac.kr

Received November 24, 2017 / Revised December 21, 2017 / Accepted December 8, 2017

www.kci.go.kr

curs in about 25% of root fractured teeth. Because root fracture tends to dislocate only the coronal fragment, pulpal circulation in the apical fragment is not severely disturbed[7]. Thus, pulp necrosis usually occurs only in the coronal fragment, while the pulp in the apical fragment remains vital. However, if pulp necrosis of the coronal fragment is left untreated, the bacteria may spread and cause inflammation and necrosis of the pulp in the apical fragment[8].

In root fracture, because of overfiling during removal of pulp tissue, endodontic treatment of the apical fragment can be performed unintentionally. This report presents 3 cases of endodontic treatment of the apical fragment, each of which has a good prognosis. Healing of the apical fragment following root fracture is also discussed.

II. Case Reports

1. Case 1

A 7-year-old boy attended the Department of Pediatric Dentistry due to a fall. Clinical and radiologic findings were diagnostic of root fracture of the right permanent central incisor (Fig. 1A). Reduction of the coronal fragment and resin wire splinting were performed (Fig. 1B). At the 2-month follow-up, diagnosed as pulp necrosis of the apical fragment, pulp extirpation, calcium hydroxide canal filling, and splint removal were performed (Fig. 1C). During this procedure, root canal treatment of the apical fragment was performed (Fig. 1D).

After 3 months, calcium hydroxide between the fragments had begun to be absorbed (Fig. 2A), therefore we tried to exchange total calcium hydroxide. Because resistance was felt at the fracture site and access to the root canal in the apical fragment was difficult, we exchanged the calcium hydroxide in the coronal fragment, and monitored the apical fragment. Subsequently, calcium hydroxide was exchanged only in the coronal fragment after 6 months (Fig. 2B). After 2 years, the coronal fragment canal was filled with Gutta-percha and the apical fragment was monitored continuously (Fig. 2C). After 4 years, calcium hydroxide in the apical fragment had been absorbed and there were no complications (Fig. 2D).

After 8 years, calcium hydroxide was completely absorbed and pulp canal obliteration was observed in the apical fragment (Fig. 3A). After 9, 10, and 11 years, pulp canal obliteration in the root-fractured teeth had continued (Fig. 3).

2. Case 2

A 12-year-old boy with mental retardation visited our hospital due to tooth trauma. At the initial visit, an oral and radiographic examination led to diagnosis of intrusion and crown fractures without pulp exposure of the upper left and right central incisors (Fig. 4A).

On the day of visit, reduction of the intruded teeth into their original positions and wire splinting were performed (Fig. 4B). 2 weeks later, pulp extirpation was performed. After 1 month, the root canal was filled with calcium hydroxide (Fig. 4C).

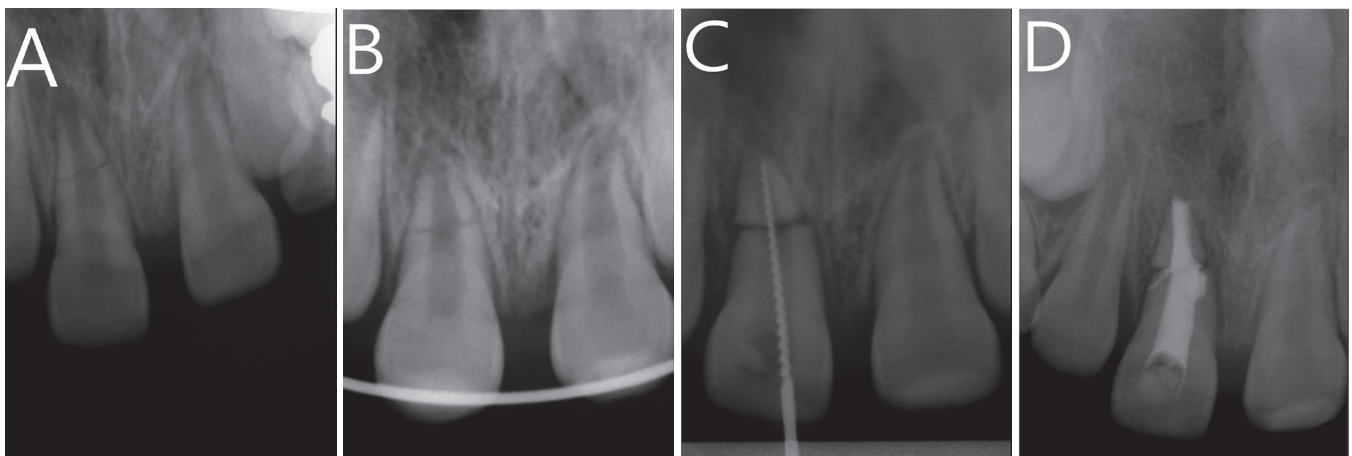


Fig. 1. Periapical radiographs of a root fracture. (A) Initial periapical view. (B) Reduction and wire-splinted root-fractured tooth. (C) Pulp extirpation and (D) Calcium hydroxide canal filling were performed after 2 months.

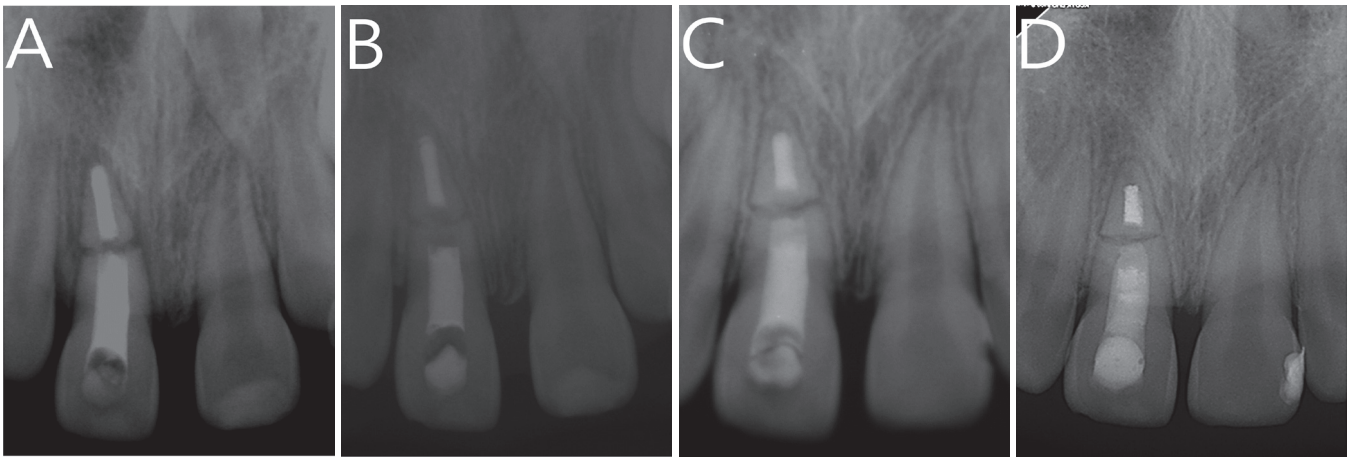


Fig. 2. Follow-up examinations. (A) Absorption of calcium hydroxide between the fragments at the 3-month follow-up. (B) Calcium hydroxide exchange at the 6-month follow-up. (C) Gutta-percha filling at the 2-year follow-up. (D) Absorption of calcium hydroxide in the apical fragment at the 4-year follow-up.

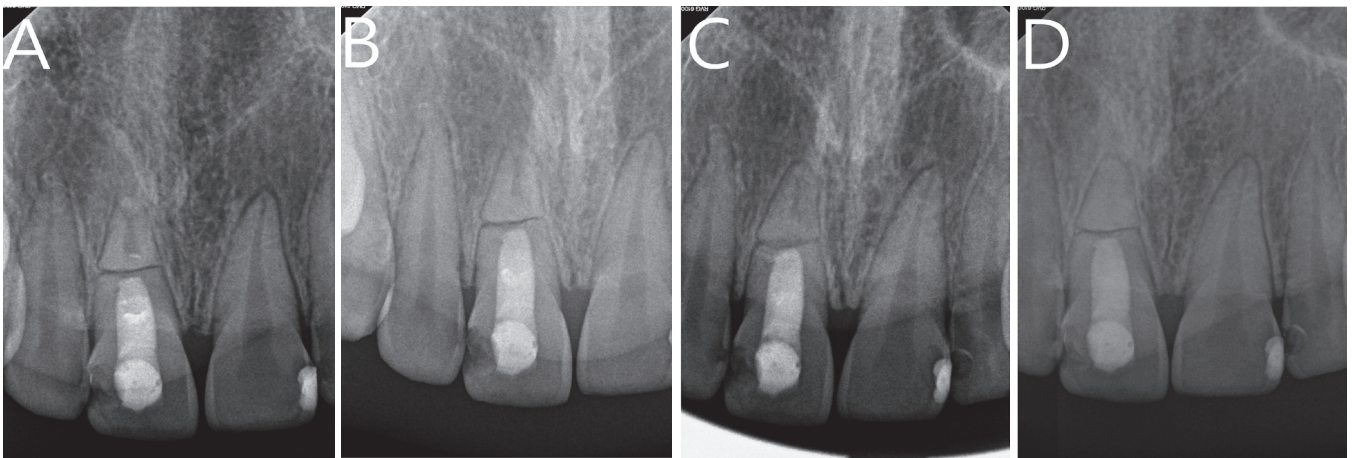


Fig. 3. Follow-up examinations. (A) Completely absorption of calcium hydroxide in the apical fragment at the 8-year follow-up. (B) 9-, (C) 10-, and (D) 11-year follow-ups.

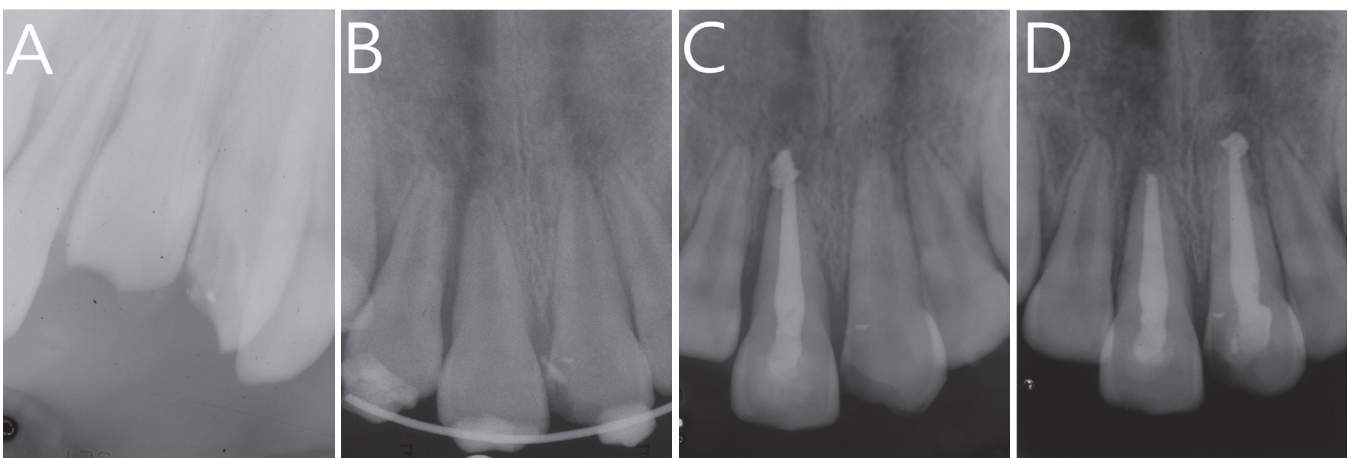

Fig. 4. Periapical radiographs of root fractures. (A) Initial periapical view. (B) Reduction and wire-splinted root-fractured tooth. (C) Pulp extirpation and calcium hydroxide canal filling were performed. (D) 2-month follow-up.

After 4 months, the patient attended the hospital due to additional trauma, and a root fracture of the right permanent central incisor was observed on a periapical radiograph (Fig. 5A). Extraction and a space maintainer were considered; however, as it was unrealistic to expect co-operation from a child with mental retardation, we planned conservative treatment.

After 6 months, calcium hydroxide between the fragments had begun to be absorbed (Fig. 5B). As in the first case, because of resistance at the fracture site and difficulty accessing the apical fragment in the root, we exchanged the calcium

hydroxide only in the coronal fragment, and monitored the apical fragment periodically.

After 3 years, calcium hydroxide on the coronal side of the apical fragment had begun to be absorbed (Fig. 6A). Remnant calcium hydroxide of apical fragment was completely absorbed after 4 years (Fig. 6B). After 5 years, the root fracture was healed with calcified and connective tissue, and the canal of the apical fragment was healed with bone tissue. The canal of the coronal fragment was filled with Gutta-percha, and there were no complications after 8 years (Fig. 6D).

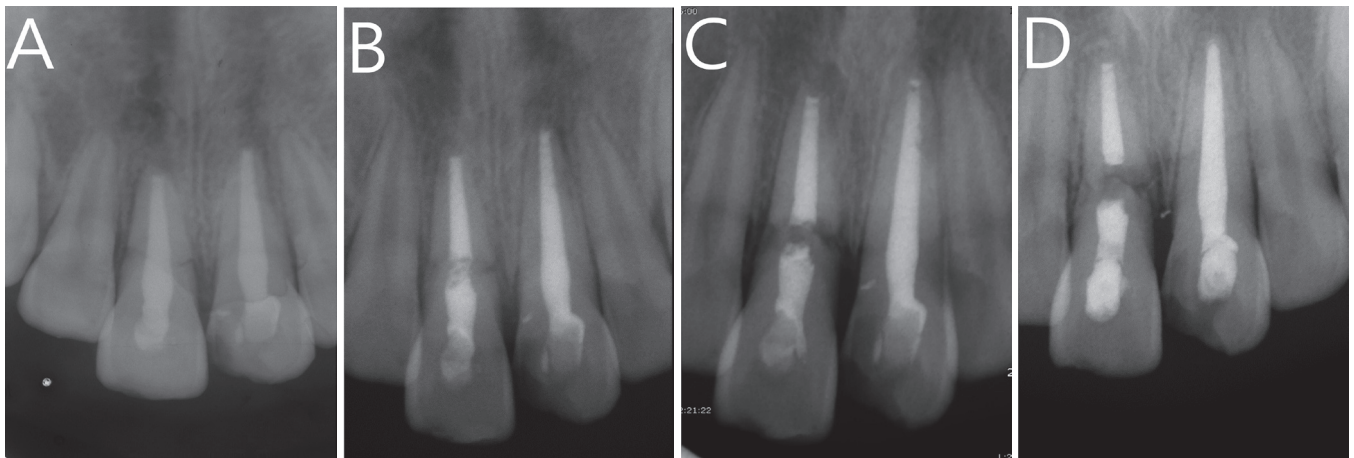


Fig. 5. Follow-up examinations. (A) Root fracture was observed after 4 months. (B) Absorption between the fragments at the 6-month follow-up. (C) 1- and (D) 2-year follow-ups.

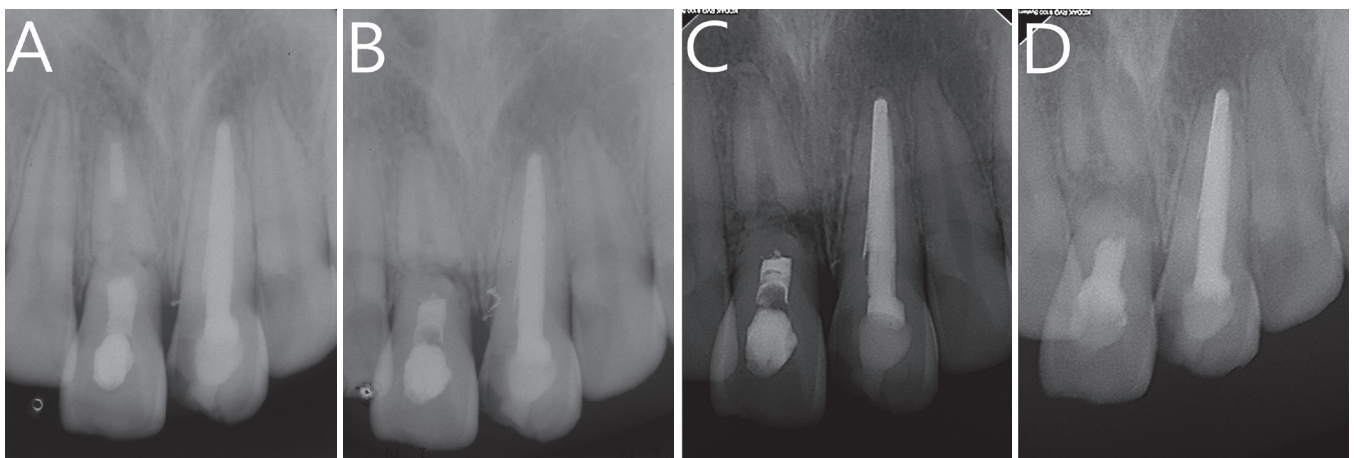


Fig. 6. Follow-up examinations. (A) Absorption of calcium hydroxide in the apical fragment at the 3-year follow-up. (B) Complete absorption of calcium hydroxide at the 4-year follow-up. (C) 5- and (D) 8-year follow-ups.

3. Case 3

An 8-year-old boy was referred from a local dental clinic at 2 weeks after splinting of a tooth with a root fracture. During the visit, root canal treatment and calcium hydroxide filling of the coronal fragment were performed. However, as a result of the excessive filing, a periapical radiograph showed the presence of excess calcium hydroxide in the canal of the apical fragment (Fig. 7B). As in the previous case, we exchanged the calcium hydroxide only in the coronal fragment and monitored the apical fragment at 3-month intervals.

After 3 months, calcium hydroxide in the coronal fragment was completely absorbed (Fig. 7C). After 6, 12, and 24 months, there were no complications or clinical symptoms (Fig. 8).

III. Discussion

Endodontic treatment for root fracture can involve treatment of the coronal fragment only, or treatment of both the apical and coronal fragments. If this is unsuccessful, it is necessary to remove the apical fragment[1]. Root canal treatment of both fragments can be performed if the entire pulp is necrotic. However, it is difficult to completely remove apical necrotic tissue and there is a risk of overfilling the space between the fragments. Therefore, the prognosis is poor. However, if the root fracture has healed and there is no space between the fragments, this type of endodontic treatment has a good prognosis[1,8].

In the present cases, endodontic treatment of the api-

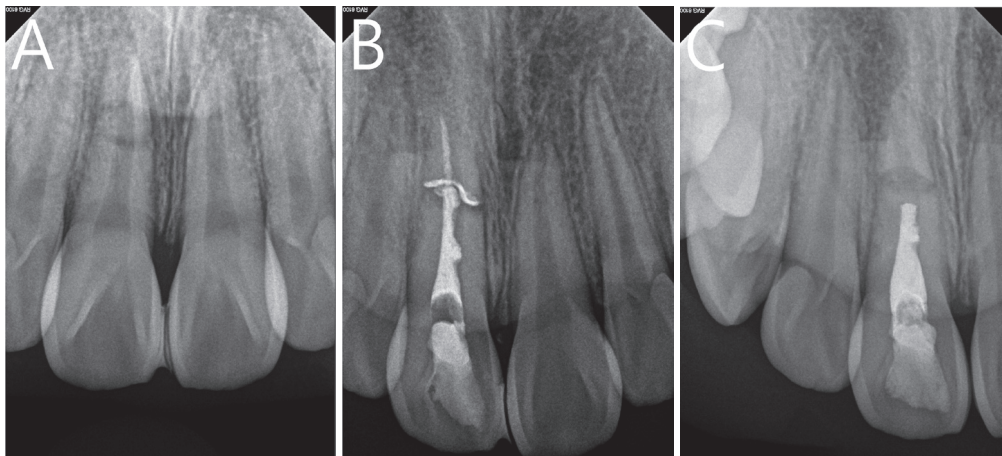


Fig. 7. Periapical radiographs of root fracture. (A) Initial periapical view. (B) Pulp extirpation and calcium hydroxide canal filling were performed. (C) Absorption of calcium hydroxide in the apical fragment at the 3-month follow-up.

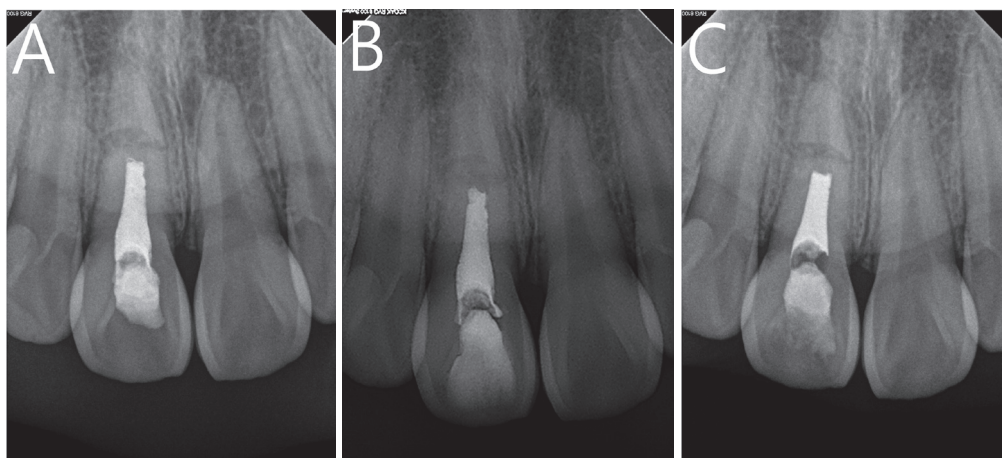


Fig. 8. Follow-up examinations. (A) 6-, (B) 12-, and (C) 24-month follow-ups.

cal fragment of root fracture was performed and the canal of the apical fragment was filled with calcium hydroxide. We exchanged the calcium hydroxide every 6 to 10 months, but resistance was felt at the fracture site and access to the root canal in the apical fragment was difficult. Therefore, the calcium hydroxide was exchanged only in the coronal fragment. In the first and second cases, after confirming the absence of complications and the formation of dentin bridges on the apical side of the coronal fragment, the root canal of the coronal fragment was filled with Gutta-percha.

Calcium hydroxide is widely used for root canal treatment of traumatized teeth[9]. Calcium hydroxide is readily absorbed, assists healing of the periapical tissues, and exerts an antimicrobial effect[10,11]. Direct contact with calcium hydroxide reportedly results in the killing of 99.9% of bacteria within a few minutes[9]. Calcium hydroxide also breaks down remnant necrotic pulp tissue, thus cleaning the root-canal walls [12,13]. This facilitates healing of the surrounding tissues and formation of a hard tissue barrier at the apical end[9].

In the first and third cases, excess calcium hydroxide was present between the fragments, but this was rapidly absorbed and dentin bridges subsequently formed. In the second case, root canal treatment was performed due to pulp necrosis of an intruded tooth, but root fracture occurred due to additional trauma. However, calcium hydroxide in the apical fragment was absorbed and dentin bridges were formed. In all cases, excess calcium hydroxide between the fragments was absorbed and formation of dentin bridges to the coronal fragment prevented infection, resulting in a good prognosis for the apical fragment.

Microleakage can occur due to multiple tunneling defects in most of the dentin bridging through calcium hydroxide[14-16]. Therefore, dentin bridges require a strong seal to prevent penetration by bacteria[1,16].

In the first case, calcium hydroxide on the apical side of the apical fragment began to be absorbed after 4 years. After 8 years, calcium hydroxide was completely absorbed and pulp canal obliteration, a sign of good recovery, was observed. In the second case, absorption of calcium hydroxide occurred on the coronal side of the apical fragment after 4 years. This absorption was likely caused by microleakage around the dentin bridges. There was no radiographic lesion because there was no bacterial penetration above the apical fragment of the root fracture. Additionally, recurrent vascularization was probably caused by the inflow of blood as the pulp canal was obliterated.

In the endodontic treatment of root fracture, because the vitality of the pulp in the apical fragment is critical, it is recommended to treat the root canal of the coronal fragment. However, endodontic treatment of the apical fragment can be performed unintentionally due to overfilling. In such cases, continued root canal treatment of the coronal fragment leads to a good prognosis.

As in this case, a good prognosis was obtained when root canal treatment of apical fragment of root fractures was treated. But accurate diagnosis and treatment of root fracture should be done. Above all, careful file manipulation and filling is considered to be important in root canal treatment of root fractures.

IV. Summary

Endodontic treatment of the apical fragment of a fractured root has a poor prognosis because of difficulty in removing necrotic tissue from the apical fragment and the risk of overfilling of the space between the fragments.

In the 3 cases in this study, the initial root canal treatment involved the apical fragment, but root canal treatment of the coronal, but not the apical, fragment was subsequently performed. As a result, no complications occurred and calcium hydroxide was absorbed, including pulp canal obliteration.

Endodontic treatment of the apical fragment of a root fracture has a good prognosis if thorough disinfection of the coronal fragment and periodic observation are performed.

References

1. Andreasen JO, Andreasen FM, Andersson L : Textbook and Color Atlas of Traumatic Injuries to the Teeth, 4th ed. Blackwell Munksgaard, Copenhagen, 337-367, 2007.
2. Andreasen JO, Ravn JJ : Epidemiology of traumatic dental injuries to primary and permanent teeth in a Danish population sample. *Int J Oral Surg*, 1:235-239, 1972.
3. Cvek M, Nord C, Hollender L : Antimicrobial effect of root canal debridement in teeth with immature root. A clinical and microbiologic study. *Odontol Revy*, 27:1-10, 1976.
4. Andreasen JO, Andreasen FM, Mejare I, Cvek M : Healing of 400 intra-alveolar root fractures. 2, Effect of treatment factors such as treatment delay, repositioning, splinting type and period and antibiotics. *Dent Traumatol*, 20:203-211, 2004.

5. Andreasen FM : Pulpal healing after luxation injuries and root fracture in the permanent dentition. *Endod Dent Traumatol*, 5:111-131, 1989.
6. Andreasen FM, Andreasen JO : Resorption and mineralization processes following root fracture of permanent incisors. *Dent Traumatol*, 4: 202-214, 1998.
7. Cvek M, Mejare I, Andreasen JO : Conservative endodontic treatment of teeth fractured in the middle or apical part of the root. *Dent Traumatol*, 20:261-269, 2004.
8. Cvek M, Andreasen JO, Borum MK : Healing and prognosis of teeth with intra-alveolar fractures involving the cervical part of the root. *Dent Traumatol*, 17:53-62, 2002.
9. Mitchell DF, Shankwalker GB : Osteogenetic potential of calcium hydroxide and other materials in soft tissue and bone wounds. *J Dent Res*, 37:1157-1163, 1958.
10. Haapasalo M, Orstavik D : In vitro infection and disinfection of dentinal tubules. *J Dent Res*, 16:207-210, 1990.
11. Hasselgren G, Olsson B, Cvek M : Effect of calcium hydroxide and sodium hypochlorite on the dissolution of necrotic porcine muscle tissue. *J Endod*, 14:125-127, 1988.
12. Orstavik D, Kerekes K, Molven O : Effects of extensive apical reaming and calcium hydroxide as a short-term intracanal dressing. *Int Endod J*, 24:1190-125, 1991.
13. Turkun M, Gengiz T : The effects of sodium hypochlorite and calcium hydroxide on tissue dissolution and root canal cleanliness. *Int Endod J*, 30:135-142, 1997.
14. Goldberg F, Massone EJ, Spielberg C : Evaluation of the dentinal bridge after pulpotomy and calcium hydroxide dressing. *J Endo*, 10:318-320, 1984.
15. Cox CF, Bergenholtz G, Heys DR, *et al.* : Pulp capping of dental pulp mechanically exposed to oral microflora: A 1-2 year observation of wound healing in the monkey. *J Oral Pathol*, 14:165-168, 1985.
16. Cox CF, Subay RK, Ostro E, Suzuki S, Suzuki SH : Tunnel defects in dentin bridges: their formation following direct pulp capping. *Oper Dent*, 21:4-11, 1996.

국문초록

미성숙 영구치의 치근파절시, 전체 근관치료 후 근단 파절편의 예후

이제식 · 남순현

경북대학교 치의학대학원 소아치과학교실

치근 파절시, 치수괴사는 주로 치관부 파절편에서만 일어나며 근단측은 생활력을 유지한다. 치근단 파절편의 근관치료는 파절편간 사이 공간의 과잉충전의 높은 가능성 및 잔여 괴사조직 제거의 어려움으로 예후가 좋지 않다.

본 증례에서는 통상적인 치료와는 다르게 치근단 파절편의 근관치료가 이루어졌다. 하지만 재근관 치료시 치근파절 부위에서 저항성과 치근단 파절편 근관으로 접근의 어려움이 있었다. 따라서 추가적인 치료 없이, 치관부 파절편만의 수산화칼슘의 교체 및 정기적인 관찰이 시행되었으며, 최종적으로 근관 충전을 시행하였다.

정기적인 관찰결과 치근단 파절편에서 방사선학적 합병증은 관찰되지 않았으며, 일부 증례에서는 장기적으로 치근단 파절편의 수산화칼슘의 흡수 및 근관 협착 등의 양호한 치유 형태를 보였기에 보고하고자 한다.