

A Study of Root Canals Morphology in Primary Molars using Computerized Tomography

Dohee Sim, Yonjoo Mah

Division of Pediatric Dentistry, Department of Dentistry, Ewha Womans University Mokdong Hospital

Abstract

The purpose of this study is to identify the most common canal type in primary molars and the correlation between their roots and canals. A comprehensive understanding of root canal morphology will lead to more successful root canal treatment.

Computed Tomography (CT) images from 114 children (81 boys, 33 girls) aged 3 - 7 years were obtained. The locations and numbers of roots and canals were evaluated, and the relationship between root and canal parameters was determined.

The most commonly observed canal morphology in primary maxillary molars were mesio-buccal, disto-buccal and palatal canal. Primary mandibular molars most frequently contain mesio-buccal, mesio-lingual, disto-buccal and disto-lingual canal. All the roots of the primary maxillary molars except for the mesio-buccal root, each had 1 canal while there were 2 canals observed in each root of primary mandibular molars. Without exception, all mesial roots in primary mandibular 2nd molars had 2 canals. In case when either the palatal root in a primary maxillary molar or the distal root in a primary mandibular molar was separated into 2 roots, each root seemed to have its own canal. Even though the disto-buccal and palatal roots were fused into 1 root in primary maxillary molars, this fused root had tendency to have 2 separate canals. Primary mandibular molars showed similar canal morphologies between left and right molars in the same patient, while the primary maxillary molars did not.

Key words : Root canal, Primary molars, Computed Tomography, Symmetry

I . Introduction

Dental caries is the most common chronic oral diseases in children[1]. Because enamel layer is thin in deciduous teeth, the dental pulp is easily involved as dental caries progress. An understanding of root canal morphology is essential in successful endodontic treatment[2,3].

It is difficult to obtain specific information about root canal configuration from periapical radiography since it only provides 2-dimensional view of 3-dimensional structure[2,4]. Several studies used some techniques such as canal staining[5] and micro computed tomography (CT) scanning of extracted teeth[6,7] to clarify the root canal morphology. These techniques have limitations such as the destruction of the tooth

Corresponding author : Yonjoo Mah

Division of Pediatric Dentistry, Department of Dentistry, Ewha Womans University Mokdong Hospital, 1071, Anyangcheon-ro, Yangcheon-gu, Seoul, 07985, Korea

Tel: +82-2-2650-2660 / Fax: +82-2-2650-5764 / E-mail: magic-lily@hanmail.net

Received July 16, 2019 / Revised October 11, 2019 / Accepted September 5, 2019

structure by the injection of staining material and small sample sizes of extracted teeth. In addition, there are not enough studies evaluating the root canal system in Korean pediatric patients.

The purpose of this study is to investigate the root canal morphology of the primary molars and to determine the symmetry in canal anatomy between left and right sides in the same patient.

II. Materials and methods

This retrospective study was conducted at the Ewha Womans University Mokdong Hospital. The Institutional Review Board (IRB) of Hospital (IRB No. : 2019-02-001) approved the study prior to its implementation.

1. Study participants

A total of 114 children (81 boys, 33 girls) aged 3 to 7 years were included in this study. Participants did not exhibit any syndromic condition that could affect bone development. Over the period from January 1, 2007 to June 31, 2018, facial CT (SOMATOM perspective, SIEMENS, Germany) was carried out on the subject to assess various parameters such as trauma, facial swelling, and a presence of supernumerary teeth. All CT images were obtained with the following specifications : dose, 110 - 150 mAs; tube voltage, 80 - 120 kV; a matrix 512 × 512; pixel size, 0.3 mm; and slice thickness, 0.1 mm. To ensure the integrity of the morphology of the root canals, the following exclusion criteria were defined : molars with periapical lesions, a history from the patient of previous pulp treatment, and root resorption exceeding 1/5 of the root length. A total of 831 teeth (208 primary maxillary 1st molars, 195 primary maxillary 2nd molars, 205 primary mandibular 1st molars, 223 primary mandibular 2nd molars) were analyzed.

2. Evaluation of the image

Each CT image was evaluated twice by 2 pediatric dentists. Within 2 weeks, the assessments were conducted once again by the same pediatric dentists. All CT images were thoroughly screened at 1.0 mm intervals using 3 plane (sagittal, axial, and coronal) slices. The locations and numbers of roots and canals were determined for each tooth.

Cohen's kappa coefficients were calculated to evaluate bi-

lateral symmetry of the primary molars between left and right sides in the same patient. Statistical analysis was performed using SPSS 22.0 software (SPSS Inc., Chicago, IL, USA).

3. The types of root canal in primary molars

There were several variants of root and canal morphology found in primary molars. The types of roots and canals were classified based on the location of roots and canal, and are shown in Fig. 1, 2, 3, and 4.

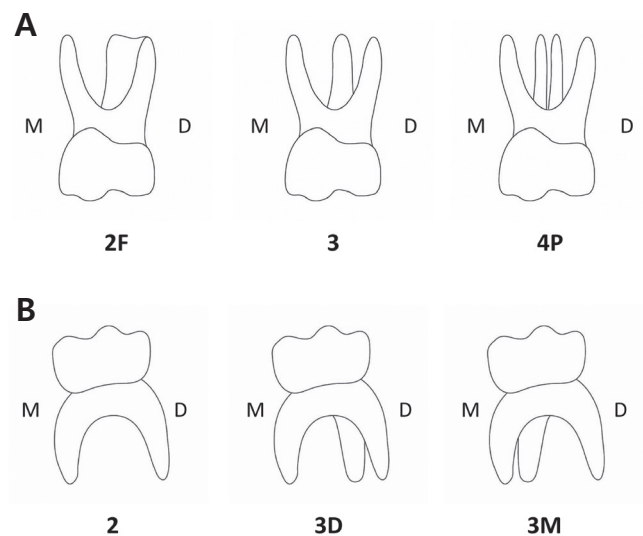


Fig. 1. The types of root in primary molars.

A. The types of root in primary maxillary molars

- Type 2F: 1 mesio-buccal root and 1 fused disto-buccal, palatal root
- Type 3: 1 mesio-buccal root, 1 disto-buccal root, and 1 palatal root
- Type 4P: 1 mesio-buccal root, 1 disto-buccal root, and 2 palatal roots

B. The types of root in primary mandibular molars.

- Type 2: 1 mesial root and 1 distal root
- Type 3D: 1 mesial root and 2 distal roots
- Type 3M: 2 mesial roots and 1 distal root

M: Mesial, D: Distal

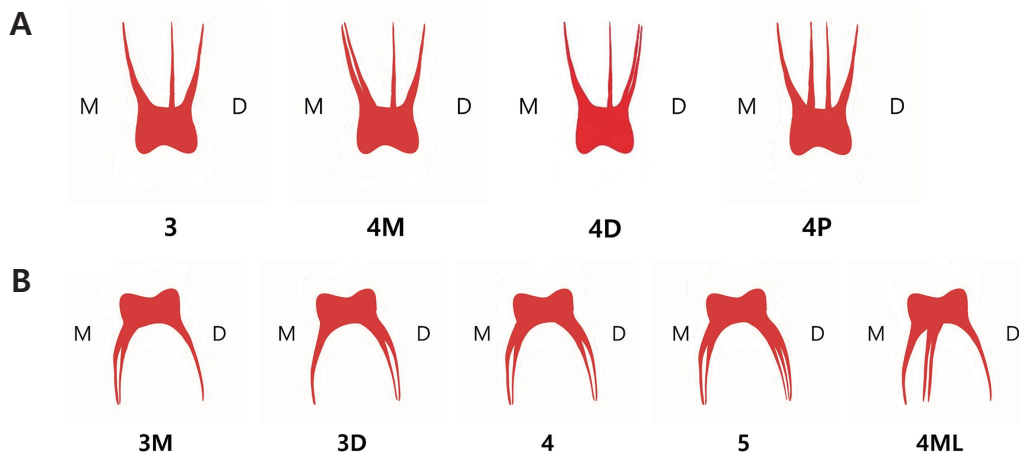


Fig. 2. The types of canal in primary molars.

A. The types of canal in primary maxillary molars

- Type 3: 1 mesio-buccal canal, 1 disto-buccal canal, and 1 palatal canal
- Type 4M: 2 mesio-buccal canals, 1 disto-buccal canal, and 1 palatal canal
- Type 4D: 1 mesio-buccal canal, 2 disto-buccal canals, and 1 palatal canal
- Type 4P: 1 mesio-buccal canal, 1 disto-buccal canal, and 2 palatal canals

B. The types of canal in primary mandibular molars.

- Type 3M: 2 mesial canals and 1 distal canal
- Type 3D: 1 mesial canal and 2 distal canals
- Type 4: 2 mesial canals and 2 distal canals
- Type 5: 2 mesial canals and 3 distal canals
- Type 4ML: 3 mesial canals and 1 distal canal

M: Mesial, D: Distal

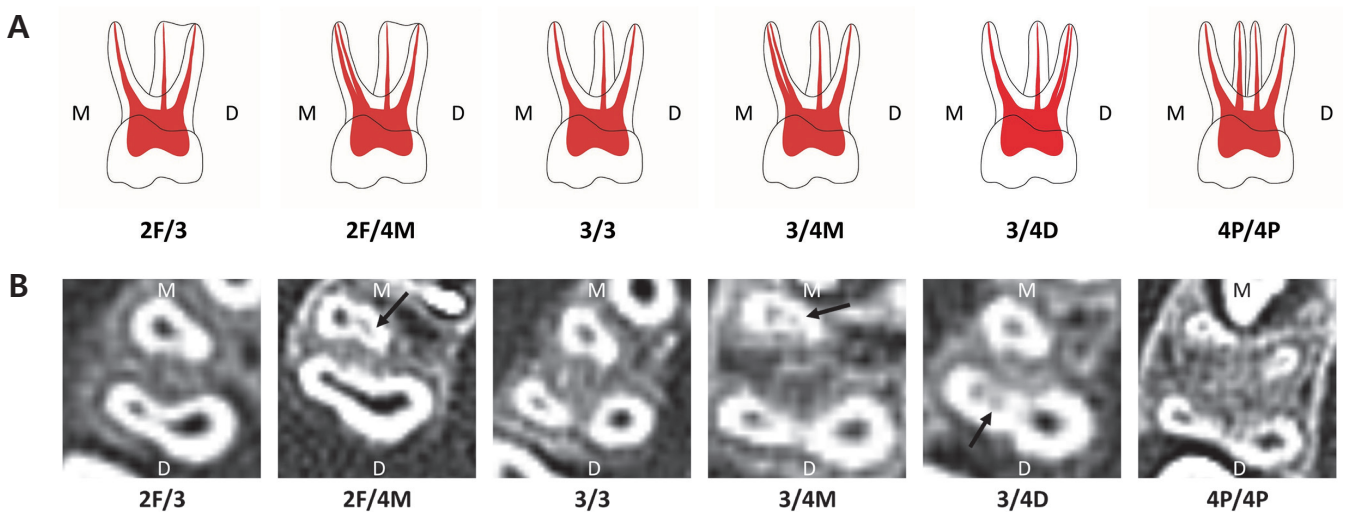


Fig. 3. The types of root-canal (root/canal) in primary maxillary molars. (A) Illustrations. (B) Computed tomography images. The black arrow indicates the canal.

- Type 2F/3 : Type 2F of root / Type 3 of canal
- Type 2F/4M : Type 2F of root / Type 4M of canal
- Type 3/3 : Type 3 of root / Type 3 of canal
- Type 3/4M : Type 3 of root / Type 4M of canal
- Type 3/4D : Type 3 of root / Type 4D of canal
- Type 4P/4P : Type 4P of root / Type 4P of canal

M = Mesial, D = Distal

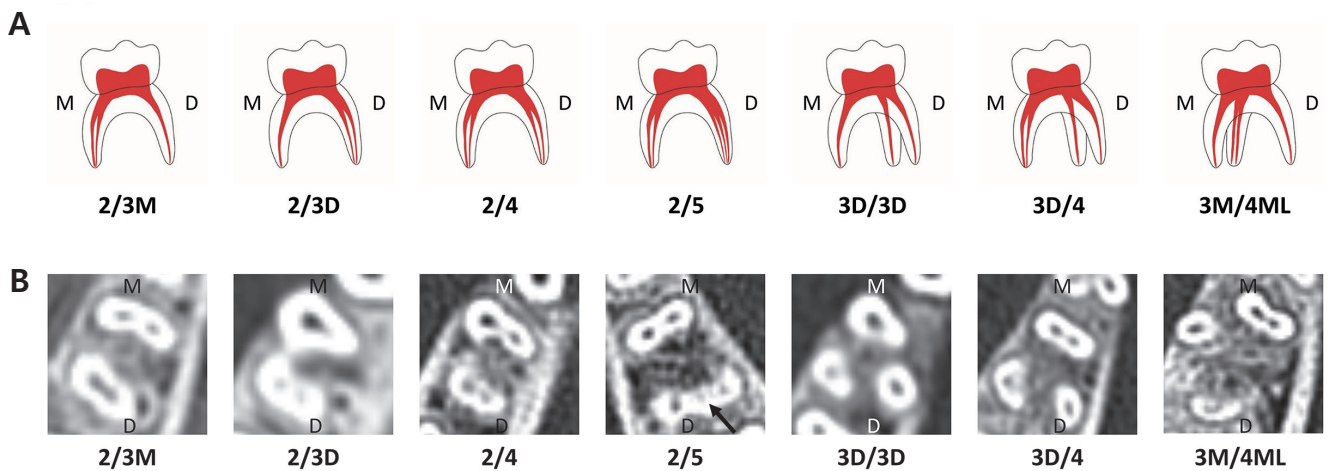


Fig. 4. The types of root-canal (root/canal) in primary mandibular molars. (A) Illustrations. (B) Computed tomography images. The black arrow indicates the canals.

- Type 2/3M: Type 2 of root / Type 3M of canal
 - Type 2/3D: Type 2 of root / Type 3D of canal
 - Type 2/4: Type 2 of root / Type 4 of canal
 - Type 2/5: Type 2 of root / Type 5 of canal
 - Type 3D/3D: Type 3D of root / Type 3D of canal
 - Type 3D/4: Type 3D of root / Type 4 of canal
 - Type 3M/4ML: Type 3M of root / Type 4ML of canal
- M = Mesial, D = Distal

III. Results

The kappa coefficients for the evaluation of intra-examiner and inter-examiner agreement were 0.910 and 0.969, respectively.

1. The types of root-canal, root, and canal in primary maxillary molars

Table 1 and 2 show the types of root and canal in primary

maxillary molars. The most common type of root-canal in primary maxillary 1st molars found in this study was type 3/3, observed in 116 molars (55.8%), followed by type 2F/3 observed in 82 molars (39.4%). The types of canals were found to be 95.2% type 3 canal and 4.3% type 4M canal. Type 4D canal was found in only 1 case.

In primary maxillary 2nd molars, root-canal type 3/3 (30.3%) was the most commonly observed type, followed by type 2F/3 (29.7%). The types of canals were found to be 60% type 3 canal, 36.9% type 4M canal, and 3.1% type 4P canal.

Table 1. Frequency of types of root and canal in primary maxillary 1st molars

Type of root	Type of canal			Total N (%)
	3	4M	4D	
2F	82 (39.4)	4 (1.9)	0	86 (41.3)
3	116 (55.8)	5 (2.4)	1 (0.5)	122 (58.7)
Total	198 (95.2)	9 (4.3)	1 (0.5)	208 (100)

Table 2. Frequency of types of root and canal in primary maxillary 2nd molars

Type of root	Type of canal			Total N (%)
	3	4P	4M	
2F	58 (29.7)	0	24 (12.3)	82 (42.0)
3	59 (30.3)	0	48 (24.6)	107 (54.9)
4P	0	6 (3.1)	0	6 (3.1)
Total	117 (60.0)	6 (3.1)	72 (36.9)	195 (100)

2. The types of root-canal, root, and canal in primary mandibular molars

Table 3 and 4 show the results of the types of root and canal in primary mandibular molars. The root-canal type 2/4 (71.2%) was most frequently found in primary mandibular 1st molars, followed by type 2/3M (12.2%) and type 2/3D (12.2%). When the study focused on the types of canal, type 4 canal (73.7%) was the most common, followed by type 3D canal (14.1%) and type 3M (12.2%).

In primary mandibular 2nd molars, type 2/4 (63.2%) was the type observed most frequently, followed by type 3D/4 (25.6%). In terms of the types of canals, type 4 canal was the most common type and type 3M (9.9%) was the second most common type. Type 4ML canal was observed in only 1 case (0.4%), whereas type 5 canal was observed in only 2 cases (0.9%).

3. The symmetry of types of canal

Tables 5, 6, 7 and 8 show the types of canal of the primary molar on the left and right sides of the same patient. The kappa coefficient values, which test the relationships between the types of canal on both sides of the primary molars, are presented in Table 9. The kappa coefficient values in primary maxillary 1st and 2nd molars were 0.373 and 0.474 respectively, whereas the coefficients in primary mandibular 1st and 2nd molars were 0.809 and 0.601 respectively.

Table 3. Frequency of types of root and canal in primary mandibular 1st molars

Type of root	Type of canal N (%)			Total N (%)
	3M	3D	4	
2	25 (12.2)	25 (12.2)	146 (71.2)	196 (95.6)
3D	0	4 (2.0)	5 (2.4)	9 (4.4)
Total	25 (12.2)	29 (14.2)	151 (73.6)	205 (100)

Table 4. Frequency of types of root and canal in primary mandibular 2nd molars

Type of root	Type of canal N (%)				Total N (%)
	3M	4	4ML	5	
2	22 (9.9)	141 (63.2)	0	2 (0.9)	165 (74)
3D	0	57 (25.6)	0	0	57 (25.6)
3M	0	0	1 (0.4)	0	1 (0.4)
Total	22 (9.9)	198 (88.8)	1 (0.4)	2 (0.9)	223 (100)

Table 5. The symmetry of types of canal in primary maxillary 1st molars

		Left N (%)		Total
		3	4M	
Right N	3	95 (97.9)	2 (2.1)	97 (100)
	4M	3 (60.0)	2 (40.0)	5 (100)
Total		98	4	102

Table 6. The symmetry of types of canal in primary maxillary 2nd molars

		Left N (%)			Total
		3	4P	4M	
Right N	3	45 (78.9)	0	12(21.1)	57 (100)
	4P	2 (50.0)	1 (25.0)	1 (25.0)	4 (100)
	4M	10 (29.4)	0	24 (70.6)	34 (100)
Total		57	1	37	95

Table 7. The symmetry of types of canal in primary mandibular 1st molars

		Left N (%)			Total
		3M	3D	4	
Right N	3M	9 (90.0)	1 (10.0)	0	10 (100)
	3D	1 (6.7)	12 (80.0)	2 (13.3)	15 (100)
	4	4 (5.3)	0	71 (94.7)	75 (100)
Total		14	13	73	100

Table 8. The symmetry of types of canal in primary mandibular 2nd molars

		Left N (%)		Total
		3M	4	
Right N	3M	8 (80.0)	2 (20.0)	10 (100)
	4	4 (4.1)	94 (95.9)	98 (100)
Total		12	96	108

Table 9. The kappa coefficient value in primary molars

	Mx. 1st	Mx. 2nd	Mn. 1st	Mn. 2nd
Kappa coefficient	0.373	0.474	0.809	0.601

Mx. 1st = Primary maxillary 1st molar
 Mx. 2nd = Primary maxillary 2nd molar
 Mn. 1st = Primary mandibular 1st molar
 Mn. 2nd = Primary mandibular 2nd molar

IV. Discussion

The purpose of this study was to investigate the root canal morphology of primary molars in pediatric patients. Dentist usually employ the periapical radiography for diagnosis and endodontic treatment. It can be a difficult task to find the exact location of the canal due to superimposition of structures in the images. It is not feasible to use CT for every pediatric patient in order to identify accurate locations of canals for endodontic treatment. Therefore, this study aimed to provide guidelines for clinical applications, by investigating the relationships between root canals of primary molars.

Each root of a primary maxillary molar tended to have 1 canal, similar the findings in previous studies[2,5,8]. 2 canals in mesio-buccal (MB) roots were observed in 4.3% of primary maxillary 1st molars and in 36.9% of 2nd molars. Joseph *et al.*[2] reported that 6.67% of primary maxillary 1st molars and 53.3% of 2nd molars had 2 canals in MB roots. A previous study on Korean pediatric patients[9] also reported that 22.8% of primary maxillary 1st molars and 66% of 2nd molars had 2 canals in MB root. These discrepancies in the results of different studies can be explained by the following reasons. First of all, the studies conducted by Joseph *et al.*[2] and Kim *et al.*[9] were carried out with extracted teeth and used small sample sizes. In addition, accessory canals were detected by Kim *et al.*[9] by observing canals directly in the cavities of extracted teeth. These different approaches seemed to be responsible for the different frequencies of 2 canals in MB roots among these studies.

The presence of 2 palatal roots was found only in maxillary 2nd molars. When there are 2 palatal roots, each root contains a canal. In other words, when 2 separated palatal roots are observed in a periapical X-ray, each root contains a canal. In 40% of primary maxillary molars, there was a fusion between the palatal and disto-buccal roots, although each root had a separate canal. This finding was consistent with those from previous studies by Wang *et al.*[7] and Bagherian *et al.*[5]. Clinicians should expect to find 2 separate canals in primary maxillary molars even when 1 fused root is observed in periapical radiographs.

In primary mandibular molars, each root seemed to have 1 or 2 canals. In the present study, 85.85% of mesial roots of primary mandibular 1st molars had 2 canals. This value was similar to the result from other previous studies, which were median values of 81.5%[5], 93.3%[2], and 100%[8]. Further-

more, each mesial root in a primary mandibular 2nd molar had 2 canals, which is consistent with the studies conducted by Joseph *et al.*[2], Bagherian *et al.*[5], Aminabadi *et al.*[8] and Gaurav *et al.*[3]. From this result, clinicians should expect a high probability of locating two canals in mesial roots of primary mandibular molars.

When only 1 distal root was observed in primary mandibular molars, 87.24% of the distal roots of the primary mandibular 1st molars contained 2 canals, and this percentage was higher than the results from studies carried out by Bagherian *et al.*[5] (22.2%), Wang *et al.*[7] (50%) and Joseph *et al.*[2] (60%). 2 canals were found in the distal roots in 84.94% of the primary mandibular 2nd molars, but this occurrence varies from 20%[7] to 100%[8] in previous studies. These varying results can be due to difference races and the different sample sizes in these studies.

2 separate distal roots were observed in 4.4% of primary mandibular 1st molars, whereas they were observed in 25.6% of primary mandibular 2nd molars. These results were consistent with those from a previous study performed in a Korean population where 2 separate distal roots were observed in 9.7% of primary mandibular 1st molars and 27.08% of primary mandibular 2nd molars[10]. According to the studies comparing the incidence rates of 2 separate distal roots among different races, 2 separate distal roots were found only in Chinese and Malassian populations, but not in European, Eurasian or Indian populations[11]. This finding indicates that 2 separate distal roots were found more often in Asian than in Caucasian populations[12,13]. This study also discovered that each separate distal root had its own canal. When 2 separated distal roots in primary mandibular molars are observed in periapical radiographs, clinicians should be able to predict that there are 2 canals in the distal roots.

With regard to the symmetry of the types of canal in primary molars on the left and right primary molars in the same patient, canal morphology was more symmetric in primary mandibular molars than in primary maxillary molars. Kappa coefficients of bilateral symmetry were 0.373 (confidence interval, CI = 0 - 0.765) and 0.474 (CI = 0.301 - 0.647) in primary 1st and 2nd maxillary molars respectively, whereas higher kappa coefficients were obtained for primary 1st and 2nd mandibular molars, 0.809 (CI = 0.686 - 0.932) and 0.601 (CI = 0.368 - 0.834) respectively. Based on Altman's suggestion[14] on coincidence levels, 1st molars and 2nd molars can be interpreted as very high and high coincidence levels respectively. On the

other hand, primary maxillary 1st molars showed fair coincidence between the left and right side of the molars, whereas the symmetry of primary maxillary 2nd molars showed moderate coincidence. A small number of reports have been published describing the symmetry of the root morphology of permanent molars[15,16], but only a few studies have been carried out on the symmetry of primary molars. Yang *et al.*[4] reported that 50.65% (39/77) of primary mandibular 2nd molars in Chinese children had symmetrical root morphology and canal morphology. In the present study on Korean children, the primary mandibular molars tended to show symmetry with regard to canal configuration. This was particularly evident in the primary mandibular 1st molars rather than in the primary mandibular 2nd molars. In accordance with the finding in this study, clinicians could readily predict the root canal morphology on the opposite side when the molars in both left and right sides needed endodontic treatment.

The limitation of this was that lower resolution facial CT was used rather than micro CT, which is used in more recent studies on root canal morphology[6,7,15]. Although it is difficult to locate small accessory canals with facial CT, the findings from our study are still valuable because of the large sample size used. Furthermore, our study observed canals that are clinically significant. More comprehensive investigations, taking root length, angulation, diameter and accessibility into account should be carried out in the future to overcome the limitations of the present study.

V. Conclusions

Based on this research, the most commonly observed canal morphology in primary maxillary molars was mesio-buccal, disto-buccal and palatal canal, whereas it was mesio-buccal, mesio-lingual, disto-buccal and disto-lingual canal in primary mandibular molars. All roots in primary maxillary molars, except for MB roots, tended to have 1 canal. The roots in primary mandibular molars tended to have 2 canals, especially the mesial root in primary mandibular 2nd molars. If either a palatal root in a primary maxillary molar or a distal root in a primary mandibular molar splits into 2 roots, there can be 1 canal for each root. Even in the fused types of disto-buccal and palatal roots of primary maxillary molars, there was 1 canal for each root as well. The symmetry of canals in primary molars was most common in primary mandibular 1st molars.

References

1. Vargas CM, Crall JJ, Schneider DA : Sociodemographic distribution of pediatric dental caries: NHANES III, 1988-1994. *J Am Dent Assoc*, 129:1229-1238, 1998.
2. Zoremchingi, Joseph T, Varma B, Mungara J : A study of root canal morphology of human primary molars using computerised tomography: an in vitro study. *J Indian Soc Pedod Prev Dent*, 23:7-12, 2005.
3. Gaurav V, Srivastava N, Rana V, Adlakha VK : A study of root canal morphology of human primary incisors and molars using cone beam computerized tomography: an in vitro study. *J Indian Soc Pedod Prev Dent*, 31:254-259, 2013.
4. Yang R, Yang C, Zou J, *et al.* : Evaluate root and canal morphology of primary mandibular second molars in Chinese individuals by using cone-beam computed tomography. *J Formos Med Assoc*, 112:390-395, 2013.
5. Bagherian A, Kalhori KA, Parisay I, *et al.* : An in vitro study of root and canal morphology of human deciduous molars in an Iranian population. *J Oral Sci*, 52:397-403, 2010.
6. Fumes AC, Sousa-Neto MD, Consolaro A, *et al.* : Root canal morphology of primary molars: a micro-computed tomography study. *Eur Arch Paediatr Dent*, 15:317-326, 2014.
7. Wang YL, Chang HH, Lin CP, *et al.* : A study on the root canal morphology of primary molars by high-resolution computed tomography. *J Dent Sci*, 8:321-327, 2013.
8. Aminabadi NA, Farahani RM, Gajan EB : Study of root canal accessibility in human primary molars. *J Oral Sci*, 50:69-74, 2008.
9. Kim CG, Hong SS, Lee SH, *et al.* : The second mesiobuccal canal of upper primary molar: case report. *J Korean Acad Pediatr Dent*, 29:139-145, 2002.
10. Song JS, Kim SO, Lee JH, *et al.* : Incidence and relationship of an additional root in the mandibular first permanent molar and primary molars. *Oral Surg Oral Med Oral Pathol Oral Radiol Endod*, 107:56-60, 2009.
11. Tratman EK : Three rooted lower molars in man and their racial distribution. *Br Dent J*, 64:264-274, 1938.
12. Winkler MP, Ahmad R : Multirooted anomalies in the primary dentition of Native Americans. *J Am Dent Assoc*, 128:1009-1011, 1997.
13. Mayhall JT : Three-rooted deciduous mandibular second molars. *J Can Dent Assoc*, 47:319-321, 1981.
14. Altman DG : Practical statistics for medical research, 1st ed.

Chapman & Hall/CRC Publishing, London, 404-409, 1990.

15. Villas-Bôas MH, Bernardineli N, Ordinola-Zapata R, *et al.* : Micro-computed tomography study of the internal anatomy of mesial root canals of mandibular molars. *J Endod*, 37:1682-1686, 2011.
16. Plotino G, Tocci L, Gambarini G, *et al.* : Symmetry of root and root canal morphology of maxillary and mandibular molars in a white population: a cone-beam computed tomography study in vivo. *J Endod*, 39:1545-1548, 2013.

국문초록

CT를 이용한 유구치 근관 형태에 관한 평가

심도희 전공의 · 마연주 교수

이화여자대학교 의과대학 목동병원 소아치과학교실

이 연구는 3세부터 7세사이의 소아를 대상으로 촬영하여 획득한 Computed tomography (CT) 영상을 이용하여 유구치 근관의 개수, 위치를 평가하고 유구치 근관들의 관계 및 치근과 근관의 관계를 분석하여 유치 근관 치료시 참고자료로 활용하고자 하였다. 남아 81명, 여아 33명, 총 114명의 CT 시상면, 수평면 영상에서 유구치 근관의 개수와 위치, 치근의 개수와 위치에 대해 평가하였고 수집된 자료를 통계분석 하여 한 환자에게서 양측에 같은 위치의 치아에 나타나는 근관의 대칭성을 평가하였다.

상악 제 1유구치와 제 2유구치에 가장 많이 관찰되었던 근관의 개수는 3개로 위치는 근심 협측, 원심 협측, 구개 근관이었다. 하악 제 1유구치 제 2유구치에 가장 많이 관찰되었던 근관의 개수는 4개로 위치는 근심 협측, 근심 설측, 원심 협측, 원심 설측 근관이었다. 상악의 치근은 근심 협측 근관을 제외하고 1개의 근관을 가지려는 경향을 가지고 있었고, 하악의 치근은 2개의 근관을 가지려는 경향을 보였다. 특히 하악 제 2유구치의 근심 치근은 100%으로 2개의 근관을 가졌다. 상악 유구치의 구개측 치근과 하악 유구치의 원심 치근이 2개의 치근으로 나누어져 있는 경우, 그 치근들은 각각 1개의 근관을 가지려는 경향을 보였다. 상악 유구치에서 원심 협측 치근과 구개측 치근이 융합되어 있더라도, 치근은 각각의 근관을 가지려는 경향을 보였다. 같은 환자의 같은 위치의 반대편 치아의 근관의 대칭성은 하악 유구치부에서 상악 유구치보다 더 높게 나타났다.

이 연구를 통해 소아 환자의 유구치 근관에 대한 이해도를 높이고, 유구치 근관 치료 시 근관의 위치에 대해 미리 예측함으로써 술식 시간을 줄이고 치료의 완성도를 높이는 데 도움이 될 것으로 사료된다.