

# Semi-Fixed Lip Bumper in Lesch-Nyhan Syndrome: An Interim Treatment Modality

Junhee Lee, Eungyung Lee, Jonghyun Shin, Shin Kim, Taesung Jeong

*Department of Pediatric Dentistry, School of Dentistry, Pusan National University*

## Abstract

Lesch-Nyhan syndrome is a rare X-linked, recessively inherited disorder of purine metabolism, caused by complete absence of the enzyme hypoxanthine-guanine phosphoribosyl transferase. This syndrome is characterized by 3 major features: neurological dysfunction, hyperuricemia, and cognitive and behavioral disturbances (e.g., self-mutilation, which begins at 2 to 3 years of age). Uncontrollable self-mutilation begins with biting of the perioral tissues and extends into patterns such as finger biting and head hitting. This report describes the case of a 31-month-old boy who was diagnosed with Lesch-Nyhan syndrome with severe lip injuries caused by self-mutilative behaviors. The behaviors were blocked with a semi-fixed lip bumper for a short period. The device was applied to the patient on the day of the visit without the requirement for an oral impression. It was easy to manage oral hygiene and adjust the device because it was detachable by clinicians and guardians. Therefore, a semi-fixed lip bumper may be useful as an interim appliance to block self-mutilative behaviors in children with Lesch-Nyhan syndrome.

**Key words :** Lesch-Nyhan syndrome, Self-mutilation, Lip bumper, Oral hygiene

## I. Introduction

Lesch-Nyhan syndrome is a chronic, progressive neurodevelopmental disorder characterized by hyperuricemia, intellectual disability, motor disorders, and compulsive self-mutilative behaviors. This metabolic disorder is associated with increased synthesis of uric acid, due to various forms of mutations that inhibit the synthesis of hypoxanthine-guanine phosphoribosyl transferase, an enzyme involved in purine metabolism[1,2]. Generally, hyperuricemia can be controlled by treatment with allopurinol or uric oxidase, however neurological symptoms progress and eventually lead to disabilities such as sclerosis, chorea, and self-harm[3,4]. The self-mutilative and aggressive

behaviors typically begin at 2 - 3 years of age. These behaviors begin with biting of the lips or buccal mucosa, and extend into patterns such as finger bites and head hitting[5]. Perioral tissues are rapidly and perniciously destroyed, which results in a risk of infection; therefore, immediate treatment is required.

From a dental perspective, several preventive approaches such as mouth guards, bite blocks, and acrylic appliances and helmets, as well as invasive treatments have been used to prevent self-mutilative behaviors. However, intraoral impressions must be taken for most devices, and they cannot be applied on the day of the visit[6-10]. Although a semi-fixed lip bumper can supplement these limitations, few case reports using semi-fixed lip bumper were reported. In this case, a semi-

*Corresponding author : Taesung Jeong*

*Department of Pediatric Dentistry and Institute of Transitional Dental Sciences, School of Dentistry, Pusan, National University & Dental Research Institute of Pusan National University Dental Hospital, Yangsan 50612, Republic of Korea*

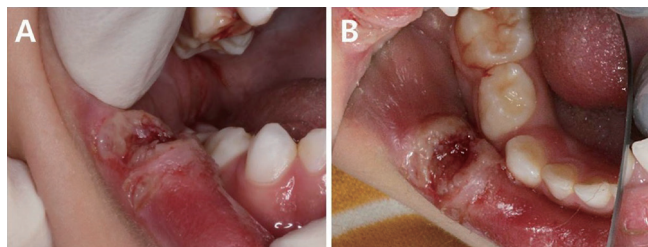
*Tel: +82-55-360-5181 / Fax: +82-55-360-5174 / E-mail: tsjeong@pusan.ac.kr*

*Received September 16, 2019 / Revised November 5, 2019 / Accepted November 4, 2019*

fixed lip bumper was applied to a 31-month-old boy who was diagnosed with Lesch-Nyhan syndrome. Impressions were not taken prior to application of this device, and it could be applied immediately. The device facilitated easy management of oral hygiene and adaptation to changing habits, because it could be removed and assembled by clinicians and guardians. After 2 months, perioral tissue injuries recovered without additional damage and the continuity of the lip line was maintained, which constituted favorable outcomes. The patient has resumed normal daily life, as noted in the following case report.

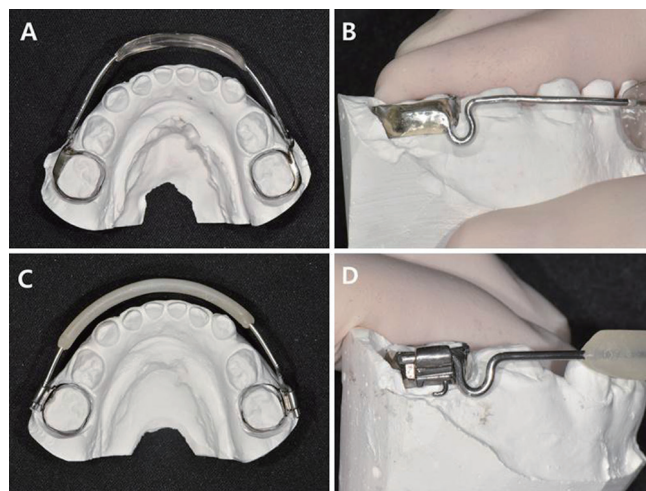
## II. Case Report

A 31-month-old boy was brought to the Department of Pediatric Dentistry at Pusan National University Dental Hospital with a chief complaint of lower lip injuries due to self-mutilative behaviors. The patient was diagnosed with Lesch-Nyhan by HPRT1 c (p.Gly 190Ala) hemizygote mutation and brain lesion grade 1. The patient had symptoms of developmental delay, mental retardation, gait disturbance, and spasticity due to systemic disorder. A pharmacotherapy and rehabilitation for systemic treatment were conducted at the pediatric neurology clinic. Allopurinol 100 mg was used as a qid to control hyperuricemia, and antipsychotics such as haloperidol, aripiprazole and risperidone were selectively used in combination with muscle relaxants such as baclofen and diazepam. In oral finding, generalized attrition and white lesion were observed. Approximately 2.0 cm of laceration in the right lower lip, caused by self-mutilative behaviors, was observed. The perioral tissue had been damaged at a very rapid rate for a few days and immediate prevention was required (Fig. 1). A fixed-type lip bumper was planned for prevention of biting habits and



**Fig. 1.** Clinical photograph at the 1st visit. Right lower lip injuries of approximately 2.0 cm were observed (A, B).

a lower dental arch impression was taken after orthodontic bands were adapted to the mandibular 2nd primary molar. It was difficult to take an accurate impression and the fingers of a clinician were injured during the procedures due to the patient's involuntary biting habit. After 1 week, a fixed-type lip bumper was applied to the patient; it was difficult to isolate saliva and apply to the mouth as a single-unit device using a mouth gag (Fig. 2A, 2B). During the 3 weeks after the fixed lip bumper was applied, the orthodontic band was detached from the teeth 4 times, potentially due to failure of saliva isolation and accurate impression taking. The fixed lip bumper was replaced with a semi-fixed type lip bumper. A lip bumper tube (MBT 022" lip bumper tube, 3M Unitek, St. Paul, MN, USA) was welded to the orthodontic band that was adapted for the size of the mandibular 2nd primary molar. It was applied to the tooth with a mouth gag and isolation of the saliva using resin cement (Maxcem Elite, Kerr™, Los Angeles, CA, USA). A ready-made lip bumper bow (Lip bumper, Tomy®, Tokyo, Japan) was adjusted at a distance of approximately 5.0 mm from the mandibular incisor and assembled to the tube (Fig. 2C, 2D, 3A). The end of the cut lip bumper bow is rounded. All procedures were performed on the day of the visit without impression taking. After the semi-fixed type lip bumper was applied



**Fig. 2.** Comparison of fixed and semi-fixed lip bumpers. The dental cast of semi-fixed lip bumper was duplicated. (A) Occlusal view of fixed-type lip bumper. (B) Lip bumper bow and orthodontic band were soldered together. (C) Occlusal view of semi-fixed lip bumper. (D) Lip bumper bow was inserted into lip bumper tube for device connection.

to the mandible, the lower lip biting habit was blocked. After 1 month, the patient began biting his upper lip. The same device was applied to the maxilla (Fig. 3B). After 6 weeks, the buccal mucosa was injured by unnecessary structures of the bracket, including a hook; these structures were removed to minimize stimulation of the buccal mucosa (Fig. 4). Injuries to the buccal mucosa were remarkably reduced, and the upper and lower lips recovered. After 2 months, injuries to the perioral tissue recovered and the continuity of the lip line was maintained (Fig. 3C). After 11 months, no additional trauma

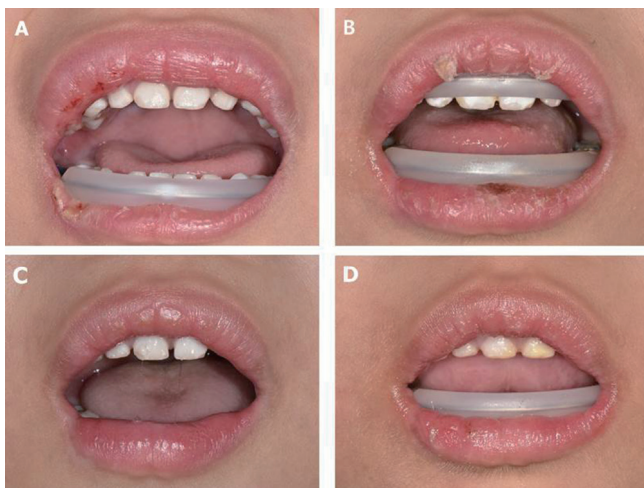
or worsening of self-mutilative behaviors were found (Fig. 3D). The patient is currently undergoing observation at 1-month intervals. Adjustments of the lip bumper have been performed at each check-up. Fluoride varnish is applied at 2-month intervals to prevent dental caries. In the future, systemic care of the patient through cooperation with pediatrics will be needed. Managing oral hygiene should be maintained and replacement with other devices will be considered with worsening of self-mutilative behaviors.

### III. Discussion

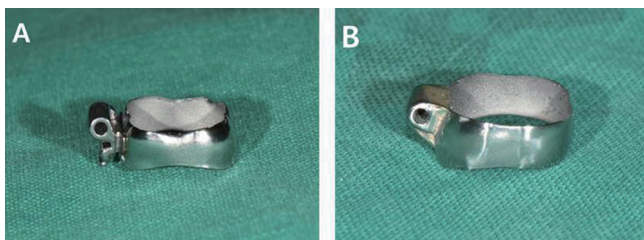
The patients with Lesch-Nyhan syndrome should be treated with medical approaches to control the concentration of uric acid and the self-injurious behaviors should be blocked simultaneously. When treating the patients, several considerations such as a high probability of aspiration pneumonia should be considered. And the clinicians should be evaluate whether the drug to use affects acute renal failure or HPRT activity[11].

Self-mutilative behaviors are typically observed at 2 - 3 years of age in patients with Lesch-Nyhan syndrome, and can easily be detected by clinicians and guardians. When these habits develop, severe injuries to the perioral tissues are caused in a short period. Immediate prevention of self-mutilative behaviors is indispensable. Several preventive approaches have been reported, such as bite raising oral appliances, mouth guards, fixed lip bumpers, and helmets, as well as invasive treatments (e.g., extraction of teeth and/or orthognathic surgery, coronal resection following vital pulpectomy)[5-7,12-16]. However, partial success has been achieved with some limitations using these methods. Invasive treatments are difficult to select as 1st treatment options[6]. Besides, interference with alveolar bone growth may occur when teeth are extracted at an early age[16]. There are also limitations in preventive approaches. Impression-taking procedures, which are required for the fabrication of nearly all oral appliances, are difficult to perform in patients with Lesch-Nyhan syndrome, due to involuntary biting. Although self-mutilative behaviors should be stopped as soon as possible, it is difficult to apply oral appliances to such patients at the 1st visit. Difficulties in oral hygiene management and constraint of action and masticatory function are also problems encountered by these patients.

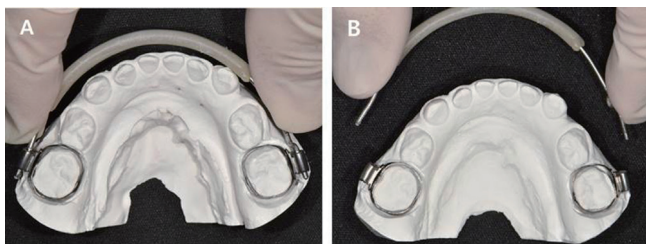
In some previous cases using lip bumpers, fixed-type devices were applied, which revealed several limitations of fixed devices. In the present case, a semi-fixed lip bumper was



**Fig. 3.** (A) After the semi-fixed lip bumper was applied to the mandible, incomplete healing was observed on the right lower lip. (B) After 6 weeks, a semi-fixed lip bumper was applied to the maxilla because the patient began biting the upper lip. (C) After 2 months, the upper and lower lips were completely recovered. The continuity of the lip line was maintained. (D) After 11 months, the recovery is maintained favorably.



**Fig. 4.** Orthodontic tube and bracket before (A) and after simplification (B).



**Fig. 5.** The semi-fixed lip bumper can be inserted and removed by clinicians or guardians.

used to overcome these limitations. Compared to the fixed-type design, the semi-fixed lip bumper bow can be inserted and removed by clinicians or guardians (Fig. 5). Adaptation of the device can easily be performed, based on variation in self-mutilative behaviors, and oral hygiene can easily be managed.

In patients with Lesch-Nyhan syndrome, perioral tissues can be severely damaged in a short period of time. Prompt prevention of self-mutilative behaviors should be conducted. The semi-fixed lip bumper in this case consisted of a ready-made lip bumper bow, as well as orthodontic bands that were welded to the lip bumper tubes. This bumper can be constructed without the requirement for impressions and can be applied to patients at the 1st visit. It can also be used with other appliances as a combined treatment, as it can be removed when necessary. Intraoral appliances in patients with Lesch-Nyhan syndrome should be designed with appropriate considerations for the patients' daily lives. When patients perform activities that involve a risk of orofacial trauma, such as outdoor activities or rehabilitation, the devices can be removed and a soft device can be applied (i.e., a mouthguard).

Although there are several advantages in using a semi-fixed lip bumper, the orthodontic effect caused by the device is uncertain when it is used for an extended period of time. It is unclear whether a semi-fixed lip bumper can be maintained under the lip force present in adolescent patient with Lesch-Nyhan syndrome. Also, the self-mutilative behaviors that involve biting the tongue or buccal mucosa cannot be blocked by this device.

When treating patients with Lesch-Nyhan syndrome, clinicians are recommended to postpone invasive treatments as much as possible and to promote patients' oral health through conservative approaches. In this case, self-mutilative behaviors were prevented with a semi-fixed lip bumper and the results

were favorable. Several advantages can be obtained using a semi-fixed lip bumper, compared to a fixed-type lip bumper. In the future, the method for blocking self-mutilative behaviors should be improved for use in patients with Lesch-Nyhan syndrome, and new approaches that can be used for extended periods of time are needed.

#### IV. Summary

In this case, a semi-fixed lip bumper was used to prevent self-mutilative behaviors in a child with Lesch-Nyhan syndrome, which yielded favorable results. The self-mutilative behaviors proceeded rapidly and destructively, such that immediate resolution was required. A semi-fixed lip bumper was developed that can be applied to patients on the day of the visit, without the requirement for intraoral impressions. This approach is advantageous for management of oral hygiene and adjustment of the device; it can also be used as a combined treatment with other devices. Therefore, a semi-fixed lip bumper may be useful as an interim approach for prevention of self-mutilative behaviors in patients with Lesch-Nyhan syndrome.

#### ORCID

Junhee Lee <https://orcid.org/0000-0002-7243-6722>

Eungyung Lee <https://orcid.org/0000-0001-8313-8571>

Jonghyun Shin <https://orcid.org/0000-0002-9777-0196>

Shin Kim <https://orcid.org/0000-0002-7202-7726>

Taesung Jeong <https://orcid.org/0000-0002-0431-5574>

#### References

1. Harris JC : Lesch-Nyhan syndrome and its variants: examining the behavioral and neurocognitive phenotype. *Curr Opin Psychiatry*, 31:96-102, 2018.
2. Mak BS, Chi CS, Lin HY, *et al.* : New mutations of the HPRT gene in Lesch-Nyhan syndrome. *Pediatr Neurol*, 23:332-335, 2000.
3. Jeong TS, Lee JH, Tootla RG, *et al.* : A preventive approach to oral self-mutilation in Lesch-Nyhan syndrome: a case report. *Pediatr Dent*, 28:341-344, 2006.
4. Kállay K, Liptai Z, Kriván G, *et al.* : Successful unrelated umbilical cord blood transplantation in Lesch-Nyhan syndrome. *Metab Brain Dis*, 27:193-196, 2012.

5. Fardi K, Topouzelis N, Kotsanos N : Lesch-Nyhan syndrome: a preventive approach to self-mutilation. *Int J Paediatr Dent*, 13:51-56, 2003.
6. Davila JM, Aslani MB, Wentworth E : Oral appliance attached to a bubble helmet for prevention of self-inflicted injury. *ASDC J Dent Child*, 63:131-134, 1996.
7. Evans J, Sirikumara M, Gregory M : Lesch-Nyhan syndrome and the lower lip guard. *Oral Surg Oral Med Oral Pathol*, 76:437-440, 1993.
8. Chen LR, Liu JF : Successful treatment of self-inflicted oral mutilation using an acrylic splint retained by a head gear. *Pediatr Dent*, 18:408-410, 1996.
9. Saemundsson SR, Roberts MW : Oral self-injurious behavior in the developmentally disabled: review and a case. *ASDC J Dent Child*, 64:205-209, 1997.
10. Sugahara T, Mishima K, Mori Y : Lesch-Nyhan syndrome: successful prevention of lower lip ulceration caused by self-mutilation by use of mouth guard. *Int J Oral Maxillofac Surg*, 23:37-38, 1994.
11. Jun IG, Chin JH, Hwang JH, *et al.* : Anesthetic experience of percutaneous nephrolithotomy for renal calculi in a patient with Lesch-Nyhan syndrome: a case report. *Korean J Anesthesiol*, 53:520-523, 2007.
12. Lesch M, Nyhan WL : A familial disorder of uric acid metabolism and central nervous system function. *Am J Med*, 36:561-570, 1964.
13. Mahmood A, Dubey P, Moser HW, Moser A : X-linked adrenoleukodystrophy: therapeutic approaches to distinct phenotypes. *Pediatr Transplant*, 9:55-62, 2005.
14. Dicks JL : Lesch-Nyhan syndrome: a treatment planning dilemma. *Pediatr Dent*, 4:127-130, 1982.
15. Lee JH, Berkowitz RJ, Choi BJ : Oral self-mutilation in the Lesch-Nyhan syndrome. *ASDC J Dent Child*, 69:66-69, 2002.
16. Benz CM, Reeka-Bartschmid AM, Agostini FG : Case report: the Lesch-Nyhan syndrome. *Eur J Paediatr Dent*, 5:110-114, 2004.

국문초록

## 반 고정식 립 범퍼를 이용한 Lesch-Nyhan 증후군 환자의 자해습관 차단

이준희 대학원생 · 이은경 대학원생 · 신중현 교수 · 김신 교수 · 정태성 교수

*부산대학교 치의학전문대학원 소아치과학교실*

Lesch-Nyhan 증후군은 hypoxanthine-guanine phosphoribosyl transferase 결핍으로 인해 발생한 purine 대사 장애의 열성 유전 질환이다. 이 증후군은 신경 장애, 행동 장애 및 과요산혈증(hyperuricemia) 등의 증상이 나타난다. 특징적으로 자해 습관은 2 - 3세경 시작되는데, 구강 주위 조직이나 손, 발을 물어 뜯는 양상이 나타난다. 이 증례는 2세 7개월의 Lesch-Nyhan 증후군 환자의 자해습관을 반 고정식 립 범퍼를 이용하여 차단한 증례를 보고하는 바이다. 반 고정식 립 범퍼는 전통적인 인상채득 방식을 필요로 하지 않고 내원 당일 치료해 줄 수 있는 장점이 있으며, 보호자에 의해 탈, 부착이 가능하여 환자의 구강위생 관리에 용이하였다. 장치 장착 2 개월 후, 치아 주위 조직이 회복되고 연속성이 유지되는 양호한 결과를 보였다. 장치 장착 11개월 후, 양호한 회복양상이 유지되었으며 추가적인 외상이나 자해행동의 악화는 관찰되지 않았다. 따라서, semi-fixed lip bumper는 Lesch-Nyhan syndrome 환자의 자해습관을 차단하기 위한 interim appliance로 사용하는데 유용할 것으로 사료된다.