

# Dental Management in a Patient with Glanzmann's Thrombasthenia : A Case Report

Miran Han<sup>1</sup>, Jongsoo Kim<sup>2</sup>

<sup>1</sup>*Department of Pediatric Dentistry, Jukjeon Dental Hospital, Dankook University*

<sup>2</sup>*Department of Pediatric Dentistry, College of Dentistry, Dankook University*

## Abstract

Glanzmann's thrombasthenia (GT) is a rare, autosomal recessive inherited congenital disorder, characterized by impaired blood coagulation due to platelet dysfunction. It was first reported by the pediatrician Glanzmann in 1918.

GT affects both males and females, and it is more common in regions of the Middle East, India, and France, where intermarriage is common. It has an incidence of about 1 in 1,000,000 people. In South Korea, according to the Division of Rare Diseases, Korea Centers for Disease Control and Prevention, around 200 cases have been reported in 2018.

Clinical symptoms include petechia, ecchymosis, epistaxis, and gingival bleeding. The spontaneous loss of deciduous teeth can result in excessive bleeding with that blood transfusion should be considered. Preventing hemorrhages and hemostasis are most important factors in dental treatment. Local bleeding can be controlled by compression, but platelet transfusion can be required by prolonged bleeding.

Pediatric dentists can minimize the gingival bleeding by control of the oral hygiene to prevent gingivitis and dental caries. The importance of oral hygiene and periodic recall check-up should be emphasized. During dental treatment, the examination and the treatment plan of patient should be modified to prevention of hemorrhages carefully.

A 6-year-old girl with GT was referred for the treatment of dental caries, and resin restoration was performed under nitrous oxide inhalation sedation. After treatment, compression was required for the bleeding control.

**Key words :** Glanzmann thrombasthenia, Bleeding control, Dental management

## I . Introduction

Glanzmann's thrombasthenia (GT) is a rare, autosomal recessive inherited bleeding disorder due to platelet dysfunction[1]. It was first described by the pediatrician Eduard Glanzmann in 1918, and it is called Glanzmann's disease also. It is a congenital bleeding disorder with normal platelet count and morphology, but impaired platelet function. The abnormal formation of glycoprotein (GP) IIb/IIIa impairs the platelet function, which is

essential for blood coagulation, resulting in improper hemostasis[2,3].

The main clinical manifestation of GT is hemorrhage and difficult-to-control bleeding[4]. The prolonged bleeding time, mild to moderate bleeding tendency, and poor aggregation of platelets are observed in common. The bleeding tendency was variable. Patients typically experience mucocutaneous bleeding during the neonatal period and infancy, bruising and nose bleeding in childhood, and excessive menstrual bleeding

Corresponding author : Jongsoo Kim

Department of Pediatric Dentistry, School of Dentistry, Dankook University, 119, Dandae-ro, Dongnam-gu, Cheonan, 31116, Republic of Korea

Tel: +82-41-550-0223 / Fax: +82-41-551-1935 / E-mail: jskim@dku.edu

Received June 17, 2020 / Revised July 1, 2020 / Accepted July 1, 2020

www.kci.go.kr

in adolescence. Trauma, surgery, and dental treatment could cause to prolonged bleeding tendency. Excessive bleeding is expected during delivery.

Children are often diagnosed before the age of 5 years by unexpected spontaneous mucocutaneous bleeding. Excessive bleeding after deciduous tooth extraction is often the first sign of GT[5].

The purpose of this case report was to present the clinical findings and dental considerations while treating pediatric GT patients.

## II. Case Report

A 6-year-old girl was referred from a pediatric dentist to the dental hospital for the treatment of dental caries.

The information was obtained from parents. When the patient was 1 month old, a bruise was observed on the cheek and bruises spread out to the elbow at 2 months later. The pa-

tient diagnosed with GT from various tests. The patient would bruise easily on the skin, and often experienced oral bleeding and gingival bruising after toothbrushing.

From the medical consult, the patient was having outpatient follow-up visits and no prescription for GT. No pre-medication for dental treatment was required. Blood transfusion would be needed during dental treatment due to excessive bleeding.

At the first examination, multiple bruises were seen on the arms and legs (Fig. 1). Several teeth with caries were observed and bruising was shown on the buccal gingiva of the right maxillary deciduous lateral incisor to molar area, and the labial gingiva of the mandibular anterior area (Fig. 2). On the radiographic examination, interproximal dental caries of the right deciduous maxillary molars and the both right and left deciduous mandibular molars were observed (Fig. 3).

The patient was afraid of treatment due to frequent examinations and hospital visits, and the behavior pattern was Frankl rating scale 1. Treatment plan to restore dental caries

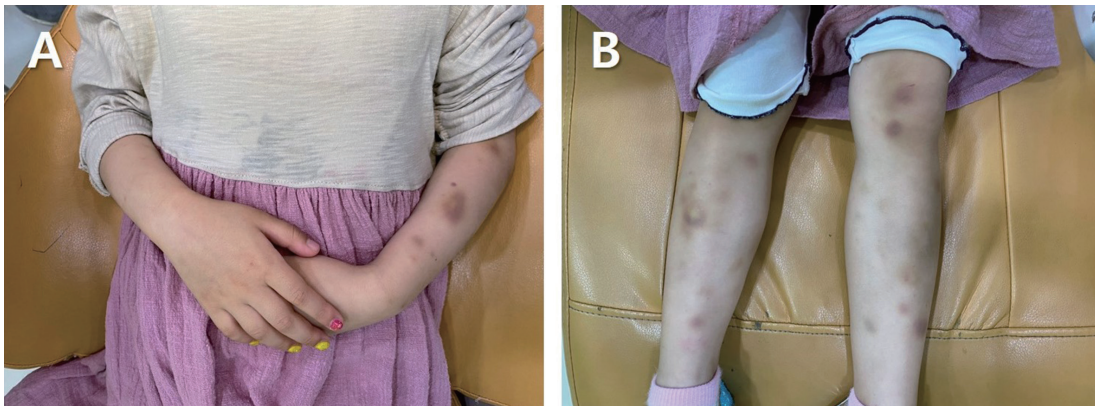
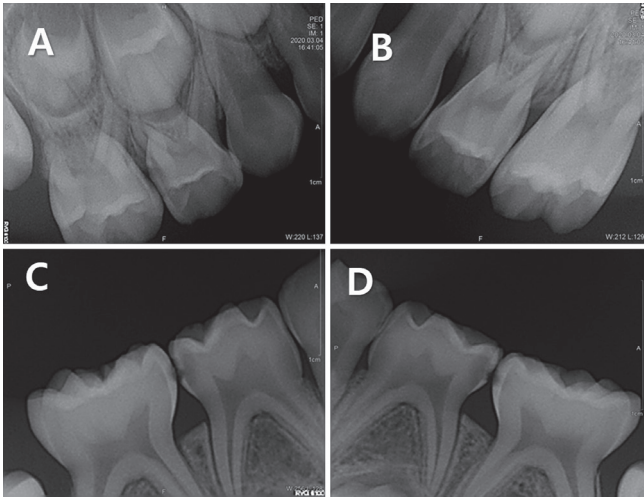


Fig. 1. Physical examination. Multiple bruises were seen on the arms and the legs.

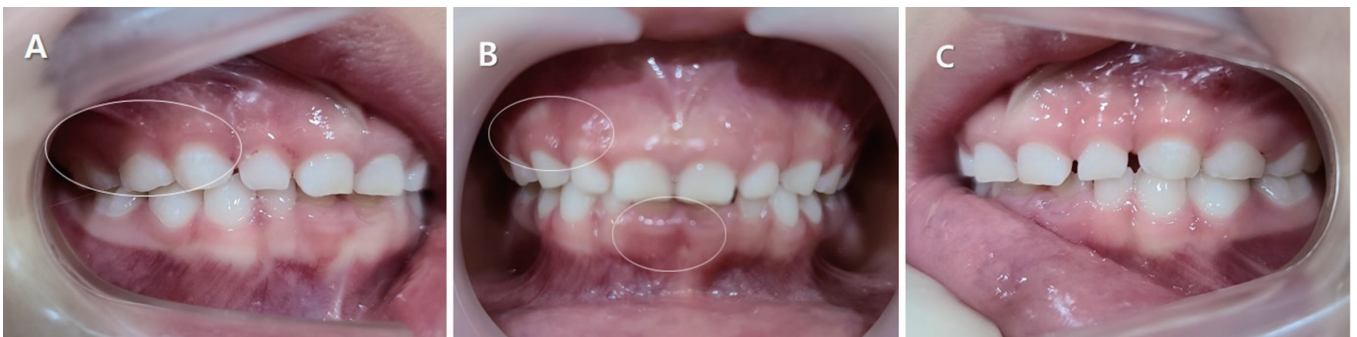

Fig. 2. Intraoral photographs at the first examination. (A, B) Bruising of gingiva in the right maxillary area and the mandibular anterior area.



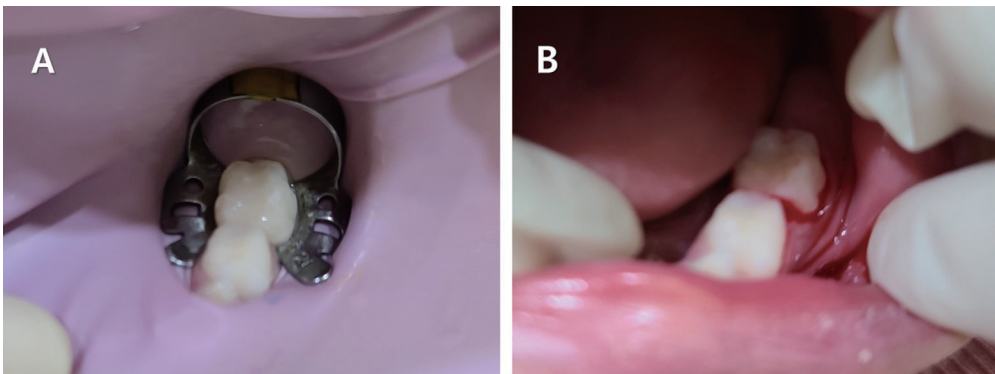
**Fig. 3.** Oral radiographs at the first examination. (A, C, D) Dental caries on the proximal surfaces of the deciduous molars.

with composite resin under nitrous oxide inhalation sedation has been established. Considering the gingival bleeding, the treatment was divided into three visits to treat one quadrant each time. For the excessive bleeding, platelet transfusion was arranged with the pediatrician.

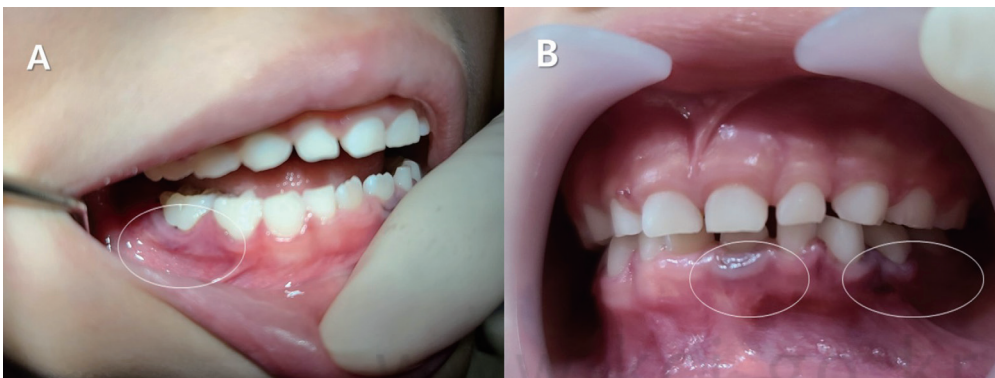The patient was treated under nitrous oxide inhalation sedation. A rubber dam was used while treating the proximal surfaces of the left deciduous mandibular molars, and resin restorations were performed as usual. After treatment, there were gingival bleedings where the rubber dam clamp and wedge were placed. Even though compressed the bleeding spot with gauze for 30 minutes, the blood was oozing from the gingiva (Fig. 4). The bleeding seemed not too severe, the patient was discharged with the parental consent, and instructed to call back if the bleeding persisted. The parents informed by phone that blood was oozing for 4 hours after returning home.

At the second visit for treatment, there was bruising on the labial gingiva of the left mandibular central incisor, buccal gingiva of the left deciduous mandibular canine to second molar area, and buccal gingiva of the right mandibular second molar (Fig. 5). Resin restorations of the proximal surfaces of the right mandibular molars were performed, and the bleeding was lesser than the first treatment (Fig. 6). The patient was discharged after compression for hemostasis.

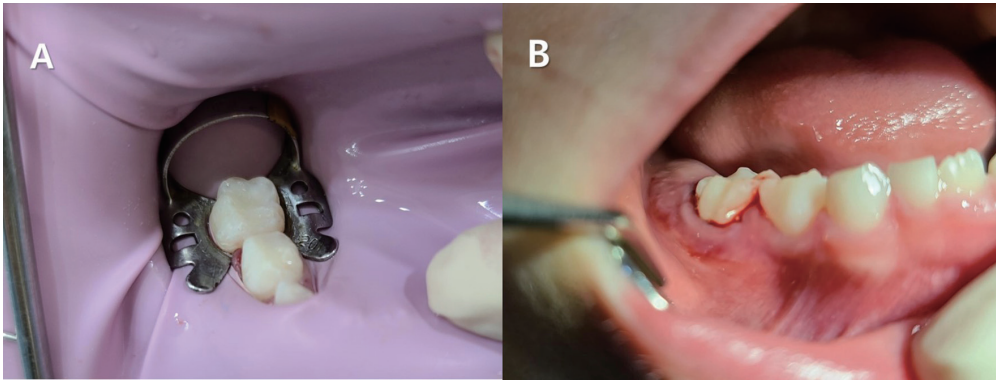
At the third visit for treatment, there were no specific findings in the oral cavity. Resin restorations were performed on the proximal surfaces of the right deciduous maxillary molars,



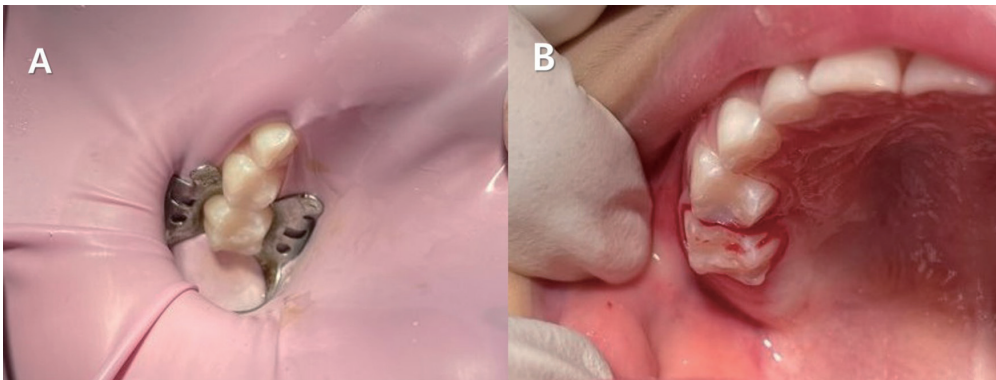
**Fig. 4.** Resin restorations of the left deciduous mandibular molars. (B) Gingival bleeding was seen after removal of the rubber dam.



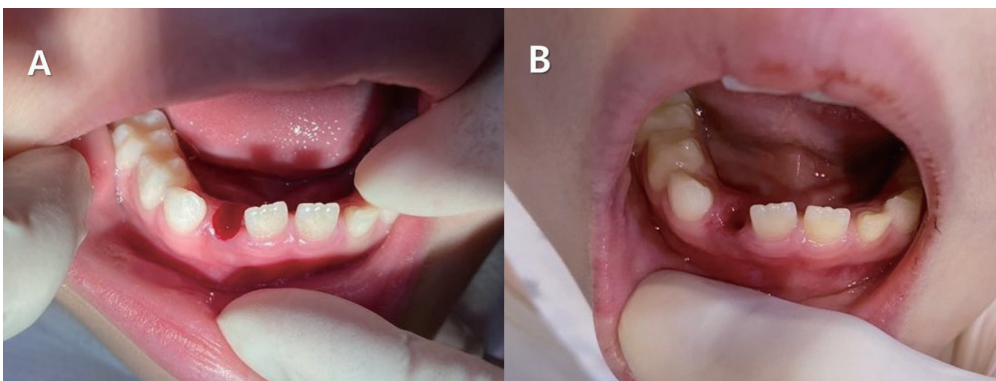
**Fig. 5.** Intraoral photographs at the second visit for treatment. Bruising of gingiva in the mandibular incisal and molar area.



**Fig. 6.** Resin restorations of the right deciduous mandibular molars. (B) Gingival bleeding was seen after removal of the rubber dam.



**Fig. 7.** Resin restorations of the right deciduous maxillary molars. (B) Gingival bleeding was seen after removal of the rubber dam.



**Fig. 8.** (A) After extraction of the right deciduous mandibular lateral incisor. (B) After 30 minutes of gauze biting.

and gingival bleeding was similar to the first treatment (Fig. 7). After 30 minutes of compression, the bleeding was reduced, and the patient was discharged. The parents confirmed by phone that there were no bleeding problems.

The patient visited with a chief complaint of a mobility of right deciduous mandibular lateral incisor. The tooth was extracted after applying topical anesthetics. After 30 minutes of biting a gauze, the bleeding was controlled (Fig. 8).

The patient and parents were instructed the importance of periodic dental examinations and oral hygiene practices at home for the prevention of gingivitis and dental caries.

### III. Discussion

Hemostasis is a physiological well-controlled complex process. This process has three main components including vascular system, platelets, and coagulation factors. Congenital bleeding disorders occur when deficiencies of these components. The most well known is Hemophilia. Hemophilia is a coagulation disorder caused by deficiency of factor VIII (hemophilia A) or factor IX (hemophilia B). It is inherited as X-linked recessive condition[6]. von Willebrand disease is the commonest congenital bleeding disorder characterised by abnormali-

ties in platelet adhesion and aggregation due to a deficient of von Willebrand factor. It is an autosomal dominant condition, and affects both males and females[6]. GT is an extremely rare bleeding disorder caused by inherited platelet function disorders. Its clinical manifestation include abnormalities in bleeding time, clot retraction, and a normal platelet count and morphology[7].

GT occurs because of genetic mutations that result in the absence or low levels of platelet surface GP IIb/IIIa, resulting in platelet dysfunction. The genes for both GP are on chromosome 17[8]. GP IIb and IIIa are receptors of fibrinogen, and when they are deficient, the fibrinogen cannot link the platelets together. The deficiency of GP IIb/IIIa interrupts platelet aggregation and causes a bleeding tendency[3]. Since GT patients show normal levels of platelet count, prothrombin time, and activated partial thromboplastin time, it is important to ask for the patient's bleeding tendency and history thoroughly.

Menorrhagia during initial menstrual cycles is most common among GT patients, followed by petechia, ecchymosis, epistaxis, and gingival bleeding. Gastrointestinal bleeding, hematuria, and hemarthrosis are rare[4]. Epistaxis can occur due to the common childhood habit of nose picking, which damages the blood vessels in the nasal mucosa and often leads to excessive bleeding. It rarely occurs in adults, as the risk of bleeding decreases with age[2]. Gingival bleeding is a common symptom, and it is often caused by gingivitis due to poor oral hygiene. Spontaneous loss of deciduous teeth can cause excessive bleeding that requires blood transfusion[4]. It is difficult to estimate the intensity of hemorrhages, because the intensity can differ even between related patients carrying the same mutation[4,9].

The major goal of management is to prevent hemorrhages and achieve hemostasis. Physical activity that can cause bleeding should be avoided, and drugs that interfere with platelet functions, such as aspirin or non-steroidal anti-inflammatory agents, are contraindicated. Frequent hemorrhages can cause iron deficiency anemia. Especially during childhood and adolescence, when rapid development occurs, a large amount of iron is required. To prevent iron deficiency anemia, administration of iron supplements and folic acid is recommended[10]. Local bleeding can be treated by compression, but for prolonged bleeding, platelet transfusion may be required[11]. Repetitive platelet transfusions can cause alloimmunization, wherein antibodies against GP or human leukocyte antigens (HLA) could be formed on the surface of the donor's platelets.

Therefore, transfusion of HLA-compatible platelet concentrates should be considered[12].

GT is a very rare disease that is inherited as an autosomal recessive condition. It affects both males and females. It is more commonly observed in the Middle East, India, and France, where intermarriages are frequent[13]. There were 130 cases reported worldwide by 1969[14], and the disorder has an incidence of about 1 in 1,000,000 people[15]. In South Korea, it was first reported in 1979, and 15 cases were documented in 1992[10]. According to the Division of Rare Diseases, Korea Centers for Disease Control and Prevention, around 200 cases have been reported in 2018.

Pediatric dentists should instruct the importance of dental caries prevention and oral hygiene to minimize gingival bleeding due to gingivitis and dental treatment. Regular dental examination is needed for oral health maintenance. Local anesthesia of 2% lidocaine with 1 : 100,000 epinephrine can be administered without the risk of excessive bleeding[4]. For the bleeding control after tooth extraction or the loss of deciduous teeth, hemostasis can be achieved by applying resorbable oxidized cellulose or plastic splint, or suturing[4,5]. While preparing for hemorrhages that may occur with dental treatment, dentists should keep in mind the bleeding tendency and history of the patient. Medical consultation should be done to provide platelet transfusion when needed.

In this case, the patient did not have a severe bleeding tendency. Compression was enough to achieve hemostasis after dental treatment. After observing the hemostasis in the four visits, the long time required for achieving homeostasis at the first treatment was thought that caused by improper compression. Periodic examinations and oral hygiene maintenance are needed to prevent severe dental caries that may require root canal treatment and tooth extraction in the future. It is believed that thorough preparation will be needed for treatment that is expected to cause excessive bleeding.

#### IV. Summary

Glanzmann's thrombasthenia is a rare inherited disorder characterized by platelet dysfunction. The main symptom is uncontrolled bleeding. Pediatric dentists should minimize factors that cause oral hemorrhages by conducting periodic examinations and giving instructions regarding oral hygiene maintenance. The history of bleeding tendency and severity should be recorded and sufficient preparation for excessive

bleeding that may occur during dental treatment is advisable.

### Authors' Information

Miran Han <https://orcid.org/0000-0003-0312-6023>

Jongsoo Kim <https://orcid.org/0000-0001-8752-332X>

### References

- Bellucci S, Caen J : Molecular basis of Glanzmann's thrombasthenia and current strategics in treatment. *Blood Rev*, 16:193-202, 2002.
- Caen JP, Castaldi PA, Bernard J, *et al.* : Congenital bleeding disorders with long bleeding time and normal platelet count. I. Glanzmann's thrombasthenia : Report of 15 patients. *Am J Med*, 41:4-26, 1966.
- Ranjith A, Nandakumar K : Glanzmann thrombasthenia: A rare hematological disorder with oral manifestations: A case report. *J Contemp Dent Pract*, 9:107-113, 2008.
- George JN, Caen JP, Nurden AT : Glanzmann's thrombasthenia: The spectrum of clinical disease. *Blood*, 75:1383-1395, 1990.
- Diana NM, Rupinder B : Dental considerations in the management of Glanzmann's thrombasthenia. *Int J Child Ped Dent*, 3:51-56, 2010.
- Brown DL : Congenital bleeding disorders. *Curr Probl Pediatr Adolesc Health Care*, 35:38-62, 2005.
- Toygar HU, Guzeldemir E : Excessive gingival bleeding in two patients with Glanzmann thrombasthenia. *J Periodontol*, 78:1154-1158, 2007.
- Nurden AT : Glanzmann thrombasthenia. *Orphanet J Rare Dis*, 1:10, 2006.
- Bellucci S, Devergie A, Boiron M, *et al.* : Complete correction of Glanzmann's thrombasthenia by allogeneic bone marrow transplantation. *Br J Haematol*, 59:635-641, 1985.
- Doh YJ, Kim MH, Kim KY, *et al.* : A case of Glanzmann's thrombasthenia diagnosed with flow cytometry and SDS-PAGE analysis of platelet membrane glycoprotein. *Korean J Hematol*, 27:443-451, 1992.
- Park JB, Shin YS, Kim SH : Anesthetic experience for orthopedic surgery on a patient with Glanzmann's thrombasthenia refractory to platelet transfusion-case report. *Kor J Anesthesiol*, 57:507-510, 2009.
- Murphy MF, Waters AH : Immunological aspects of platelet transfusions. *Br J Haematol*, 60:409-414, 1985.
- Seligsohn U, Rososhansky S : A Glanzmann's thrombasthenia cluster among Iraqi Jews in Israel. *Thromb Haemost*, 52:230-231, 1984.
- Williams WJ, Beutler E, Ersler AJ : Disorders of hemostasis. In, "Hematology", 2nd ed. McGraw-Hill, New York, 1368-1376, 1977.
- Mehta BC, Agarwal MB, Bhanotra PC : Glanzmann's thrombasthenia. *J Postgrad Med*, 26:210-212, 1980.

국문초록

## 글란즈만 혈소판무력증 환자의 치과적 관리

한미란<sup>1</sup> · 김종수<sup>2</sup>

<sup>1</sup> 단국대학교 치과대학 죽전치과병원 소아치과

<sup>2</sup> 단국대학교 치과대학 소아치과학교실

글란즈만 혈소판무력증(Glanzmann Thrombasthenia, GT)은 상염색체 열성 유전으로 나타나는 희귀한 선천성 질환으로 혈소판 기능에 이상이 있어 혈액 응고 장애를 보이며 대표적인 증상은 지혈이 잘 되지 않는 출혈이다. 1918년 소아과의사 글란즈만에 의해 처음 보고 되었으며 글란즈만씨병(Glanzmann's disease)이라고도 불리 운다.

GT는 남성과 여성에서 동등하게 나타나고, 중동, 인도 프랑스 등 근친결혼을 하는 곳에서 많이 발생하며, 대략 1,000,000명당 1명에서 발견된다. 우리나라에서는 2018년 질병관리본부 희귀질환과에 따르면 200여명의 환자가 보고되고 있다.

임상증상은 점상출혈, 반상출혈, 비 출혈, 치은 출혈 등이 관찰되고, 유치의 자발적 탈락에서도 수혈을 고려해야 할 정도의 출혈이 발생할 수 있다. 치료의 일반적인 목표는 출혈 예방과 지혈이다. 여러 가지 지혈을 위한 처치에도 출혈이 지속되면 혈소판 수혈을 해야 한다.

소아치과의사는 구강을 청결히 하여 치은염과 치아 우식증을 예방함으로써 치은 출혈을 최소화하고, 구강 위생과 규칙적인 치과 검진의 중요성을 주지시켜야 하며, 치과치료시 출혈에 대비한 치료계획의 수립 및 세심한 진료가 필요하다.

GT를 동반한 만6세 여아로 치아우식증을 주소로 내원하여 아산화질소-산소를 이용한 흡입진정하에 레진수복을 시행하였으며 술 후 치료부위의 압박지혈이 필요하였다.