

Surgical therapy of keratocystic odontogenic tumors

Ji-Su Oh · Su-Gwan Kim

Department of Oral and Maxillofacial Surgery, School of Dentistry, Chosun University

*Corresponding Author: Su-Gwan Kim, Department of Oral and Maxillofacial Surgery, College of Dentistry, Chosun University, 303, Pilmun-daero, Dong-gu, Gwangju, 501-140, Korea, Tel: 82-62-220-3819 Fax: 82-62-228-7316, E-mail: sgckim@chosun.ac.kr

Received: 24 July 2015; Revised: 23 November 2015; Accepted: 11 December 2015

ABSTRACT

Objectives: Since World Health Organization reclassified the odontogenic keratocyst as a keratocystic odontogenic tumor(KCOT) in 2005, management of KCOT remains controversial. The purpose of the this study is to present a current concept of the treatment of the KCOT.

Methods: Recent articles were focused on the method of the surgical therapy and the recurrence rate of KCOT.

Results: The treatment modality is divided into conservative treatment—such as simple enucleation with or without curettage or marsupialization—and aggressive treatment including peripheral ostectomy, chemical curettage with Carnoy’s solution, and resection.

Conclusions: Keratocystic odontogenic tumors have higher recurrence rates than other odontogenic lesions; thus, the selected type of treatment is very important.

Key Words: decompression, jaw cyst, odontogenic cyst, recurrence

Introduction

Odontogenic keratocyst(OKC) was reclassified by the World Health Organization(WHO) as a keratocystic odontogenic tumor(KCOT) in 2005. This reclassification includes only the aggressive parakeratinized type lesions and excludes cystic lesions with orthokeratinizing epithelium¹⁾. In other words, the parakeratinized variety is identified as KCOT, while the orthokeratinized variety is identified as an orthokeratinized odontogenic cyst(OOC)²⁾. The WHO defined OOC as “a benign uni- or multicystic, intraosseous tumor of odontogenic origin, with a characteristic lining of parakeratinized stratified squamous epithelium and potentially aggressive infiltrative behavior. It may be solitary or multiple. The latter is usually a stigmata of the inherited nevoid basal cell carcinoma syndrome(NBCCS)³⁾.” Reasons

for reclassification as a benign neoplasm are as follows: locally destructive and high recurrence rate, the basal layer of the KCOT budding into connective tissue and mitotic figures in suprabasal layers, and an association with mutation of the tumor suppressor gene⁴⁾. Thus, KCOT was classified as a benign tumor containing an odontogenic epithelium with a mature and fibrous stroma and no odontogenic ectomesenchyme⁵⁾. However, whether the KCOT is a cyst or a cystic neoplasm is yet to be determined.

The ultimate goals of treatment of the KCOT are eliminating the potential for recurrence and minimizing the surgical morbidity⁶⁾. Complete removal of the KCOT is very difficult because of the thin and friable epithelial lining, limited surgical access, cortical perforation, and the desire to preserve adjacent vital structures⁶⁾. Although various surgical modalities have been developed, management of the KCOT remains controversial and there is no consensus because of multiple different treatment modalities and varying recurrence rates^{7,8)}.

The purpose of this study was to review the current management concept, focusing on surgical therapy and

► This study was supported by research fund from Chosun University Dental Hospital, 2014.

Copyright©2015 by Journal of Korean Society of Dental Hygiene
This is an open-access article distributed under the terms of the Creative Commons Attribution Non-Commercial License (<http://creativecommons.org/licenses/by-nc/3.0/>), which permits unrestricted non-commercial use, distribution, and reproduction in medium, provided the original work is properly cited.

the recurrence rate of the KCOT.

Histopathologic characteristics of the KCOT

KCOT have keratinized cells that make keratin fragments in the lumen, resulting in high osmolarity. The KCOT expands because of high osmolarity. The proteolytic activity of the KCOT is related to its growth⁹. Histologic features show the complicated luminal characteristic encroaching on the external capsular surface with little separation of the lining epithelium from the outer surface⁷. The KCOT has increased mitotic activity in the cystic epithelium, a high budding characteristic of the basal layer, and daughter cysts attached to the side walls of the pericyclic cavity¹. On the other hand, the histopathological features related to the high recurrence rate are as follows¹⁰: a higher level of cellular proliferation in the epithelium, budding in the basal layer of the epithelium, parakeratinization of the surface layer, supraepithelial split of the epithelial lining, subepithelial split of the epithelial lining, the presence of remnants or cell rests, as well as daughter cysts.

In particular, fibroblasts of KCOT that are associated with NBCCS proliferate more than those in sporadic KCOT and have osteoclastogenic capacity. This result suggests that KCOT associated with NBCCS is more aggressive¹¹.

The treatment modality of the KCOT

When the treatment method of the KCOT is decided, the morbidity and quality of life of the patients are considered in addition to the recurrence rate¹². A low recurrence rate and a low number of morbidities are important in the selection of the best treatment modality⁸. The treatment of KCOT is still controversial as it relates to conservative or aggressive treatment.

1. The treatment modality of the KCOT

The modality of the treatment of the KCOT is as follows: Decompression (to relieve the pressure within the cystic cavity) <Fig. 1, 2> or marsupialization—which is different from decompression, but is used interchangeably¹²—enucleation (to remove a whole or clean tumor from its envelope) <Fig. 3>, decompression followed by enucleation, curettage (the removal of growths or other material from the wall of a cavity), peripheral ostectomy (the reduction of the

peripheral bone with a powered hand piece after enucleation of the lesion), application of Carnoy's solution or liquid nitrogen, and resection (ostectomy of the jaw)¹³.

Conservative treatment generally includes simple enucleation, with or without curettage, or marsupialization. Aggressive treatment generally includes peripheral ostectomy, chemical curettage with Carnoy's solution, and resection⁶. Aggressive treatments have generally been recommended for NBCCS, large KCOT, and recurrent cases⁴.

2. Radical treatment

Radical treatment results in severe complications, including facial deformity, missing teeth, infection of transplanted bone, and permanent numbness of the inferior alveolar nerve¹². Although resection of the jaw has been proved the most predictable treatment with a 0% recurrence rate¹⁴, overaggressive treatment cannot be justified by reasoning that the risk of recurrence of the KCOT is low¹⁵. It also produces significant morbidity associated with reconstructing continuity defects. Although it is aggressive⁸, KCOT does not have metastatic potential. Resection is necessary for reconstruction but it causes severe problems of jaw function and esthetics, especially among young patients¹⁴. Therefore, although most multilocular and larger aggressive types of KCOT are found in patients younger than 41 years¹⁶, aggressive surgery would not be the best choice for young patients¹⁷. Thus, radical treatment, such as resection, should be considered in patients who experience three or more recurrences, in cases where conservative treatment is impossible, and in cases where carcinomatous or ameloblastomatous transformation is the current concept^{18,19}.

3. Decompression or marsupialization

Decompression or marsupialization has been used as a more conservative form of treatment for a large KCOT in order to minimize the cyst size and to limit the extent of surgery¹². It may be the optimal approach for KCOT treatment.

Decompression or marsupialization relieves the pressure within the cyst and allows the new bone formation to fill the defect¹². Therefore, decompression results in new bone formation and leads to the conversion of the thin friable epithelium into a thickened cyst wall lining^{14,20}. The epithelium of the KCOT changes as the aggressive form transforms into a less aggressive form or into non-keratocysts after decompression¹⁴. In other words, the epithelium of the KCOT transforms into a hyperplastic, stratified, non-keratinizing squamous epithelium after marsupialization^{12,14}.

The effect of marsupialization was evaluated as extremely efficient(64.3%), moderately effective(32.1%), and poorly effective(3.6%)¹². The cysts disappeared completely in five lesions. The results of marsupialization of the KCOT in the mandibular body were more effective than those of the angle to ramus lesions¹². The duration of decompression varies from 6-19 months²⁰. The average duration of irrigation was 8.4 months and the mean shrinkage of the radiolucency was 46-65%²⁰. Epithelial differentiation is a necessary period of at least 9 months²⁰. Similarly, Shudou et al. presented that the volume of KCOT was reduced by a half over 240 days after marsupialization²¹.

The advantage of decompression or marsupialization to preserve anatomic structures, such as teeth and nerve, is advocated because KCOT is commonly found in younger patients^{4,17}. Enucleation, followed by open packing, was also associated with a low recurrence rate for large KCOT in the mandible²². However, conservative treatment, such as decompression or marsupialization, requires commitment and the compliance of patients over a long period lasting several months to years²⁰.

4. Adjunctive therapy with enucleation

A review of the relationship between treatment modalities and recurrence revealed that the most effective treatment is enucleation and application of Carnoy's solution, although marsupialization followed by cystectomy is also effective⁴. In other words, the ideal treatment for KCOT is enucleation with subsequent treatment with an agent that destroys the epithelial remnants and satellite cysts¹. A recent study about the measurements of the complexity of the management of KCOT revealed that enucleation with or without adjunctive therapy(Carnoy's solution, cryotherapy, or peripheral ostectomy) could be the most efficient treatment option²³.

Carnoy's solution is a tissue fixative that acts as a cauterizing mild penetrating agent. It is used as an adjunct for eradicating the remaining vital epithelial cells left within the peripheral cyst wall^{7,8}. The use of Carnoy's solution in eliminating epithelial residues from the wall of the cyst decreases the possibility of recurrence of the KCOT¹⁹. It can be placed into the cavity of the cyst before enucleation or applied to the bony cavity after enucleation, which most surgeons prefer <Fig. 4>⁷. Carnoy's solution can penetrate cancellous bone, as well as devitalize and fix the remaining cell after enucleation¹. Applying Carnoy's solution is the least invasive procedure with the lowest recurrence rate⁸.

On the other hand, Carnoy's solution is limited in that it can fix a daughter cyst located in the bone but not in the soft tissue²⁴. Carnoy's solution formulated with ethanol, glacial acetic acid, and ferric chloride is currently used¹⁸. In the past, chloroform was included in Carnoy's solution; however, the current modified Carnoy's solution does not contain chloroform because of its oncogenic property and reproductive toxicity¹. However, in a recent study, the recurrence rate of KCOT treated by simple enucleation and curettage with the application of modified Carnoy's solution was significantly higher than that treated with Carnoy's solution containing chloroform²⁵. Thus, the case treated with methylene blue staining using a Q-tip instead of Carnoy's solution was reported. Aggressive curettage and peripheral ostectomy with methylene blue staining after initial decompression appeared to be successful within six years²⁵.

5. Selection of treatment of the KCOT

Johnson et al. presented treatment recommendation for the KCOT by systematic review⁷. Simple enucleation is not a good treatment because of the high recurrence rate. Enucleation combined adjunctive therapy, such as Carnoy's solution, is best for accessing small KCOT; however, a large expanding KCOT is best treated with marsupialization and enucleation²⁶. Radical treatment, such as marginal or segmental resection, is not a primary treatment modality. In addition, peripheral variants of KCOT should be applied in different modalities in comparison to intraosseous variants of KCOT because there is the risk that adhesion of the thin lining wall of the KCOT to adjacent soft tissues may prevent the complete removal of the KCOT²⁴.

Recurrence rates of the KCOT

Recurrence rates vary from 0 to 100%. The reasons for recurrence of the KCOT include incomplete removal of the cyst, new growth from a satellite cyst, and the development of a new KCOT in an adjacent tissue²⁷. Highest recurrence rates occur when enucleation alone is performed(25% to 62.5%)¹. Because the lining characteristic of the tumor may be very friable and thin, removal of the cyst in one piece can be difficult. This can result in a high probability of recurrence^{7,8}. Therefore, the major factor that influences the recurrence rate is whether the cyst lining the wall can be removed in one piece¹. Madras and Lapointe reported that

recurrence is relatively low with aggressive treatment, whereas the recurrence rate is higher with more conservative methods, according to a review of articles about the KCOT. They also reported that enucleation combined with the application of Carnoy's solution, with or without peripheral osteotomy, results in a significantly low rate of recurrence (8% and 9%) in all treatment options except resection, which has a recurrence rate of 0⁴). Also, daughter microcysts and epithelial islands are thought to contribute to the high recurrence rate of the KCOT. The frequency of daughter microcysts and epithelial islands suggests a change in the growth characteristics of the KCOT to a more aggressive type¹²). When the KCOT is associated with NBCCS, the recurrence rate is increased by 82%²⁸) because parakeratinization, intramural epithelial remnants, and satellite cysts are more frequent in KCOT associated with NBCCS¹⁹). In a recent retrospective study of factors associated with the potential for recurrence of the KCOT, the recurrence rate was significantly higher in the group with tooth involvement and more marked in cases with third molar involvement²⁴).

Recurrence can occur long after surgery, even after several decades¹⁸), although most recurrences are common within 5-7 years²⁴). As such, periodical follow-up is recommended every year for the first five years and at least every two years after five years²⁹).

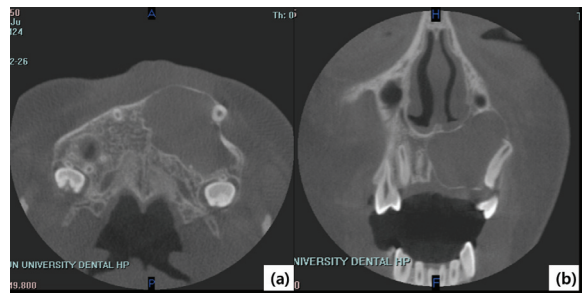


Fig. 1. (a), (b) Computerized tomography showed a large keratocystic odontogenic tumor in the left anterior maxilla.

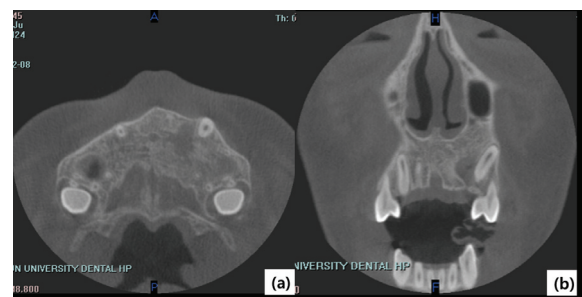


Fig. 2. (a), (b) Almost all lesions disappeared and normal bone formation was observed nine months after decompression.

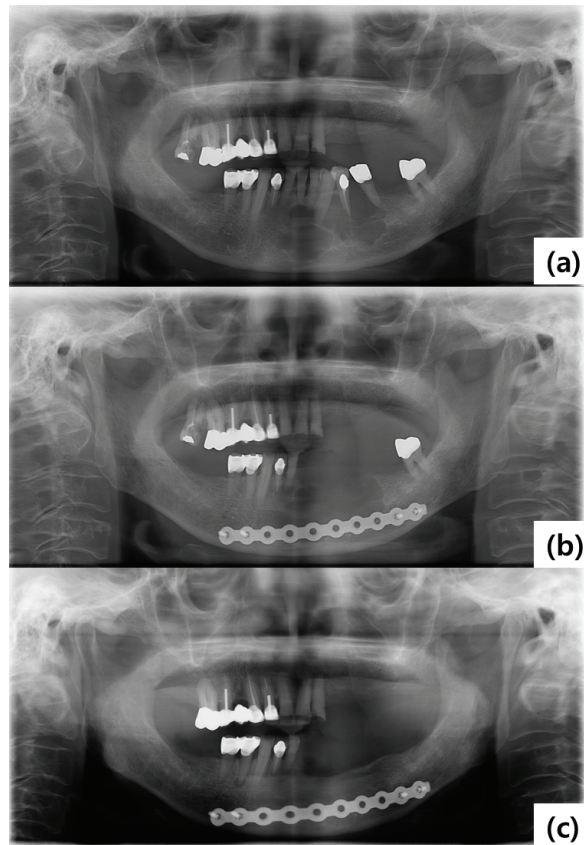


Fig. 3. (a) Pre-operative panoramic view demonstrates multilocular radiolucency of the mandible. (b) Panoramic view after enucleation and extraction followed by reconstruction with titanium plate fixation. (c) Complete bone healing was observed and there was no evidence of recurrence after four years.

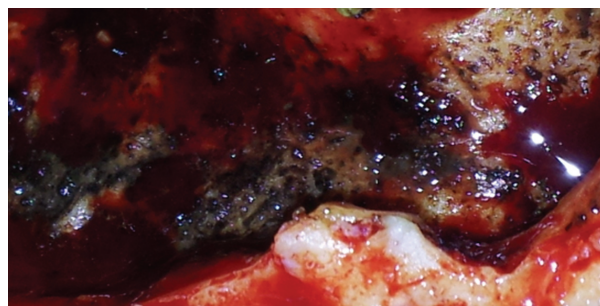


Fig. 4. Carnoy's solution was applied after enucleation.

Conclusion

In conclusion, both patient factors—such as age, general condition, relationship between NBCCS and KCOT—and characteristics—including size, cortical

perforation, involvement of adjacent structures or soft tissue—as well as whether the KCOT is recurrent or primary are considered in the selection of the most appropriate treatment modality³⁰. Also, periodic oral examination of the jaws is needed^{31,32} because almost diseases in the jaw are asymptomatic. Regardless of the treatment modality, periodic follow-up for as long as possible post-surgery is more important.

References

- Kaczmarzyk T, Mojsa I, Stypulkowska J. A systematic review of the recurrence rate for keratocystic odontogenic tumour in relation to treatment modalities. *Int J Oral Maxillofac Surg* 2012; 41(6): 756-67. <http://dx.doi.org/10.1016/j.ijom.2012.02.008>.
- Sansare K, Raghav M, Mupparapu M, Mundada N, Karjodkar FR, Bansal S, et al. Keratocystic odontogenic tumor: systematic review with analysis of 72 additional cases from Mumbai, India. *Oral Surg Oral Med Oral Pathol Oral Radiol* 2013; 115(1): 128-39. <http://dx.doi.org/10.1016/j.o000.2012.10.005>.
- Philipsen HP. Keratocystic odontogenic tumour. In: World Health Organization classification of tumours. Pathology and genetics of head and neck tumours. Edited by Barnes L EJ, Reichart P, Sidransky D: Lyon : International Agency for Research on Cancer; 2005: 306-7.
- Madras J, Lapointe H. Keratocystic odontogenic tumour: reclassification of the odontogenic keratocyst from cyst to tumour. *J Can Dent Assoc* 2008; 74(2): 165-65.
- Telles DC, Castro WH, Gomez RS, Souto GR, Mesquita RA. Morphometric evaluation of keratocystic odontogenic tumor before and after marsupialization. *Braz Oral Res* 2013; 27(6): 496-502. <http://dx.doi.org/10.1590/S1806-83242013000600009>.
- Morgan TA, Burton CC, Qian F. A retrospective review of treatment of the odontogenic keratocyst. *J Oral Maxillofac Surg* 2005; 63(5): 635-9.
- Johnson NR, Batstone MD, Savage NW. Management and recurrence of keratocystic odontogenic tumor: a systematic review. *Oral Surg Oral Med Oral Pathol Oral Radiol* 2013; 116(4): e271-6. <http://dx.doi.org/10.1016/j.o000.2011.12.028>.
- Jafaripozve N, Jafaripozve S, Khorasgani MA. Kerathocyst Odontogenic Tumor: Importance of selection the best treatment modality and a periodical follow-up to prevent from recurrence: a case report and literature review. *Int J Prev Med* 2013; 4(8): 967-70.
- Neville BW, Damm DD, Allen CM, Bouquot JE. *Oral & Maxillofacial Pathology*. 2nd ed. Philadelphia: WB Saunders; 2002: 493-540.
- Nayak MT, Singh A, Singhvi A, Sharma R. Odontogenic keratocyst: What is in the name? *J Nat Sci Biol Med* 2013; 4(2): 282-5. <http://dx.doi.org/10.4103/0976-9668.116968>.
- Hong YY, Yu FY, Qu JF, Chen F, Li TJ. Fibroblasts regulate variable aggressiveness of syndromic keratocystic and non-syndromic odontogenic tumors. *J Dent Res* 2014; 93(9): 904-10. <http://dx.doi.org/10.1177/0022034514542108>.
- Nakamura N, Mitsuyasu T, Mitsuyasu Y, Taketomi T, Higuchi Y, Ohishi M. Marsupialization for odontogenic keratocysts: long-term follow-up analysis of the effects and changes in growth characteristics. *Oral Surg Oral Med Oral Pathol Oral Radiol Endod* 2002; 94(5): 543-53.
- Simiyu BN, Butt F, Dimba EA, Wagaiyu EG, Awange DO, Guthua SW, et al. Keratocystic odontogenic tumours of the jaws and associated pathologies: a 10-year clinicopathologic audit in a referral teaching hospital in Kenya. *J Craniomaxillofac Surg* 2013; 41(3): 230-4. <http://dx.doi.org/10.1016/j.jcms.2012.09.006>.
- Marker P, Brondum N, Clausen PP, Bastian HL. Treatment of large odontogenic keratocysts by decompression and later cystectomy: a long-term follow-up and a histologic study of 23 cases. *Oral Surg Oral Med Oral Pathol Oral Radiol Endod* 1996; 82(2): 122-31.
- Finkelstein MW, Hellstein JW, Lake KS, Vincent SD. Keratocystic odontogenic tumor: a retrospective analysis of genetic, immunohistochemical and therapeutic features. Proposal of a multicenter clinical survey tool. *Oral Surg Oral Med Oral Pathol Oral Radiol* 2013; 116(1): 75-83. <http://dx.doi.org/10.1016/j.o000.2013.03.018>.
- Boffano P, Ruga E, Gallesio C. Keratocystic odontogenic tumor (odontogenic keratocyst): preliminary retrospective review of epidemiologic, clinical, and radiologic features of 261 lesions from University of Turin. *J Oral Maxillofac Surg* 2010; 68(12): 2994-9. <http://dx.doi.org/10.4103/0976-237X.152963>.
- de Molon RS, Verzola MH, Pires LC, Mascarenhas VI, da Silva RB, Cirelli JA, et al. Five years follow-up of a keratocyst odontogenic tumor treated by marsupialization and enucleation: A case report and literature review. *Contemp Clin Dent* 2015; 6(Suppl 1): S106-10. <http://dx.doi.org/10.4103/0976-237X.152963>.
- Gosau M, Draenert FG, Müller S, Frerich B, Bürgers R,

- Reichert TE, et al. Two modifications in the treatment of keratocystic odontogenic tumors(KCOT) and the use of Carnoy's solution(CS)--a retrospective study lasting between 2 and 10 years. *Clin Oral Investig* 2010; 14(1): 27-34. <http://dx.doi.org/10.1007/s00784-009-0264-6>.
19. Mendes RA, Carvalho JF, van der Waal I. Characterization and management of the keratocystic odontogenic tumor in relation to its histopathological and biological features. *Oral Oncol* 2010; 46(4): 219-25. <http://dx.doi.org/10.1016/j.oraloncology.2010.01.012>.
 20. August M, Faquin WC, Troulis MJ, Kaban LB. Dedifferentiation of odontogenic keratocyst epithelium after cyst decompression. *J Oral Maxillofac Surg* 2003; 61(6): 678-83; discussion 83-4.
 21. Shudou H, Sasaki M, Yamashiro T, Tsunomachi S, Takenoshita Y, Kubota Y, et al. Marsupialisation for keratocystic odontogenic tumours in the mandible: longitudinal image analysis of tumour size using 3D visualised CT scans. *Int J Oral Maxillofac Surg* 2012; 41(3): 290-6. <http://dx.doi.org/10.1016/j.ijom.2011.10.015>.
 22. Chuan L, Hongzhi Z, Rui H, Yuxiang D, Ruifeng Q, Kaijin H. Clinical observation of a conservative treatment for large keratocystic odontogenic tumors in the mandible: enucleation followed by open packing. *Hua Xi Kou Qiang Yi Xue Za Zhi* 2014; 32(6): 566-9.
 23. Kinard BE, Chuang SK, August M, Dodson TB. For treatment of odontogenic keratocysts, is enucleation, when compared to decompression, a less complex management protocol? *J Oral Maxillofac Surg* 2015; 73(4): 641-8. <http://dx.doi.org/10.1016/j.joms.2014.11.001>.
 24. Sanchez-Burgos R, Gonzalez-Martin-Moro J, Perez-Fernandez E, Burgueno-Garcia M. Clinical, radiological and therapeutic features of keratocystic odontogenic tumours: a study over a decade. *J Clin Exp Dent* 2014; 6(3): e259-64. <http://dx.doi.org/10.4317/jced.51408>.
 25. Pogrel MA. The keratocystic odontogenic tumour (KCOT)-an odyssey. *Int J Oral Maxillofac Surg* 2015 May 21. <http://dx.doi.org/10.1016/j.ijom.2015.03.008>. [Epub ahead of print].
 26. Padaki P, Laverick S, Bounds G. Conservative management of a large keratocystic odontogenic tumour. *J Surg Case Rep* 2014; 2014(9) <http://dx.doi.org/10.1093/jscr/rju091>.
 27. Brannon RB. The odontogenic keratocyst. A clinicopathologic study of 312 cases. Part I. Clinical features. *Oral Surg Oral Med Oral Pathol* 1976; 42(1): 54-72.
 28. Titinchi F, Nortje CJ. Keratocystic odontogenic tumor: a recurrence analysis of clinical and radiographic parameters. *Oral Surg Oral Med Oral Pathol Oral Radiol* 2012; 114(1): 136-42. <http://dx.doi.org/10.1016/j.oooo.2012.01.032>.
 29. Pitak-Amnop P, Chainé A, Oprean N, Dhanuthai K, Bertrand JC, Bertolus C. Management of odontogenic keratocysts of the jaws: a ten-year experience with 120 consecutive lesions. *J Craniomaxillofac Surg* 2010; 38(5): 358-64. <http://dx.doi.org/10.1016/j.jcms.2009.10.006>.
 30. Roopak B, Singh M, Shah A, Patel G. Keratocystic odontogenic tumor: treatment modalities: study of 3 cases. *Niger J Clin Pract* 2014; 17(3): 378-83. <http://dx.doi.org/10.4103/1119-3077.130251>.
 31. Lee DG, Yoo WK. Relations between oral health status and subjective oral health recognition in Korean adolescents. *J Korean Soc of Dent Hyg* 2015; 15(4): 593-602. <http://www.riss.kr/link?id=A100825628>.
 32. Ju OJ, Jang YJ, Jung JA. Oral health awareness and behavior affecting oral health indexes. *J Korean Soc of Dent Hyg* 2013; 13(1): 69-81. <http://www.riss.kr/link?id=A99769553>.