

Journal of Korean Society of Dental Hygiene


Original Article

Changes of airway after orthognathic surgery for patients with skeletal class III malocclusion

Seung-Hun Lee · Jeong-Jae Kim

Department of Dental hygiene, Cheongam College

Corresponding Author: Seung-Hun Lee, Department of Dental Hygiene, Cheongam College 1641 Nokseak-ro, Suncheon, Jeonnam 57997, Korea, Tel: +82-61-740-7382, Fax: +82-61-740-7418, E-mail: smili@hanmail.net



Received: May 28, 2018

Revised: July 7, 2018

Accepted: July 13, 2018

Abstract

Objectives: This retrospective study evaluated the changes in the airway width after the orthognathic surgery associated with the skeletal Class III malocclusion. **Methods:** The lateral cephalograms of 30 adult patients were taken before and immediately after the operation, and after the orthodontic treatment. The angles and distances of them were measured and compared. **Results:** Before the surgery, the mean value of mandibular (S-B) setback was 9.66 mm, and moved by 1.56 mm anteriorly after the orthodontic treatment. The ANB increased by 5.42 degrees, since then it decreased by 0.68 degree. The hyoid bone (S-APH) moved by 5.05 mm posteriorly, but then moved by 2.26 mm anteriorly. The soft tissue width of laryngeal pharynx (apw2-ppw2) was narrowed by 1.04 mm, and decreased by additional 0.83 mm after the orthodontic treatment. **Conclusions:** As the mandible was moved back, the location of hyoid bone and laryngeal pharynx were moved backward.

Key Words: Airway, Malocclusion, Orthodontic treatment, Orthognathic surgery

Introduction

An airway is an organ which connects a nasal cavity, a maxillary sinus, a pharynx, and a larynx. It is mainly composed of a muscles and a mucous membranes, and has the important functions such as breathing, swallowing, and pronouncing. In the dentistry, an airway is also interested in an adenoids face, an obstructive sleep apnea, and an oral maxillofacial surgery. Besides, it is associated with an oral and an adjacent tissues, and is closely related to the maxillofacial growth and a malocclusion[1-3].

A malocclusion can be divided into three types, the Class III malocclusion is the anterior position of mandible than the normal occlusion. It causes a dysfunction and an aesthetic defect, and these patients can be improved by an orthodontic treatment and surgery. However, the mandibular and maxilla setback osteotomy can cause not only the skeletal changes such as an occlusion, a mastication, but also the soft

tissue changes[4-9].

Therefore, when planning the surgery, a surgeon will consider how the movement of mandible and maxilla affect the airway. Yoon and Han[4] measured the changes of airway space according to the orthognathic surgery method, Choi et al.[5] measured them after bilateral sagittal split ramus osteotomy (B-SSRO), Kim et al.[6] measured them after B-SSRO using computed tomography(CT) images. Chang et al.[7] measured the changes in the airway space and cranial, cervical angulation after mandibular setback operation, Kawakami et al.[8] measured the changes in the hyoid bone, tongue, and airway following mandibular setback, Lee et al.[9] measured them after B-SSRO using three-dimensional (3D) CT.

In the previous study of the airway changes after orthognathic surgery[4-9], there were the studies that showed them the temporary decrease and then return again[7-9], while there were other studies that the reduced airway did not return[4-6].

The purpose of this study was to measure the change of airway after orthognathic surgery in patients with the skeletal class III malocclusion. Also it was to evaluate them over a long period of time.

Methods

1. Study subjects

The study subjects were the skeletal class III malocclusion patients who underwent the orthognathic surgery with A point-Nasion-B point (ANB) less than 1 angle among the patients who visited K university hospital dentistry. The patients were consulted and agreed on the surgery, the judgment sampled 90 radiographs were used in the final analysis. Those were taken from October 2015 to January 2016.

The minimum number of study samples were calculated as 20 using G Power 3.1[10-12] program by repeated measure analysis of variance (RM ANOVA) within group, 0.05 significance level, 95% power of test, and 0.73 effect size. Assuming the elimination by 20%, 30 subjects were suitable for the minimum sample size for the analysis. The size effect was referred to anteroposterior dimension of pharyngeal airway-3 (Pap-3) as results of Lee et al.[9].

The researcher received the exemption letter from Cheongam college Institutional Review Board (CA-IRB, CA17-171023-HR-001-01).

2. Study method

The subjects were taken a cephalometric radiograph at 85 kVp, 12 mA, and 10 seconds (Orthopantomograph OC-100D, Instrumentarium Imagin, Tuusula, Finland). The photos were stored as Digital Imaging and Communications in Medicine (DICOM) using Picture Archiving and Communication System (PACS). The files were converted to image file format (Joint Photographic coding Experts Group; JPEG). The photo files were reconstructed and measured at computer-aided design program (Autodesk, Inc., San Rafael, CA).

The cephalometric points were Sella turcica (S; the central point of pituitary gland of sphenoid bone), Nasion (N; the nodal point between the sutura of nasal bone and frontal bone and the sutura of nasal bone), Orbitale (Or; the most inferior point of orbit), Posterior nasal spine (PNS; the most posterior point of hard

palate), A point (A; the most posterior point of curvature liping between the fundus of maxilla and the alveolar bone), B point (B; the most posterior point of median sutura of mandibular outline), Basion (Ba; the most anterior inferior point of greater occipital foramen), Porion (Po; the most superior point of external acoustic meatus), the most anterior point of hyoid bone (APH), the most anterior point of anterior arch of 1st atlas (AA), the most inferior point of 3rd atlas (CV3ia), the nodal point between the posterior pharyngeal wall and the connecting line from PNS to Ba (ad), the nodal point between the anterior pharyngeal wall and the connecting line from the most anterior point of hyoid bone to the most anterior point of 2nd atlas (apw2), and the nodal point between the posterior pharyngeal wall and the connecting line from the most anterior point of hyoid bone to the most anterior posterior point of 2nd atlas (ppw2) <Fig. 1>.

The cephalometric plane was Frankfort horizontal (FH) plane, and the cephalometric angle was ANB. The horizontal measurement distances of skull were the distance between the vertical line from FH plane to S and the B (S-B), the distance between the vertical line from FH plane to S and the A (S-A), and the distance between the vertical line from FH plane to S and the APH (S-APH). The hard tissue airway distances were the distance between AA and PNS (AA-PNS) and the distance between CV3ia and APH (CV3ia-APH). The soft tissue airway distances were the distance between PNS and ad (PNS-ad), the distance between apw2 and ppw2 (apw2-ppw2) <Fig. 1>.

3. Data analysis

The craniometric point, plane, angle, and distance of the subjects were calculated the mean and the standard deviation. In addition, those were analyzed by RM ANOVA within group depending on the measurement period (before the surgery, after the surgery, and after the orthodontic). Also it was analyzed by RM ANOVA between group according to the gender and the surgical method.

The data were analyzed using Statistical Package for the Social Sciences (SPSS ver. 18.0, Chicago, Illinois, USA).

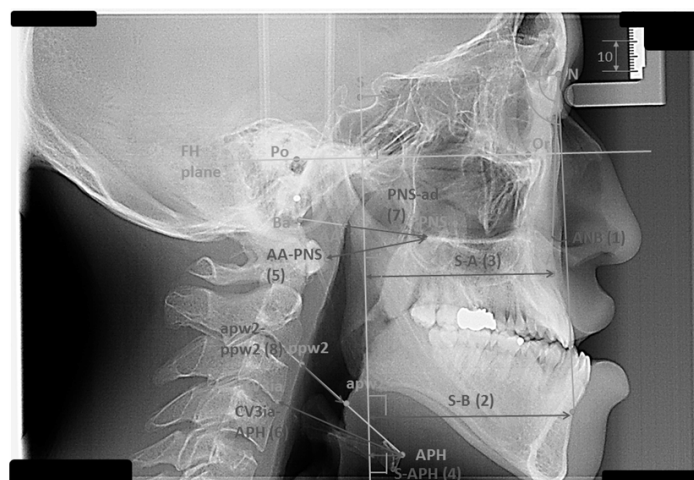


Fig. 1. The craniometric point, plane, angle, and distance.

Results

1. The general characteristics of the study subjects

The study subjects were 30 patients with the orthognathic surgery. They were 15 males, and 15 females. 15 patients underwent the mandibular surgery, and 15 patients underwent the bimaxillary surgery. The average age of the patient was 23.1 years, and underwent the surgery after an average of 4.9 months. After 11.4 months on the average, the orthodontic treatment was completed<Table 1>.

2. The changes in the angle and distance measurements of skull after the surgery

It was shown in <Table 2> that was the changes in the angle and distance measurements of skull.

ANB was -3.52 angle preoperatively, 1.90 angle postoperatively, and 1.22 angle after the orthodontic treatment. ANB increased 5.42 angle postoperatively compared with the preoperative, but decreased 0.68 angle after the orthodontic treatment ($p<0.01$). There was no significant difference according to the gender and the surgical method.

S-B was 68.96 mm, 59.30 mm and 60.86 mm, respectively. S-B decreased 9.65 mm after the surgery, but increased 1.56 mm after the orthodontics. There was no significant difference according to the gender and the surgical method.

There was no statistically significant change in S-A, but there was the significant difference according to the gender ($p<0.05$). The pre-operative S-A was greater in the males than the females, the male was decreased and then increased while the female was increased continually ($p<0.05$).

S-APH was 17.69 mm preoperatively, 12.64 mm postoperatively, and 14.90 mm after the orthodontic treatment. S-APH was statistically significantly decreased 5.05 mm after the surgery, but increased 2.26 mm after the orthodontic treatment ($p<0.01$). There was no significant difference according to the gender and the surgical method<Table 2>.

3. The changes in the oropharynx after the surgery

AA-PNS was 28.45 mm preoperatively, 29.10 mm postoperatively, and 28.81 mm after the orthodontic treatment. AA-PNS was statistically increased 0.65 mm after the surgery ($p<0.05$). There was no significant difference according to the gender and the operative method.

Table 1. The characteristics of the study subjects

Characteristics	Division	N(Mean)	%(SD)
Gender	Male	15.0	50.0
	Female	15.0	50.0
Surgery	Mandibular	15.0	50.0
	Bimaxillary	15.0	50.0
Age		23.1	3.7
Period(month)	Pre-postoperative	4.9	5.0
	After orthodontic	11.4	5.2

www.kci.go.kr

There was no statistically significant changes in PNS-ad<Table 3>.

4. The changes in the laryngopharynx after the surgery

There was no statistically significant difference in CV3ia-APH, but there was the significant difference according to the gender. The pre-operative CV3ia-APH was greater in the males than the females, the male was decreased continually while the female was increased and then decreased ($p<0.01$). In addition, the female

Table 2. The changes in the angle and distance measurements of skull (Unit: mm)

	N	Division	Pre-operation	Post-operation	After orthodontics	p^*	
						Within	Between
ANB(angle)	15	Male	-3.52±1.46	1.87±1.24 [†]	0.95±1.66 [†]	<0.001	0.532
	15	Female	-3.51±1.37	1.93±0.93 [†]	1.49±1.22 [†]	<0.001	
	15	Mand.	-3.71±1.53	2.02±1.23 [†]	1.45±1.30 [†]	<0.001	0.593
	15	bimax.	-3.33±1.27	1.78±0.08 [†]	0.99±1.61 [†]	<0.001	
	30		-3.52±1.39	1.90±1.08 [†]	1.22±1.46 [†]	<0.001	
S-B	15	Male	71.63±4.98	60.49±4.24 [†]	61.86±4.21 [†]	<0.001	0.073
	15	Female	66.28±6.64	58.11±5.31 [†]	59.86±4.94 [†]	<0.001	
	15	Mand.	68.31±7.01	59.82±5.73 [†]	61.41±5.40 [†]	<0.001	0.879
	15	bimax.	69.60±5.86	58.79±3.97 [†]	60.31±3.81 [†]	<0.001	
	30		68.96±6.38	59.30±4.87 [†]	60.86±4.62 [†]	<0.001	
S-A	15	Male	64.90±2.47	63.72±2.64	63.90±2.35	0.202	0.040
	15	Female	61.07±4.52	61.71±4.07	62.12±4.38 [†]	0.110	
	15	Mand.	62.42±4.76	63.11±4.08	63.23±3.94	0.163	0.979
	15	bimax.	63.54±3.32	62.32±2.66	62.79±3.41	0.240	
	30		62.98±4.07	62.72±3.41	63.01±3.57	0.703	
S-APH	15	Male	18.96±5.43	13.79±7.76 [†]	16.16±7.08	0.001	0.255
	15	Female	16.42±5.75	11.48±6.30 [†]	13.64±5.29 [†]	0.004	
	15	Mand.	16.74±5.91	12.80±6.98 [†]	15.05±6.66	<0.001	0.844
	15	bimax.	18.64±5.39	12.48±7.35 [†]	14.75±6.10 [†]	<0.001	
	30		17.69±5.64	12.64±7.04 [†]	14.90±6.28 [†]	<0.001	

* by RM ANOVA

[†] post-hoc analysis at $\alpha=0.05$: Bonferroni correction with the value of pre-operative

Table 3. The changes in the oropharynx (Unit: mm)

	N	Division	Pre-operation	Post-operation	After orthodontics	p^*	
						Within	Between
AA-PNS	15	Male	28.06±4.03	28.85±3.74	28.60±3.86	0.075	0.644
	15	Female	28.85±2.98	29.36±2.78	29.01±2.83	0.190	
	15	Mand.	29.60±3.08	30.04±2.87	29.74±3.11	0.157	0.095
	15	bimax.	27.31±3.62	28.17±3.43	27.87±3.38	0.083	
	30		28.45±3.50	29.10±3.25 [†]	28.81±3.33	0.015	
PNS-ad	15	Male	21.95±3.47	21.09±3.54	21.34±3.48	0.216	0.487
	15	Female	22.38±3.24	21.94±3.23	22.52±2.99	0.250	
	15	Mand.	22.72±3.02	21.97±3.22	22.67±3.02	0.192	0.607
	15	bimax.	21.61±3.59	21.06±3.54	21.19±3.39	0.406	
	30		22.17±3.31	21.51±3.36	21.93±3.24	0.110	

* by RM ANOVA

[†] post-hoc analysis at $\alpha=0.05$: Bonferroni correction with the value of pre-operative

was more difference than the male between before the operation and after the orthodontic treatment.

Apw2-ppw2 was 13.52 mm preoperatively, 12.48 mm postoperatively, and 11.65 mm after the orthodontic treatment. Apw2-ppw2 was statistically significantly decreased 1.87 mm after the orthodontic treatment compared with the prior operation ($p<0.05$). There was also a significant difference according to the gender ($p<0.05$). The pre-operative Apw2-ppw2 was greater in the males than the females, the male was more difference than the female between before the operation and after the orthodontic treatment<Table 4>.

5. The correlation between the variables

The correlation between the variables was shown in <Table 5>. The ANB decreased ($p<0.01$) as the mandibular anterior position (S-B), the hyoid bone (S-APH) was located anteriorly ($p<0.01$), and the width of hard oropharynx(AA-PNS) was increased ($p<0.05$). The width of soft laryngopharynx (apw2-ppw2) also increased ($p<0.01$).

S-B had a somewhat higher negative correlation with ANB ($r=0.634$) and a somewhat higher positive correlation with S-APH ($r=0.662$), but a lower positive correlation with AA-PNS ($r=0.225$) and apw2-ppw2 ($r=0.369$).

Table 4. The change in the laryngopharynx (Unit: mm)

	N	Division	Pre-operation	Post-operation	After orthodontics	p^*	
						Within	Between
CV3ia-APH	15	Male	38.51±3.70	38.09±3.70	37.79±4.26	0.538	<0.001
	15	Female	32.81±2.73	33.04±3.61	31.72±2.82 [†]	0.109	
	15	Mand.	35.19±3.74	35.42±3.70	34.36±4.36	0.256	
	15	bimax.	36.13±4.90	35.70±5.17	35.16±5.14	0.346	
	30		35.66±4.31	35.56±4.42	34.76±4.70 [†]	0.125	
Apw2-ppw2	15	Male	14.96±3.02	13.37±3.00	12.99±4.50 [†]	0.051	0.022
	15	Female	12.07±2.63	11.59±3.51	10.31±3.03 [†]	0.144	
	15	Mand.	13.23±3.27	11.07±3.09 [†]	11.75±4.48	0.003	
	15	bimax.	13.80±3.11	13.89±3.04	11.54±3.63 [†]	0.052	
	30		13.52±3.15	12.48±3.34	11.65±4.01 [†]	0.015	

* by RM ANOVA

[†] post-hoc analysis at $\alpha=0.05$: Bonferroni correction with the value of pre-operative

Table 5. The correlation coefficients between the variables

	S-B	ANB	S-APH	AA-PNS	apw2-ppw2
S-B	1				
ANB	-0.634**	1			
S-APH	0.662**	-0.301**	1		
AA-PNS	0.225*	0.129	0.013	1	
Apw2-ppw2	0.369**	-0.223*	0.176	0.236*	1

* $p<0.05$, ** $p<0.01$ by pearson correlation analysis

Discussion

For the cephalometry, Broadbent[13] used the lateral cephalometric radiographs, King[14] used the roentgenograph which studied the growth of pharynx. Recently, the lateral cephalograms have been used for

www.kci.go.kr

the measurements[4-5,7-8]. This study also used that to measure.

Because the airway may change with growing, the subjects were the adults.

ANB was -3.52 angle before the surgery, then it was improved to 1.90 angle after the surgery, but was slightly returned to 1.22 angle after the orthodontic treatment. The change in ANB is thought to be due to change in S-B. Because there was the negative correlation with S-B ($p<0.01, r=-0.634$). According to the previous study[15], ANB did not the correlation with the position of maxilla, but the positive correlation with the mandible.

The mandibular position (S-B) transferred posteriorly after the surgery, but slightly moved anteriorly after the orthodontic treatment. Lee and Han[4] reported that the mandibular moved to the posterior position, and then regressed to the anterior position. In the study of Chang et al.[7], the mandible moved to posterosuperior position, it regressed slightly. But Choi et al.[5] reported that the mandible moved posteriorly and further to the posterior position. This study result was similar to some previous studies[4,7].

S-APH decreased 5.05 mm after the surgery but increased 2.26 mm after the orthodontic treatment. The change in S-APH is thought to be due to change in S-B. Because there was the negative correlation with S-B ($p<0.01, r=-0.662$). The hyoid bone was regressed, but it did not return to its preoperative position. In the study of Lee and Han[4], the hyoid bone was recovered after one year, but the hyoid bone was located posteriorly before the surgery. Choi et al.[5] reported that the hyoid bone moved to the posterior but was restored to preoperative position. The study result was similar to that of Lee and Han[4]. However, some studies have reported that the hyoid bone moved inferiorly after the surgery[7,9]. Therefore, there are need the various follow-up studies on the position of hyoid bone.

There was a statistically significant difference in AA-PNS, but the change between the before and after the surgery was minimal (0.65 mm). There was no statistically significant difference in PNS-ad. It was probably due to the fact that the position of maxilla (S-A) did not change significantly. Lee and Han[4] reported that the oropharyngeal width was reduced 2.3 mm after the surgery and it was lengthened 0.9 mm after 6 months, but it was reduced 1.1 mm compared to before the surgery. Choi et al.[5] showed it was decreased after the surgery and was further decreased at the follow-up. In the study of Zhang et al.[7], the oro-pharyngeal airway was decreased after the surgery, but most of that was returned after one year. Lee[9] was also reported to recover after 6 months. This study result was similar to some previous studies[7,9].

There was no statistically significant difference in CV3ia-APH, but apw2-ppw2 was significantly decreased ($p<0.05$). The reason was that the mandible(S-B) and hyoid bone(S-APH) moved backward. In the previous study[4,7,9], the laryngopharyngeal width decreased and then regressed. However, Choi et al.[5] reported that it was decreased after the surgery, and further decreased in the follow-up. This study result was similar to that of Choi et al.[5].

In this study, the changes of airway were measured after surgery. Beside, it was the follow-up investigation after the orthodontic treatment. In addition, those were analyzed the difference in changes according to the surgical method and the gender. It was considered to be a series of steps to compensate for the mandible moved backward that was the narrowing of airway width after the orthognathic surgery. However, this study has the limitations which was difficult to generalize because of few study subjects in their 20s, had not been

able to use more accurate measurement tools such as 3D CT, and could not directly conduct a questionnaire or interview with the patient to check a various problems after the surgery.

a follow-up study is needed to study the changes of airway according to various subjects and surgical methods such as genioplasty, forward movement surgery of maxillary or mandible, and the position of the tongue.

When a surgeon plans an orthognathic surgery for a patients with risk factors which an airway is narrow or the posterior movement of mandible is large, these changes should be referred to. In addition, as a specialist who cooperates with a dental care and educates a oral health, a dental hygienists need to explain and educate a patients with reference to these changes.

Conclusions

The purpose of this study was to measure the changes of airway after the orthognathic surgery in the patients with skeletal Class III malocclusion. In addition, it was also followed up after the orthodontic treatment.

It was used for final analysis that was the total of 90 lateral cephalometric radiographs of 30 judgement sampled subjects. The measurement angle and distances were calculated as the mean and the standard deviation, and the changes of variables according to the measurement period were analyzed by repeated measures ANOVA. Also the variables were analyzed by correlation.

1. The subjects were 23.1 years old on average, underwent the surgery after an average of 4.9 months, and completed the orthodontic treatment after an average of 11.4 months.
2. ANB was increased after the surgery, but was decreased after the orthodontic treatment.
3. The mandible (S-B) moved posteriorly after the surgery, but partially moved anteriorly after the orthodontic treatment.
4. The hyoid bone (S-APH) also went back postoperatively, since then some went ahead.
5. The location of the oropharynx did not change widely after the surgery.
6. The soft tissue width (apw2-ppw2) of laryngeal pharynx was narrowed after the surgery, and further decreased after the orthodontic treatment.

As the mandible was transferred after the orthognathic surgery, the position of the hyoid bone and the angle of ANB were changed. Those changes may have affected the width of airway.

References

- [1] Hwang YI, Lee KH, Lee KJ, Kim SC, Cho HJ, Cheon SH, et al. Effect of airway and tongue in facial morphology of prepubertal Class I, II children. *Korean J Orthod* 2008;38(2):74-82. <https://doi.org/10.4041/kjod.2008.38.2.74>
- [2] Park SH, Yu HS. A comparison study of the effects of hypertrophied adenoid tissue on jaws morphology. *Korean J Orthod* 2002;32(1):19-31.
- [3] Lee MJ, Kim JG, Yang YM, Baik BJ. Effects of mouth breathing on facial skeletal morphology. *J Korean Acad Pediatr Dent* 2012;39(4):339-47. <https://doi.org/10.5933/>

www.kci.go.kr

- JKAPD.2012.39.4.339
- [4] Lee YS, Han SJ. Comparison of the change in the pharyngeal airway apace, tongue and hyoid bone positions according to the orthognathic surgical methods of mandibular prognathism. *J Korean Assoc Maxillofac Plast Reconstr Surg* 2013;35(4):211-20. <https://doi.org/10.14402/jkamprs.2013.35.4.211>
 - [5] Choi YH, Kim BK, Choi BJ, Kim YG, Lee BS, Kwon YD, et al. An investigation of hyoid bone position and airway space in class 3 malocclusion after orthognathic surgery. *J Korean Assoc Maxillofac Plast Reconstr Surg* 2011;33(5):401-6.
 - [6] Kim BS, Jung SG, Han MS, Jeoung YW, Kook MS, Park HJ, et al. Changes of pharyngeal airway space after mandibular setback surgery in computed tomography images. *J Korean Assoc Maxillofac Plast Reconstr Surg* 2011;33(1):36-43.
 - [7] Chang HH, Kim JS, Yi CK. A study on the change of airway space and cranial, cervical angulation after mandibular setback operation. *J Korean Assoc Oral Maxillofac Surg* 2000;26(2):115-31. [https://doi.org/10.1016/s0901-5027\(97\)81025-9](https://doi.org/10.1016/s0901-5027(97)81025-9)
 - [8] Kawakami M, Yamamoto K, Noshi T, Miyawaki S, Kirita T. Effect of surgical reduction of the tongue on dentofacial structure following mandibular setback. *J Oral Maxillofac Surg* 2004;62(10):1188-92. <https://doi.org/10.1016/j.joms.2004.06.032>
 - [9] Lee JH, Paeng JY, Myoung H, Hwang SJ, Seo BM, Choi JY, et al. The three dimensional analysis of volumetric airway change in orthognathic surgery of mandibular prognathism. *J Korean Assoc Maxillofac Plast Reconstr Surg* 2005;27(6):552-8.
 - [10] Faul F, Erdfelder E, Lang AG, Buchner A. G*Power 3: A flexible statistical power analysis program for the social, behavioral, and biomedical science. *Behavior Research Methods* 2007;39(2):175-91. <https://doi.org/10.3758/bf03193146>
 - [11] Cohen J. *Statistical power analysis for behavioral sciences*. 2nd ed. Hillsdale: Elsevier; 1988:553-8.
 - [12] Kang H. Sample size determination for repeated measures design using G Power software. *Anesth Pain Med* 2015;10(1):6-15. <https://doi.org/10.17085/apm.2015.10.1.6>
 - [13] Broadbent BH. A new x-ray technique and its application to orthodontia. *Angle Orthodontist* 1931;1(2):45-66.
 - [14] King EW. A roentgenographic study of pharyngeal growth. *Angle Orthodontist* 1952;22(1):23-37.
 - [15] Lee SH. Study on airway size in class iii malocclusion by the gender. *Korean J Phys Anthropol* 2017;30(4):145-51. <https://doi.org/10.11637/kjpa.2017.30.4.145>